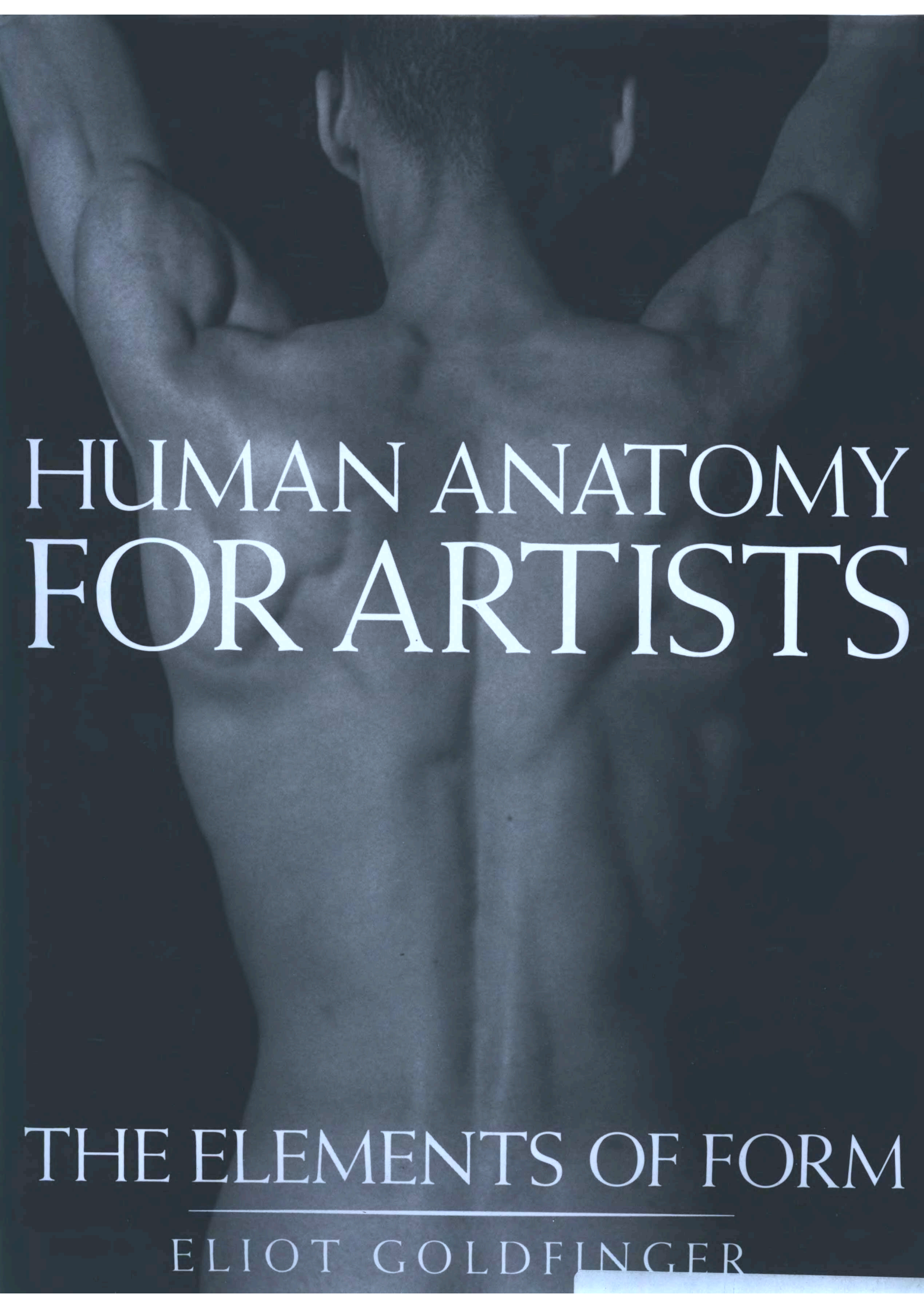

HUMAN ANATOMY FOR ARTISTS

THE ELEMENTS OF FORM

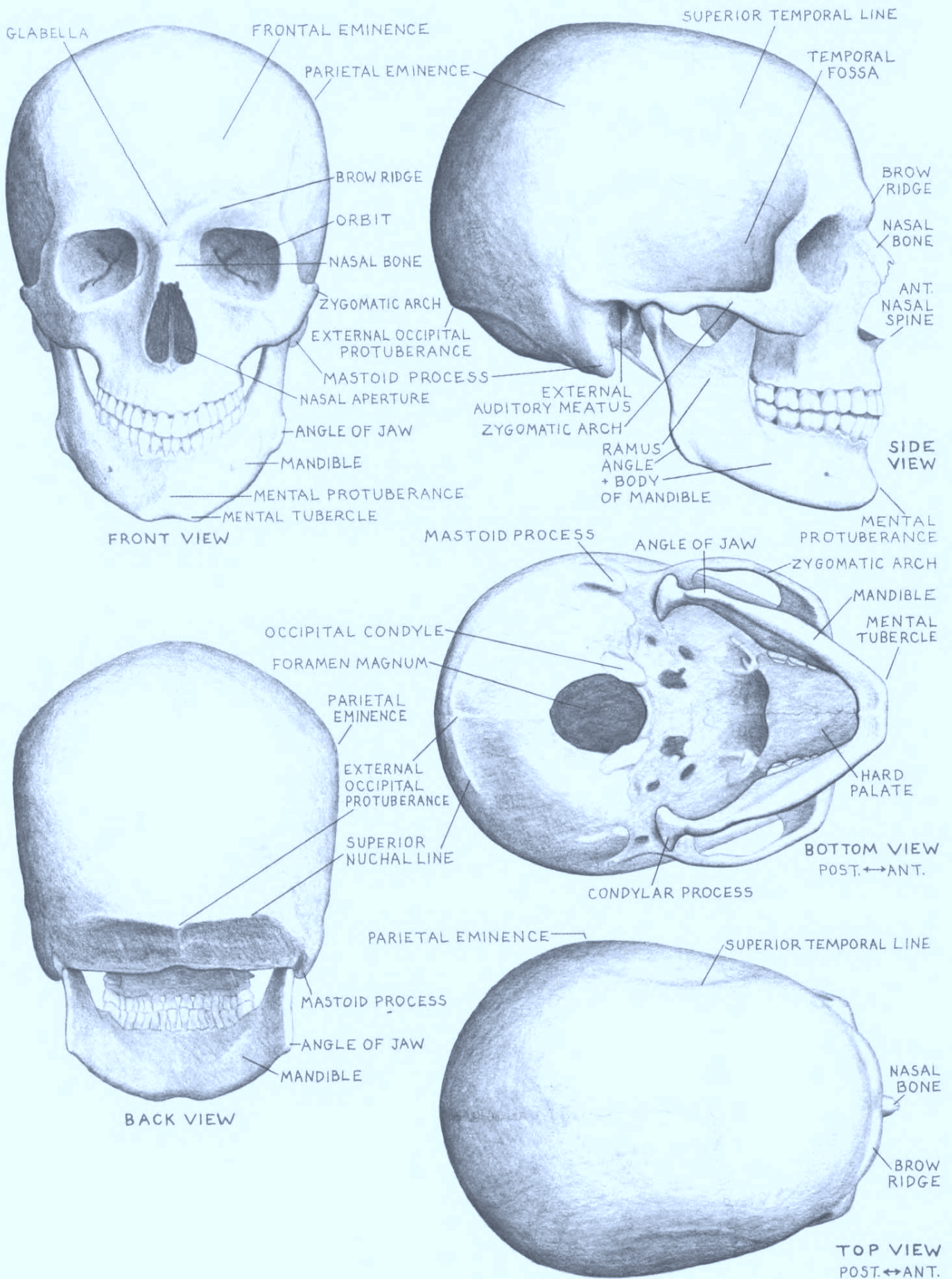
ELIOT GOLDFINGER

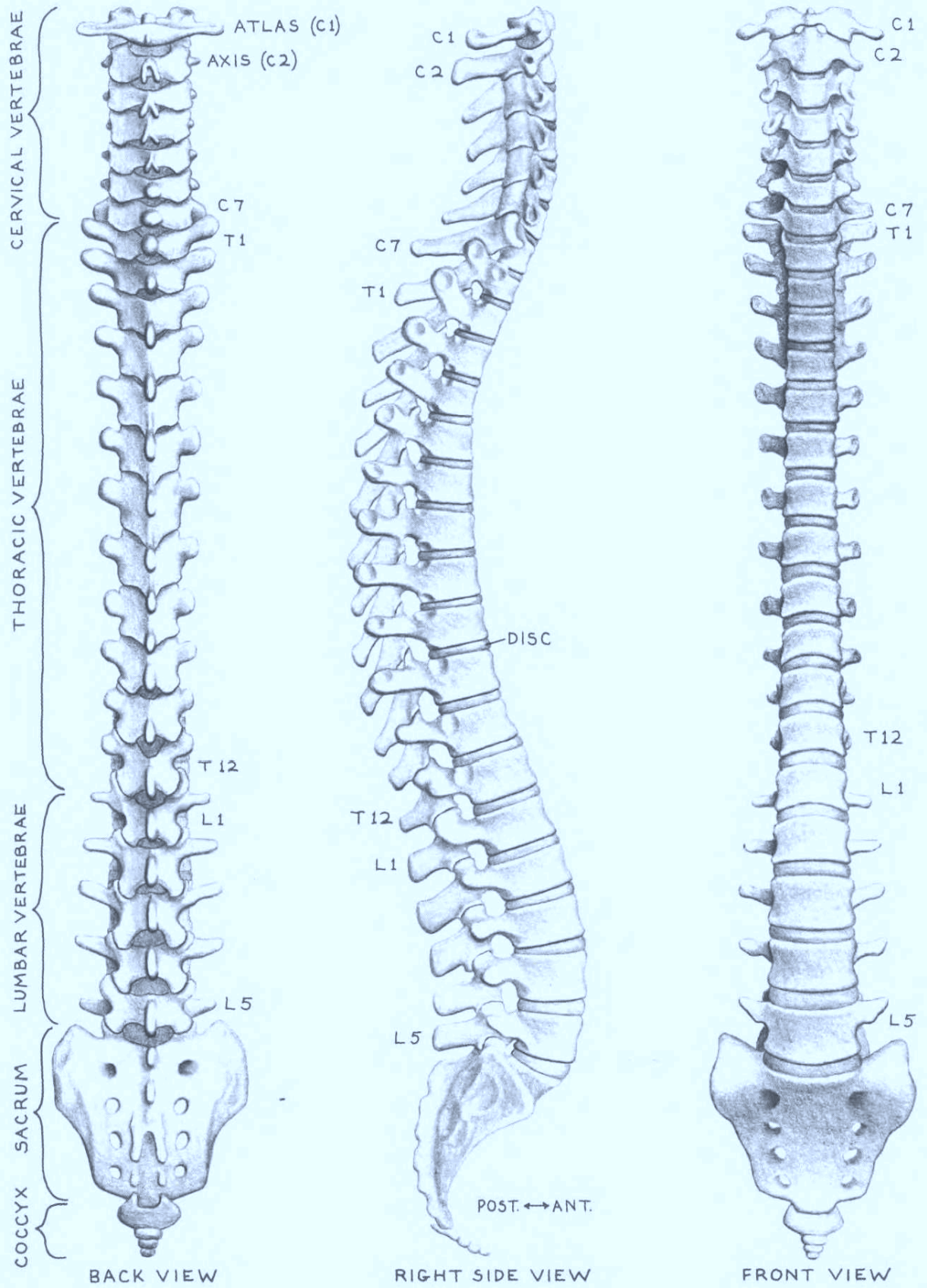
ELIOT GOLDFINGER

HUMAN ANATOMY FOR ARTISTS

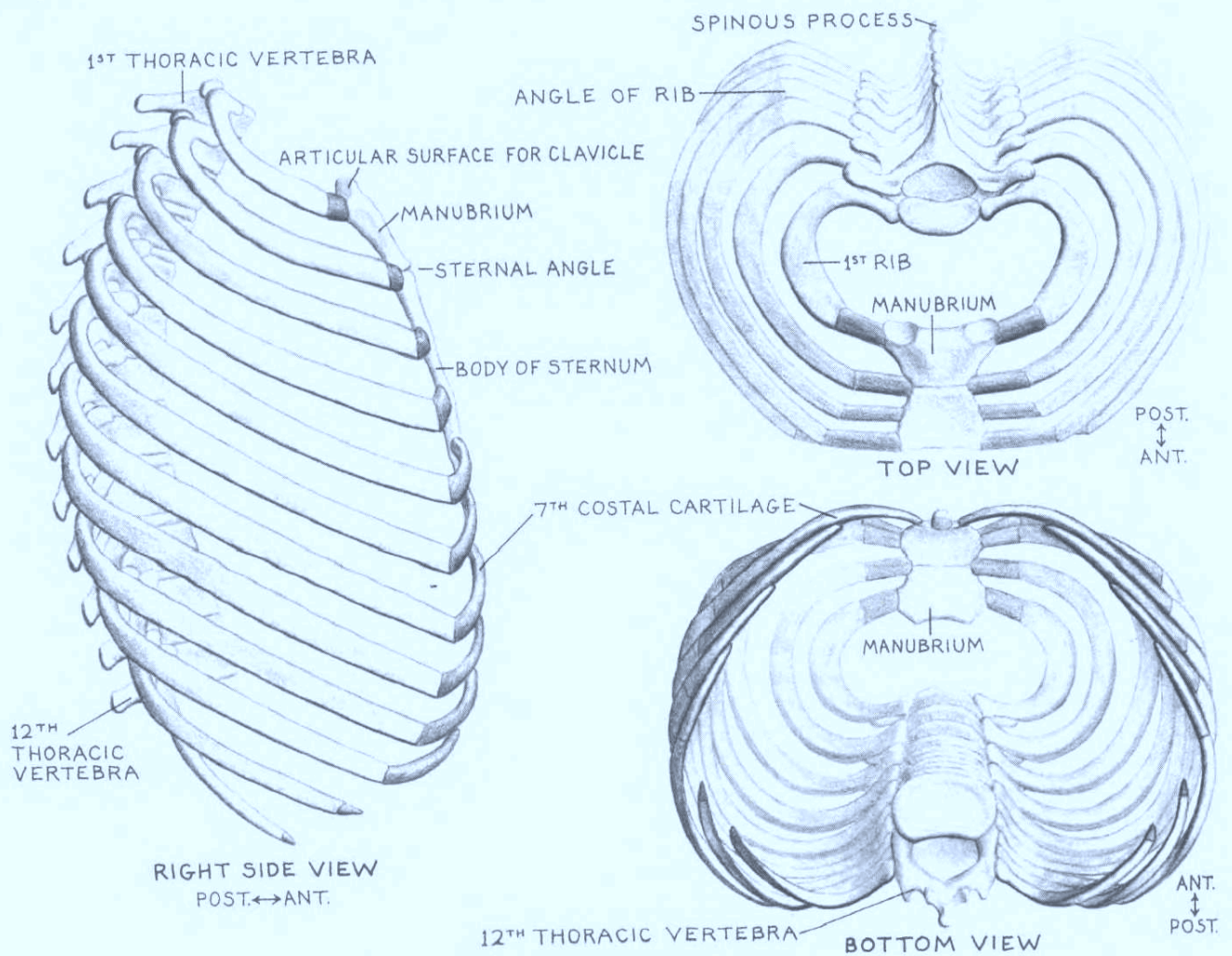
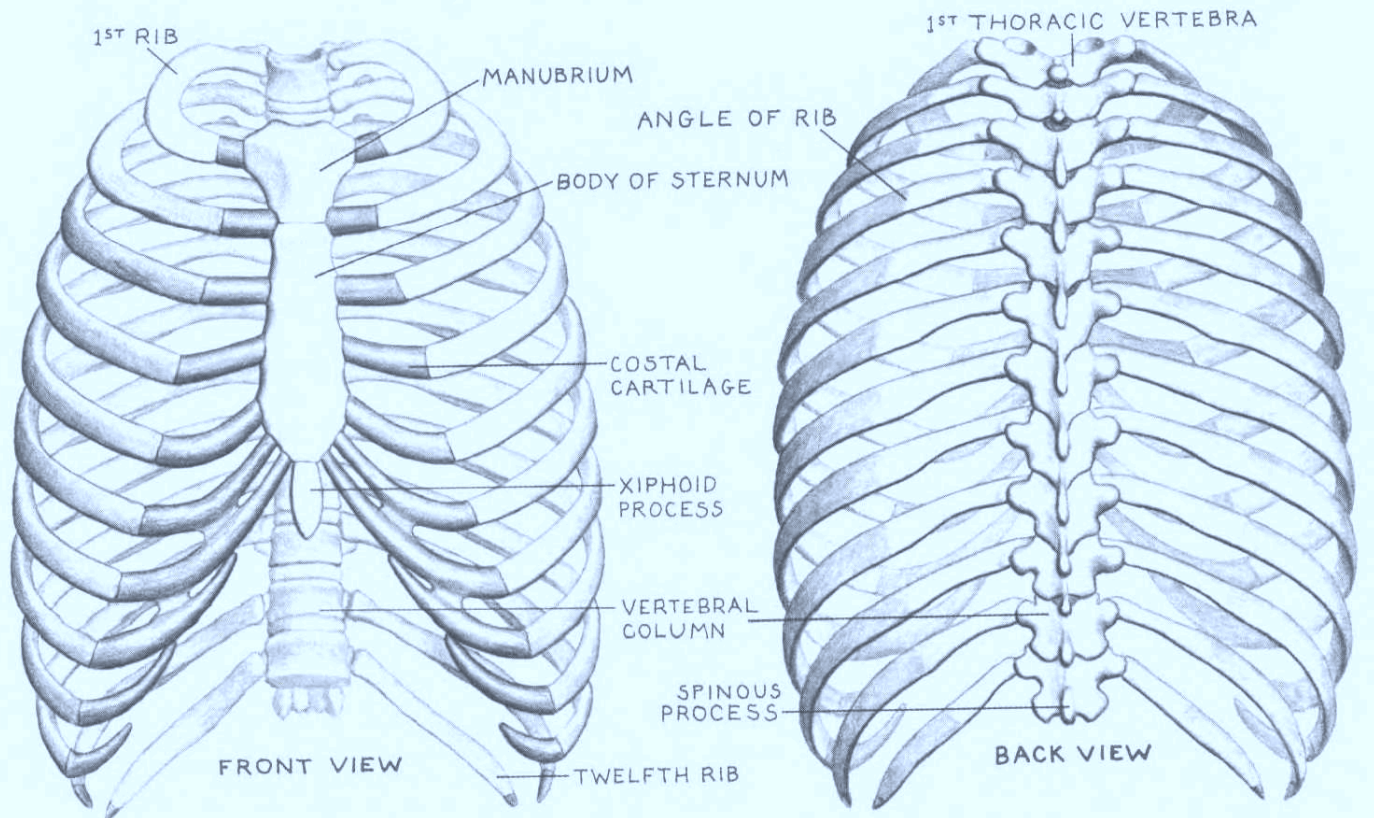
The Elements of Form

The Skeleton • SKULL

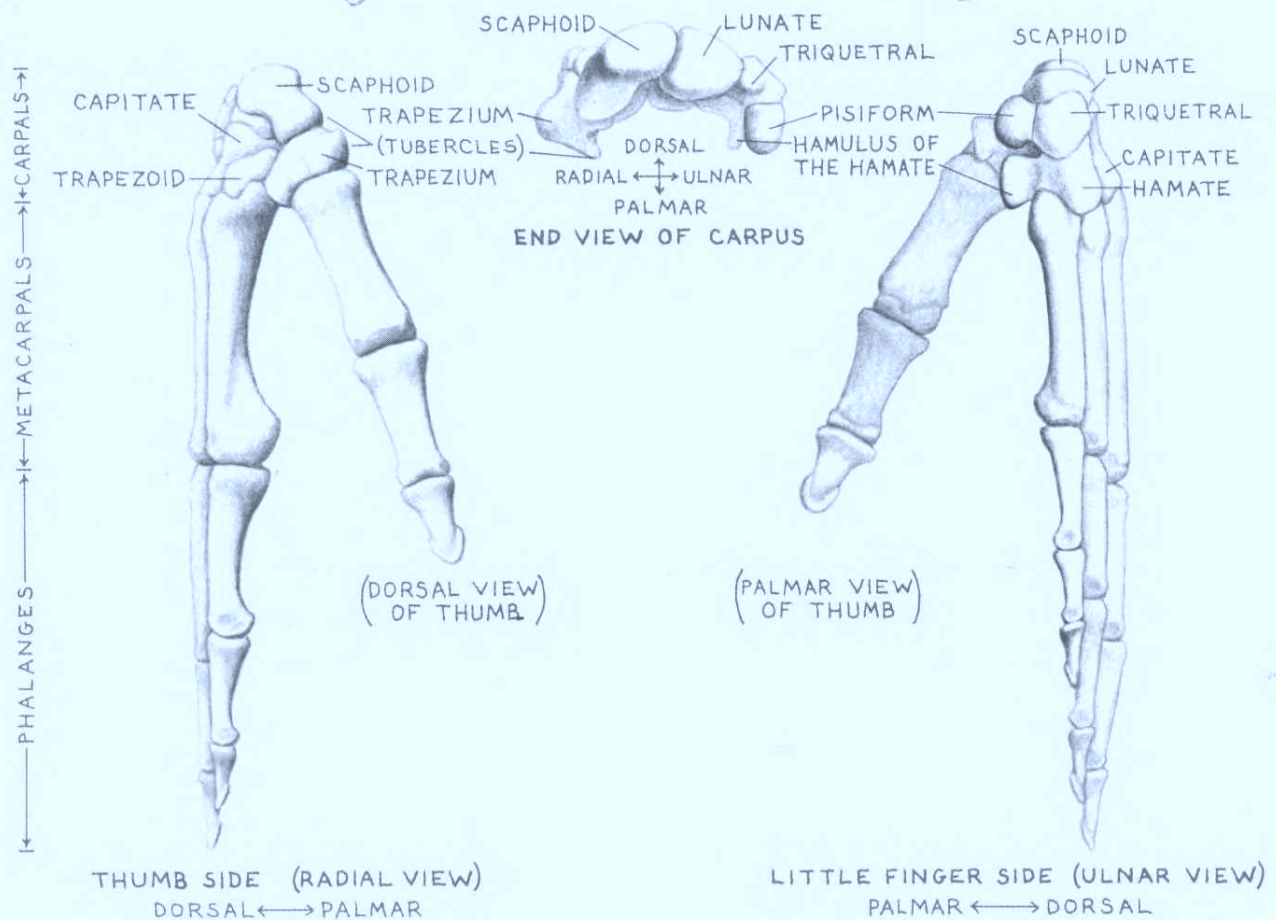
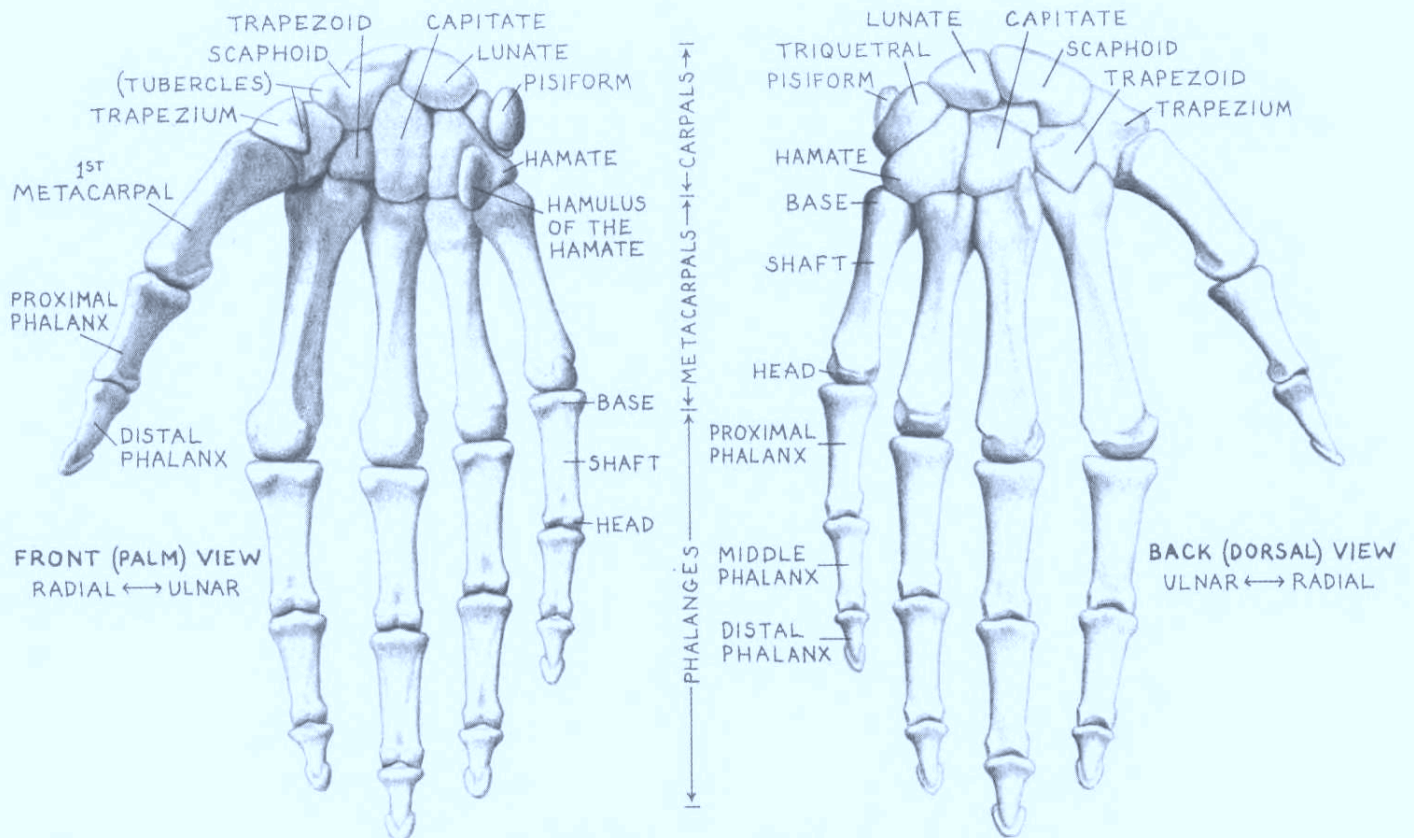




The Skeleton • RIB CAGE



The Skeleton • RIGHT HAND



The Skeleton • HAND

The *SKELETON OF THE HAND* is designed to perform the most heavy brutal chores, as well as extremely precise, sensitive, and delicate movements. In life, the hand is predominantly bony, with its surface form based for the most part on its skeleton, especially its back or dorsal surface. It consists of the carpus, the metacarpus, and the phalanges. The phalanges together are longer than the metacarpals, which in turn are longer than the carpals. These proportions are opposite to those found in the foot between the tarsals, metatarsals, and phalanges.

The *CARPUS* consists of eight small irregularly shaped **carpal bones** arranged in two rows—a proximal and a distal—of four bones each. The proximal row contains the **scaphoid**, **lunate**, **triquetral**, and **pisiform**. The distal row contains the **trapezium**, **trapezoid**, **capitate**, and **hamate**. As a unit, the carpal bones form half a disc which is curved side to side, so that its dorsal surface is convex; the concave palmar surface is transformed into the **carpal tunnel** for passage of the flexor tendons to the fingers.

On the back of the carpus, between the two carpal rows, is a depression (located toward the radial side). It is especially noticeable when the wrist joint is flexed. Also noticeable in this position is another depression between the distal end of the radius and the proximal carpal row (the articulating proximal surface of the carpus becomes a raised prominence between the two depressions).

On the palmar side of the carpus, bony prominences are formed by the pisiform at the ulnar side (at the base of hypothenar eminence) and by the tubercles of the trapezium and scaphoid together on the radial side (at the base of the thenar eminence). These bony projections are especially noticeable when the wrist joint is extended.

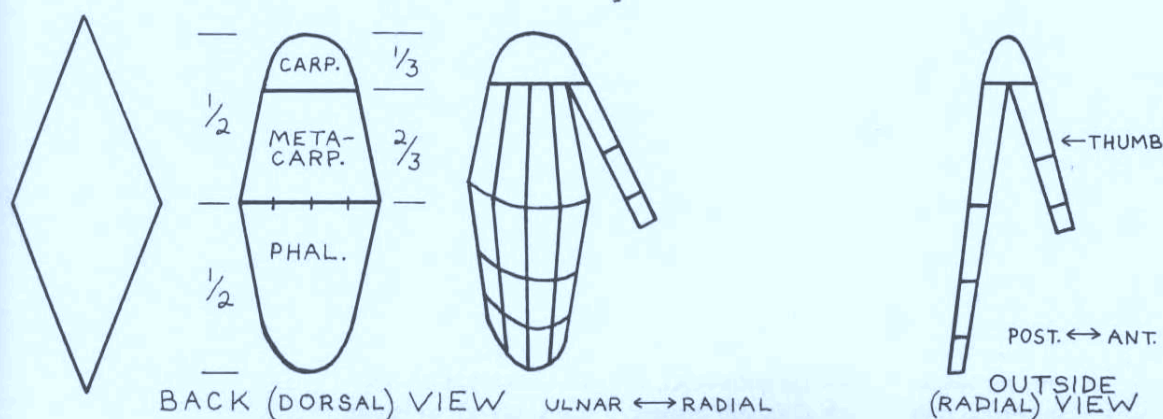
At the wrist joint, the arched proximal carpal row articulates primarily with the distal end of

the radius and minimally with the fibrous disc attached to the distal end of the ulna.

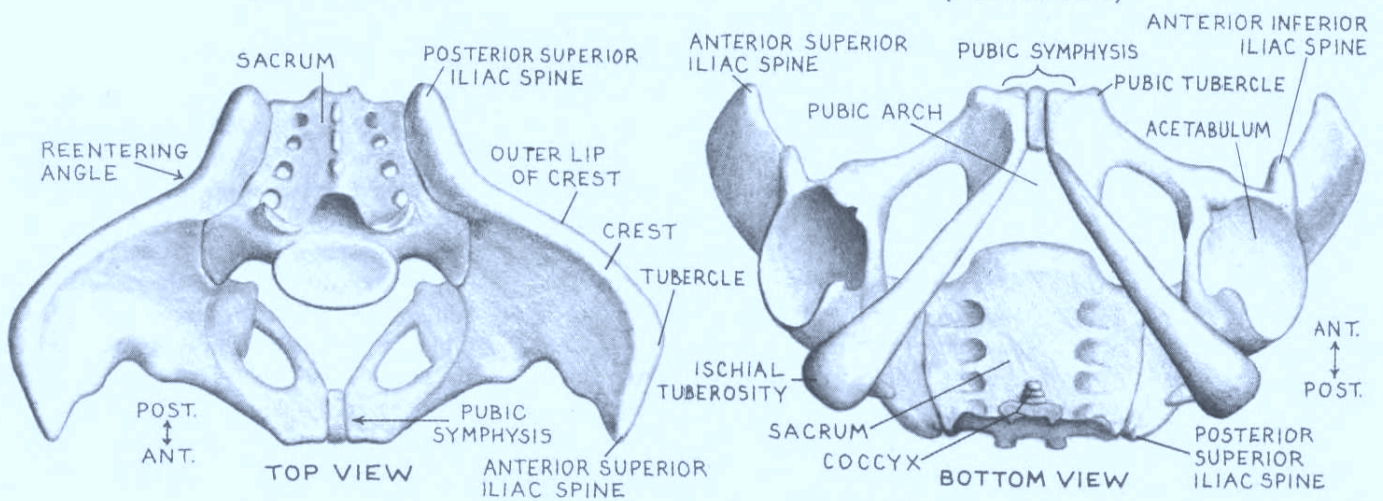
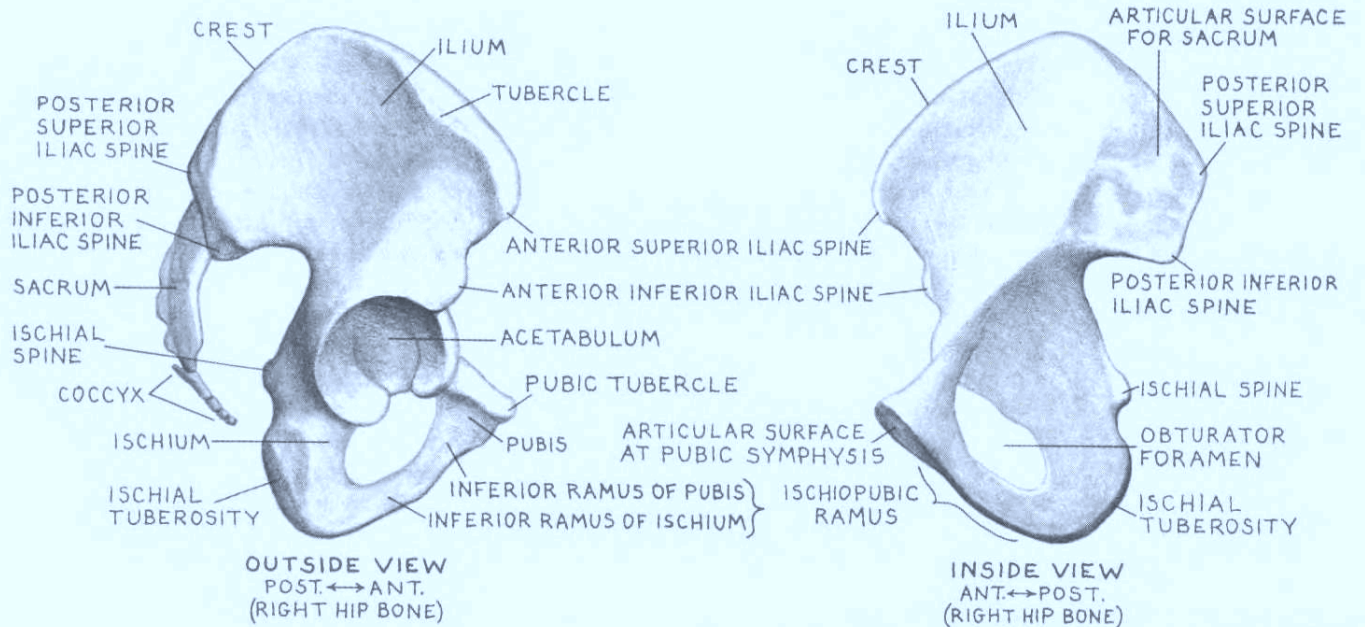
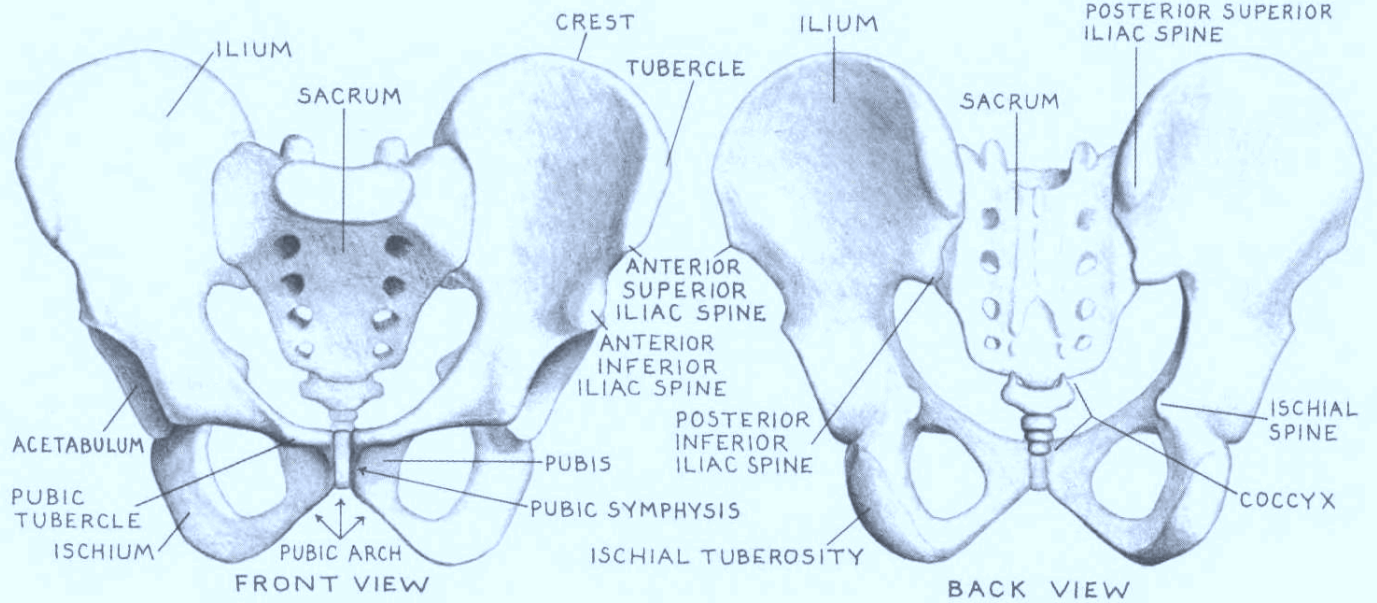
The *METACARPUS* consists of the five **metacarpal bones**. The boxlike **base** of each bone is located at the proximal extremity of the **shaft**, while the rounded **head** is located at the distal extremity. Metacarpals two through five (index to little finger) as a group radiate distally. The dorsal surfaces of the metacarpals are wide and flattened, especially distally, and all have a slight convex curvature. Metacarpals two through five create a plane on the back of the hand that curves side to side; it is especially noticeable at the knuckles. This curve, or **transverse arch**, helps create the concavity of the palm. The curvature of the transverse arch flattens when the open hand is pressed against a flat surface.

Distally, the heads of metacarpals two through five are connected to each other by ligaments; the head of the thumb is unattached, allowing it to have a great range of motion at the carpometacarpal joint and the ability to oppose the other fingers in grasping. The thumb's metacarpal is rotated around its long axis so that its dorsal surface faces laterally when the palm is directed forward (its dorsal surface is almost perpendicular to the dorsal surfaces of the other metacarpals).

The heads of metacarpals two through five are somewhat spherical. Their distal surfaces become exposed in life as rounded knuckles when the fingers are flexed at the metacarpophalangeal joints. These four metacarpals end distally along a curved line, with the middle finger projecting the farthest. The width across these four metacarpal heads is greater than the width across the humeral epicondyles at the elbow. Because the thumb's metacarpal head is not as rounded as the others, and because of limited motion at the metacarpophalangeal joint of the thumb, the distal surface of this metacar-



The Skeleton • PELVIS



The Skeleton • PATELLA

The *PATELLA*, or kneecap, is the largest sesamoid bone of the body. It is attached to the deep surface of the tendon of insertion of the quadriceps muscle of the thigh. The function of the patella is to move this tendon away from the joint, giving the quadriceps greater mechanical advantage. The deep surface of the patella articulates with the distal extremity of the femur, protecting the articular cartilages of the condyles, especially while kneeling.

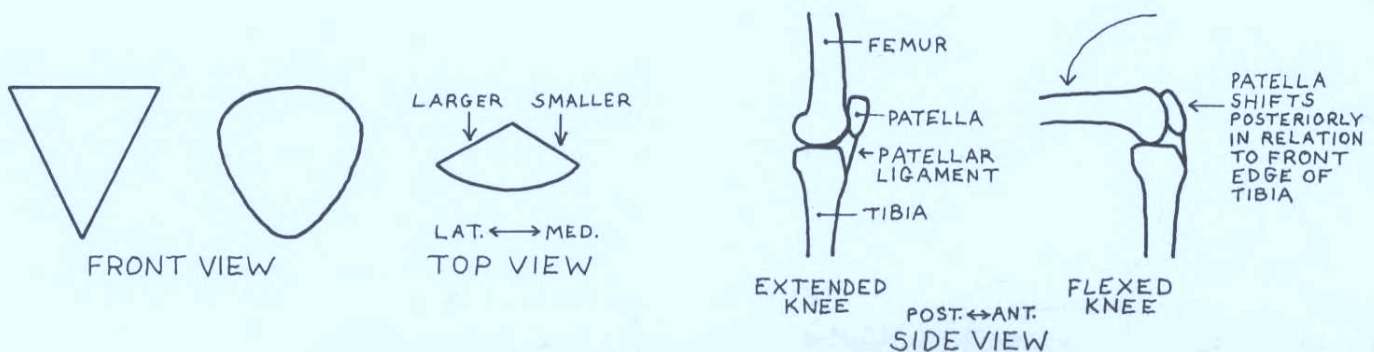
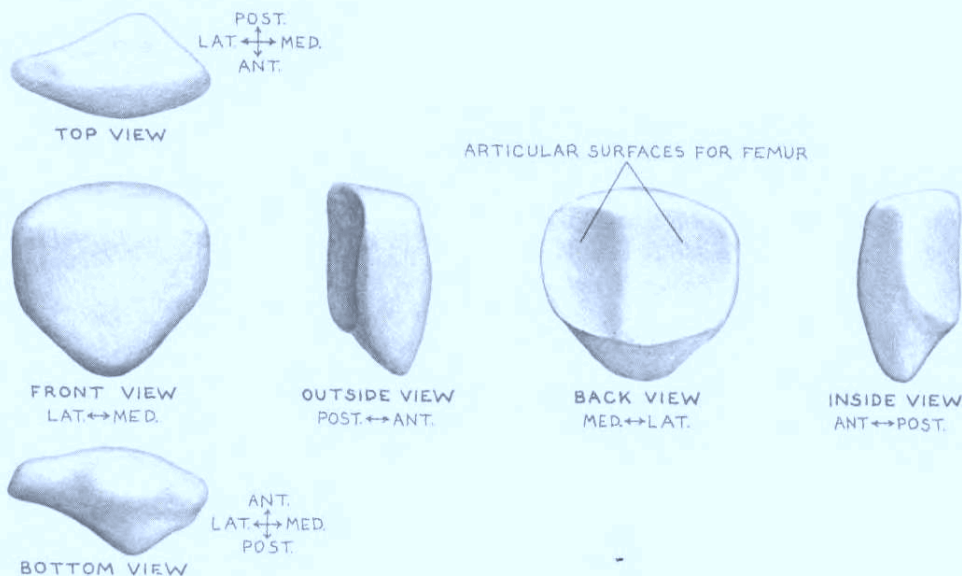
The patella is triangular with rounded corners and is flattened from front to back. Its apex is directed inferiorly. The two upper rounded corners are prominent on the surface in life. The anterior surface of the patella is convex, while the posterior surface has a wide vertical ridge which glides in the groove between the condyles of the femur. The inferior apex, attaching to the patellar ligament, is not seen on the surface in the straight extended knee; however, a horizontal skin furrow may appear at this attachment. When the knee is flexed, the anterior surface of the patella forms an angle with the patellar ligament, revealing the apex (in side view). The upper edge of the

patella is seen in the flexed knee, not in the extended knee, because the quadriceps tendon meets the patella at an angle during flexion.

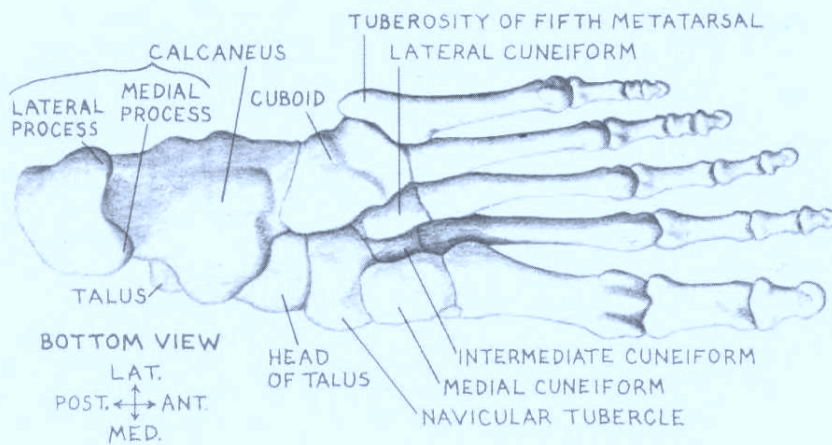
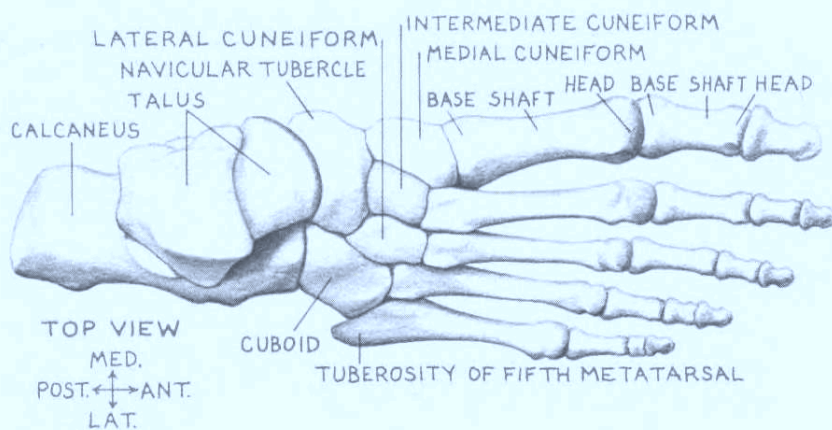
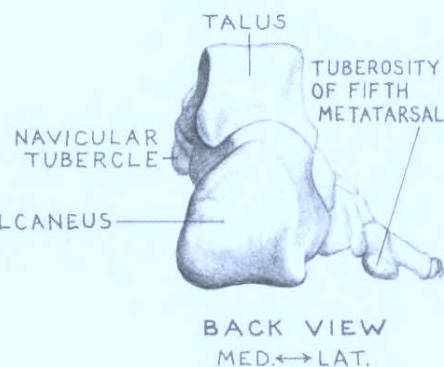
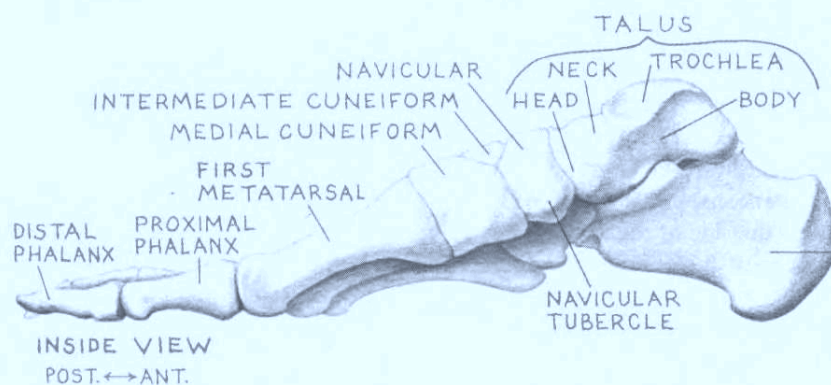
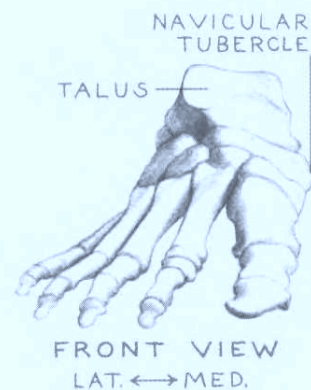
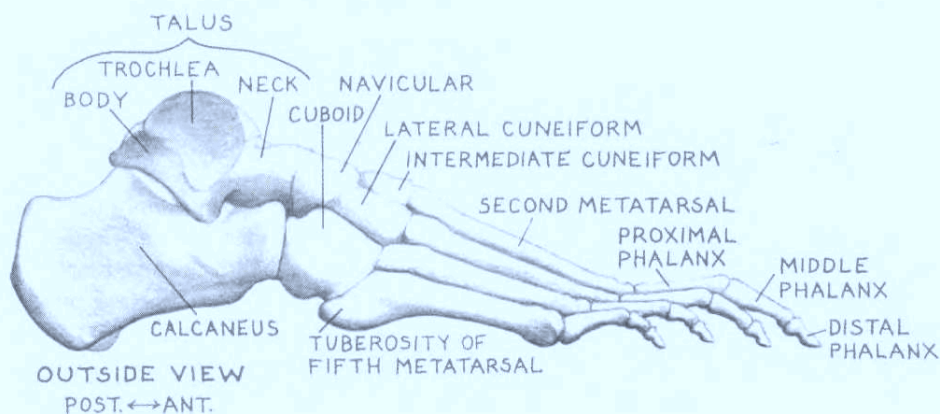
In the standing position with the thigh relaxed, the bottom of the patella sits at a level just slightly higher than the line of the knee joint; it rises slightly when the thigh muscles are tensed (with no motion taking place at the knee joint between the femur and tibia). The patella is wider than the distance across the *anterior* portion of the ridges of the medial and lateral condyles of the femur, and therefore covers a portion of these edges when the knee is extended.

When the knee is straight, the patella sits in the anterior shallow part of the femoral condyle groove. As the knee is flexed, the patella slides down into deeper parts of the groove. This action displaces the patella posteriorly in relation to the anterior profile of the lower leg. When the knee is flexed, the thigh appears longer, because the patella has been dragged around to the distal surface of the condyles of the femur, adding its thickness to the length of the thigh.

RIGHT PATELLA



The Skeleton • RIGHT FOOT



The Skeleton • FOOT

The **SKELETON OF THE FOOT** is designed to provide stability in supporting and distributing the body's weight and resiliency when receiving the impact of the body's weight while walking, running, and jumping. It also acts as a lever, pushing the body forward during locomotion. It is rigid upon takeoff and flexible upon impact. The foot skeleton is composed of the tarsus, metatarsus, and phalanges, and except for the phalanges of the lateral four toes, its bones are characterized by their thickness and strength. The phalanges are shorter than the metatarsals, which in turn are shorter than the tarsals. This arrangement is opposite to that found in the hand, where the carpus is short and the phalanges are long. In the foot, the big toe is restricted to lying parallel to the other toes, unlike the thumb, which is capable of opposing the other fingers.

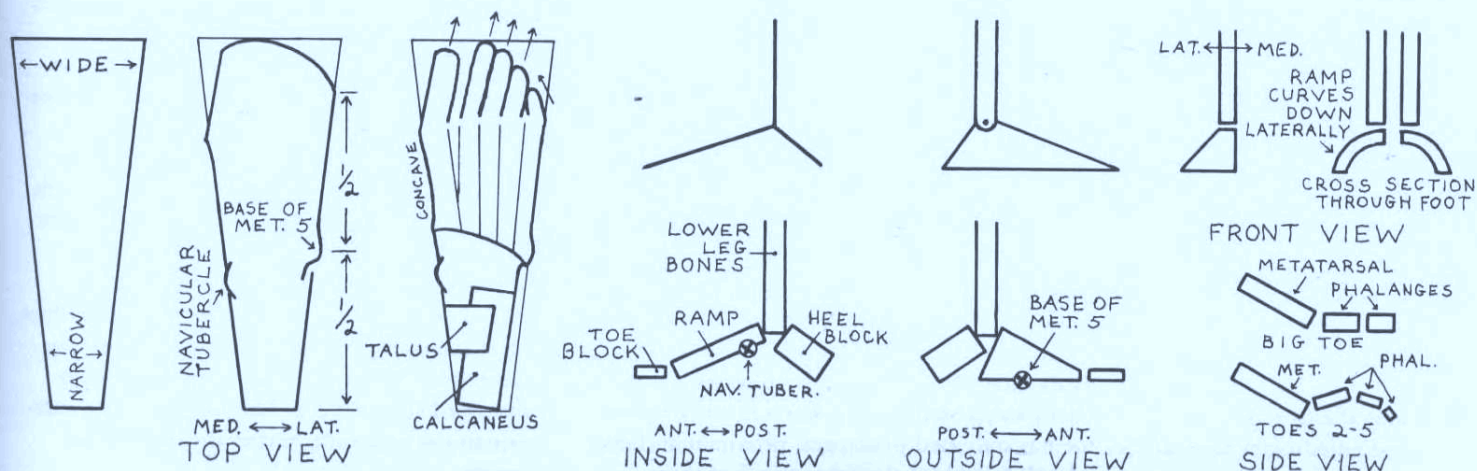
The foot has two perpendicular arches: a longitudinal arch from front to back and a transverse arch from side to side. These arches not only distribute weight but also afford the foot a degree of elasticity, providing shock absorption. The **longitudinal arch** is actually a series of five almost parallel (slightly radiating) arches passing through the long axes of the five toes. There is a high medial arch on the inside of the foot and a very low lateral arch on the outside (the base of the metatarsal of the little toe does not support weight in the foot flat on the floor). The **transverse arch** curves across the foot, bringing the outer edge of the foot down toward the ground. It is most noticeable at the midpoint of the foot, where it is high on the inside and low on the outside. The muscles, tendons, ligaments, and fasciae of the foot maintain these arches.

The **TARSUS** contains seven stout tarsal

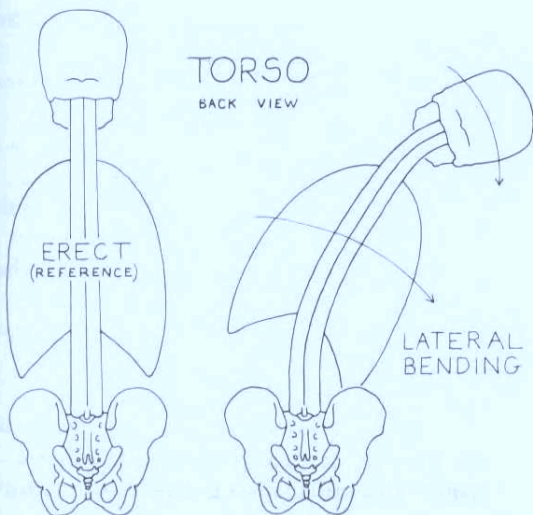
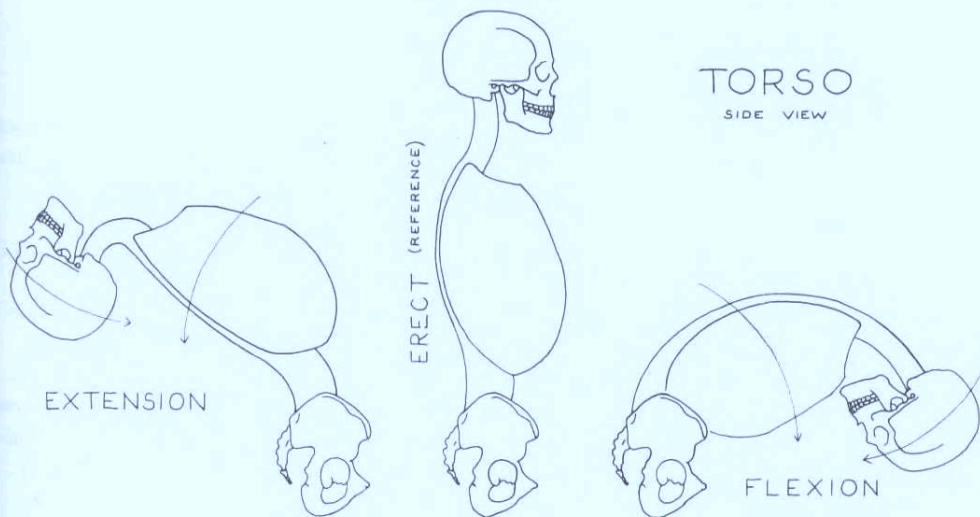
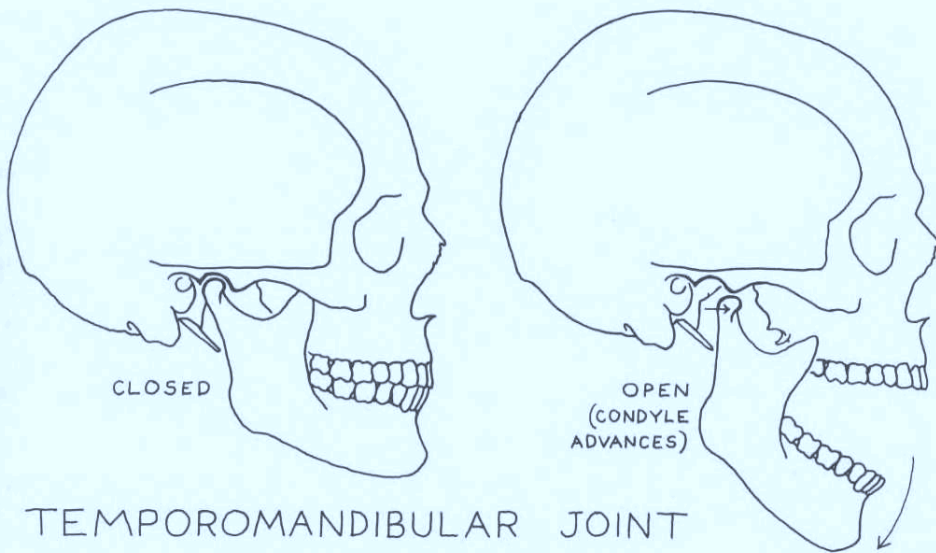
bones: the talus, calcaneus, cuboid, navicular, and three cuneiforms. There is substantial movement within the tarsus.

The **talus** (astragalus), located above the calcaneus near the back end of the medial side of the foot, consists of a **body**, an anteriorly projecting **neck**, and a rounded **head** in front. The upper articular portion of the body, the **trochlea**, is spool-shaped. It is the highest bone of the foot and articulates superiorly with the tibia and fibula to form the ankle joint. Only flexion and extension are possible at this joint. The talus articulates inferiorly with the calcaneus at the **subtalar joint** and anteriorly with the navicular. The subtalar joint permits inversion and eversion of the foot. The lateral edge of the trochlea of the talus becomes visible on the surface in front of the lateral malleolus of the fibula during extreme plantar flexion of the foot (toe pointing). During inversion of the foot (facing the foot inward), the lateral part of the head of the talus shows under the tendons of the extensor digitorum longus, while the medial part of the head shows during eversion (facing the foot outward) between the medial malleolus and the navicular tubercle. These points of the talus, when seen, appear as subtle prominences.

The **calcaneus**, or heel bone, is blocklike, flattened side to side, and rounded on its posterior surface. It is the largest foot bone. It is inclined upward, forward, and slightly laterally, resting its lower back edge on the ground (protected below by the fatty cushion of the sole of the foot). The calcaneus acts as a lever. Most of the lateral surface and part of the posterior surface (between the insertion of the Achilles tendon and the heel cushion) are subcutaneous. The Achilles tendon conceals the upper part of its back surface.



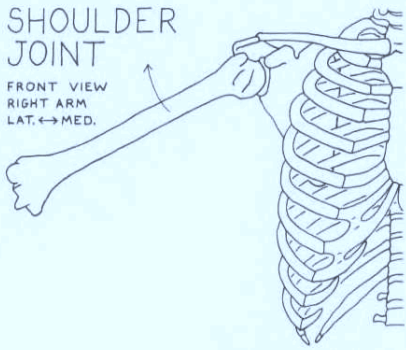
The Joints



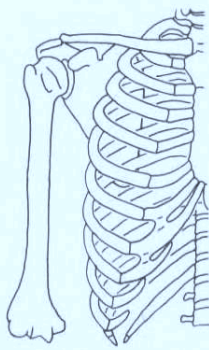
The Joints

SHOULDER JOINT

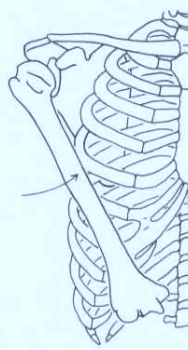
FRONT VIEW
RIGHT ARM
LAT. ↔ MED.



ABDUCTION



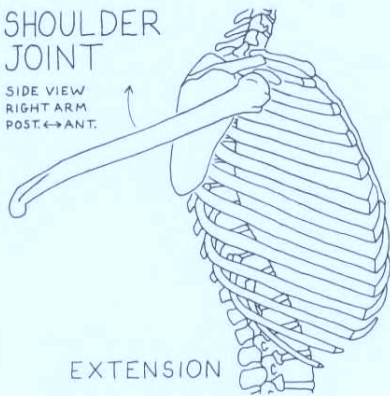
REFERENCE



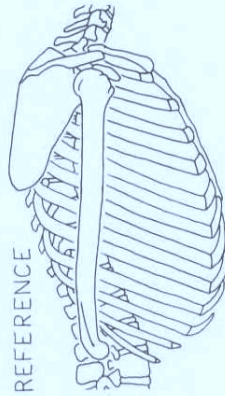
ADDUCTION
(WITH SLIGHT FLEXION)

SHOULDER JOINT

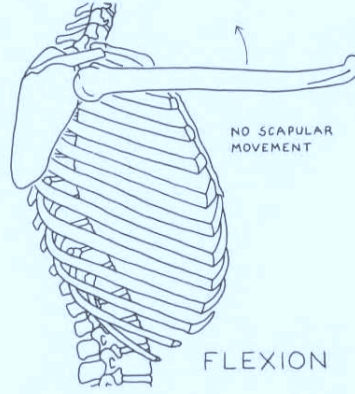
SIDE VIEW
RIGHT ARM
POST. ↔ ANT.



EXTENSION

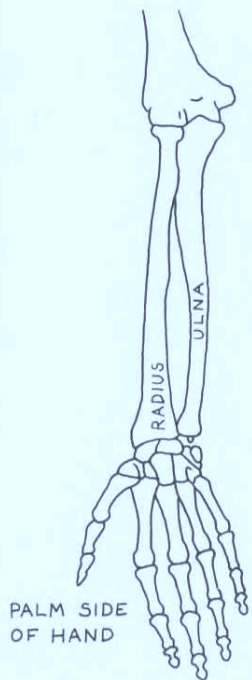


REFERENCE



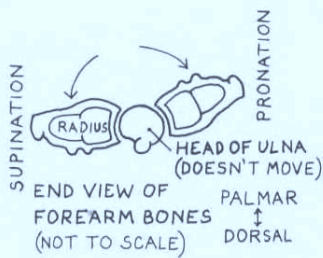
FLEXION

NO SCAPULAR
MOVEMENT



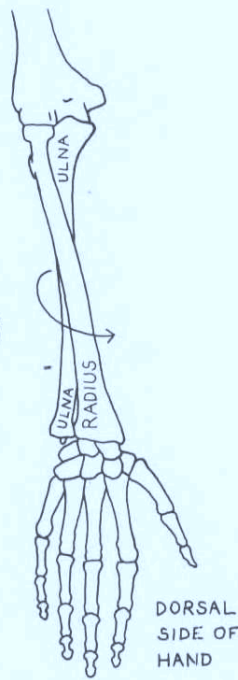
PALM SIDE
OF HAND

SUPINATION
(REFERENCE)



RIGHT FOREARM

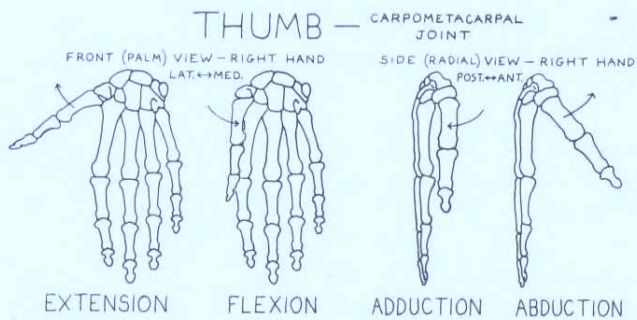
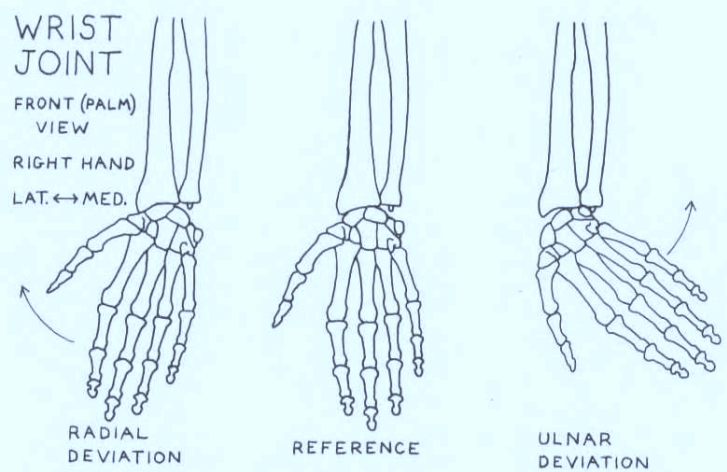
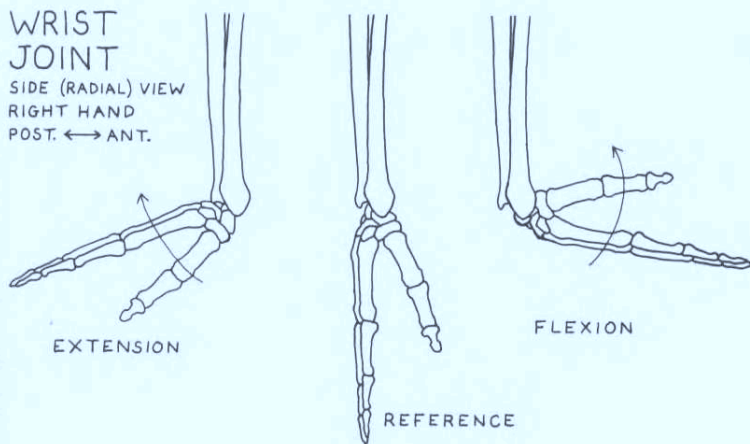
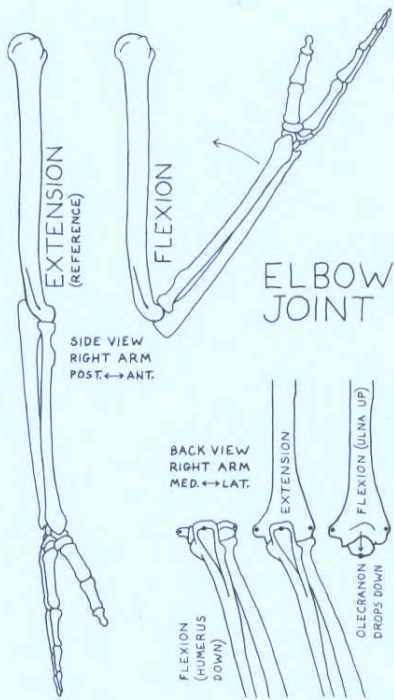
FRONT VIEW
LAT. ↔ MED.



DORSAL
SIDE OF
HAND

PRONATION

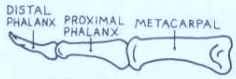
The Joints



The Joints

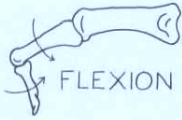
THUMB

OUTSIDE (RADIAL) VIEW
RIGHT HAND



REFERENCE

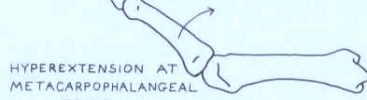(SLIGHT HYPEREXTENSION AT INTERPHALANGEAL JOINT)



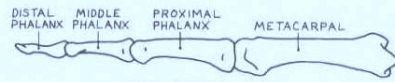
FLEXION

INDEX FINGER

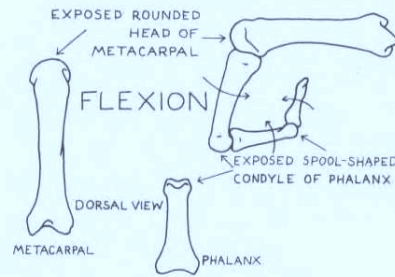
OUTSIDE (RADIAL) VIEW
RIGHT HAND



HYPEREXTENSION AT
METACARPOPHALANGEAL
JOINT



REFERENCE



FLEXION

EXPOSED SPOOL-SHAPED
CONDYLE OF PHALANX

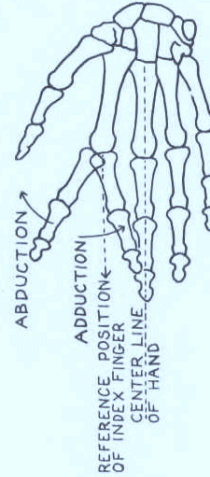
DORSAL VIEW

METACARPAL

PHALANX

METACARPO- PHALANGEAL JOINT

FRONT (PALM) VIEW
RIGHT HAND
LAT. \leftrightarrow MED.



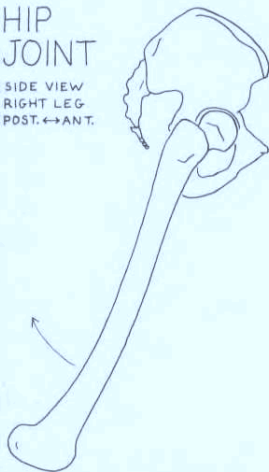
ABDUCTION

ADDUCTION

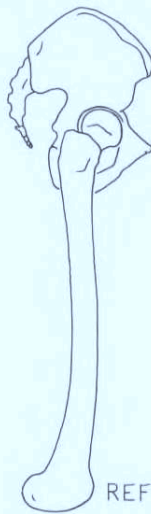REFERENCE POSITION
OF INDEX FINGER
CENTER LINE
OF HAND

HIP JOINT

SIDE VIEW
RIGHT LEG
POST. \leftrightarrow ANT.



EXTENSION



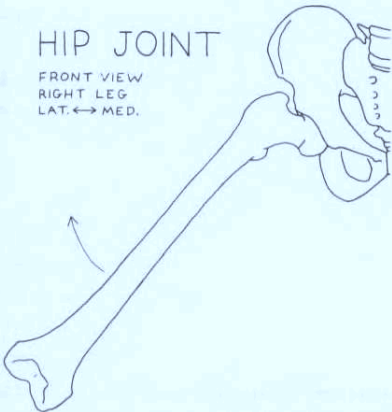
REFERENCE

FLEXION

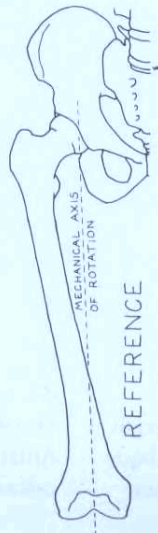


HIP JOINT

FRONT VIEW
RIGHT LEG
LAT. \leftrightarrow MED.

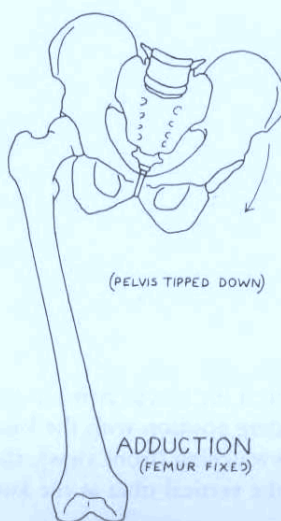


ABDUCTION



MECHANICAL AXIS
OF ROTATION

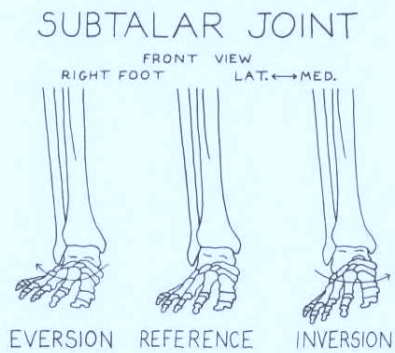
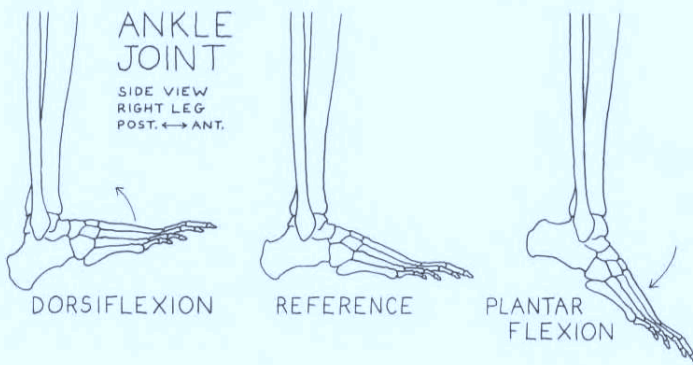
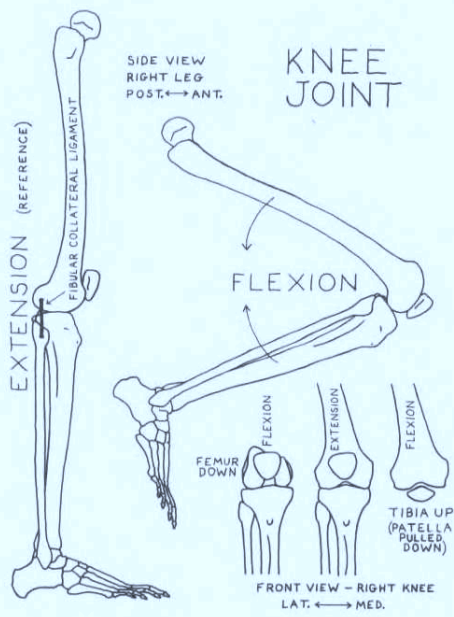
REFERENCE



(PELVIS TIPPED DOWN)

ADDUCTION
(FEMUR FIXED)

The Joints



The Joints

BIG TOE
INSIDE VIEW
RIGHT FOOT
ANT. ↔ POST.
HYPEREXTENDED
METATARSOPHALANGEAL
JOINT (PUSH-OFF)

EXTENSION
DISTAL PHALANX
PROXIMAL PHALANX
METATARSAL

REFERENCE
(FOOT ON GROUND)

FLEXION

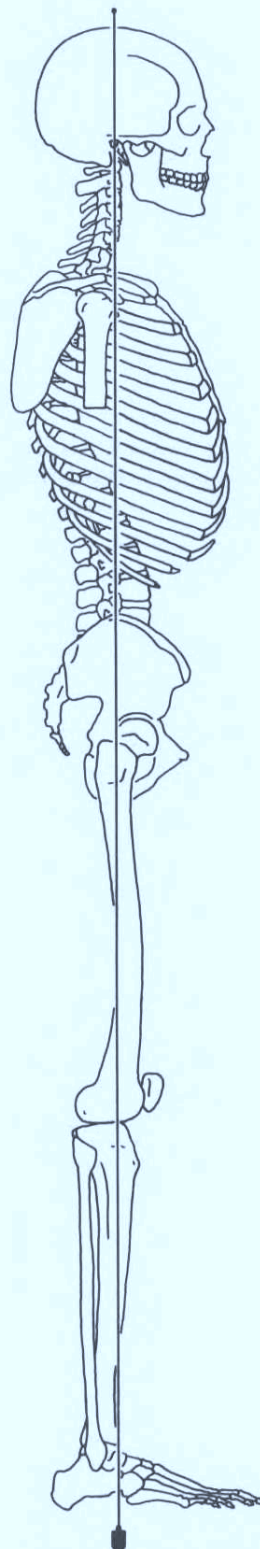
2ND TOE

OUTSIDE VIEW
RIGHT FOOT
POST. ↔ ANT.

EXTENSION

METATARSAL
PROXIMAL PHALANX
MIDDLE PHALANX
DISTAL PHALANX
REFERENCE
(FOOT ON GROUND)

FLEXION



ALIGNMENT
SIDE VIEW

usually not possible to make a fist when the wrist is fully flexed, because the finger flexors are too short to contract further (active insufficiency) and the finger extensors are fully stretched (passive insufficiency), preventing the fingers from flexing fully.

In analyzing muscular activity, it is important to think in terms of the combined actions of all the muscles in a given area—some work individually, others work as groups; some stabilize one region of the body while others create motion in another region; some begin an action while other muscles complete it; some oppose the pull of gravity. During complex actions, note the *sequence* of the contraction and relaxation of the numerous muscles that are functioning. Observe the action, visualize the skeleton deep in the body and what changes are taking place at its joints, and then determine which muscles are working in order to perform that action. For further information on function, refer to the most recent updated medical, physiology, kinesiology, and physical therapy texts.

Form

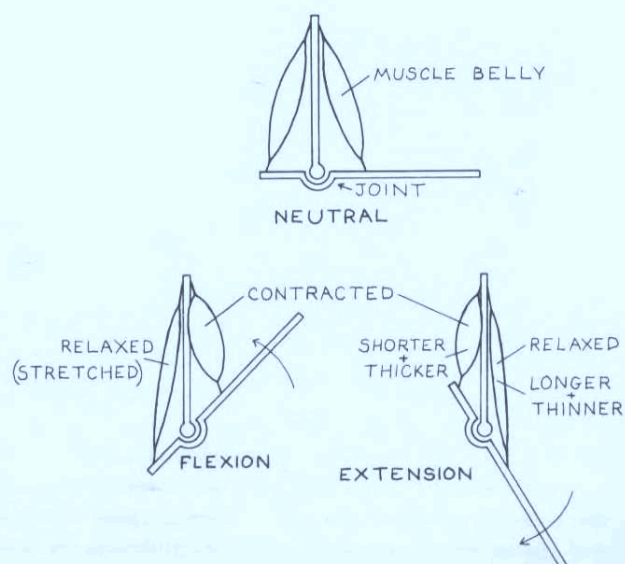
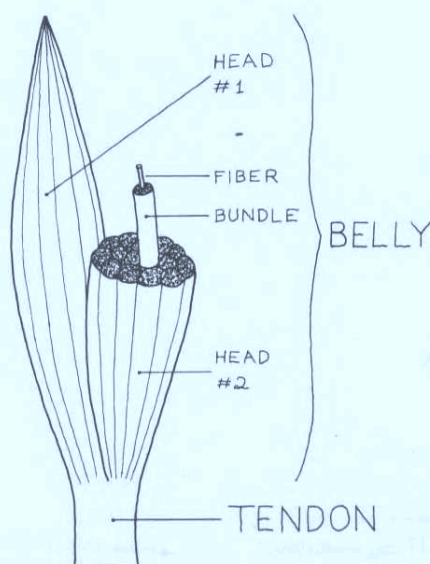
The muscles of the body are independent convex forms, and when placed side by side and one on top of the other to make up the figure, they structure the figure into a series of adjacent, bulging, convex forms which are covered by the skin. An appreciation of the *fullness of these convexities* will produce artwork with vitality and a feeling of energetic inner life radiating from the center outward. True concavities show up only rarely in the body, and one must be careful not to mistake a series of convexities for a concavity. Know the attachments of mus-

cles, because that is where their *form* begins and ends. *Know the basic individual shapes of each muscle.* Think of the form of a muscle as a swollen axis passing between the centers of its areas of attachment.

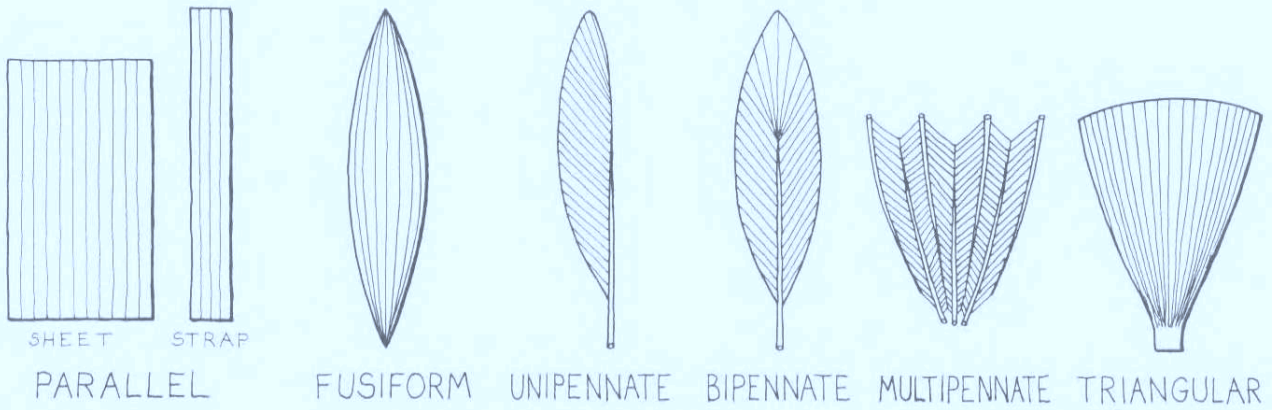
Beware of illustrations that simply diagram the surface muscles' outlines without giving indication of the deeper structures that may actually be creating the forms we see (very little of the form of the latissimus dorsi is directly seen; it is the forms of the deeper structures—erector spinae, serratus anterior, teres major, and rib cage—that create surface form). Keep in mind that the form of one muscle can blend with the form of another muscle or with fat pads, that the shapes of muscles are sometimes affected by overlying fascia, that muscles appear shorter and thicker when contracted and longer and thinner when stretched, and that they become more defined when they are contracted. In other words, the same muscle will appear differently in different actions and poses.

The artist must understand all the anatomical components that create human surface form, and when studying the living model, be able to mentally impose these structures diagrammatically on the model. For while everything is there, most of it is usually concealed to the untrained eye. It becomes the artist's job to analyze, select, and then create.

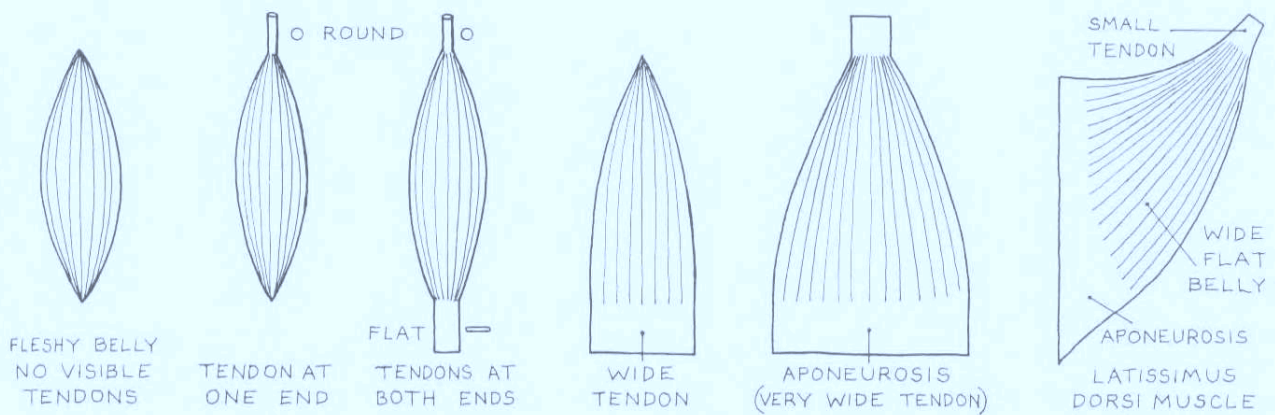
Note: In the following illustrations, muscle attachments on the skeleton are indicated by solid red areas, while nonbony attachment areas are usually indicated by red cross-hatching. They are labeled O for origin and I for insertion. A curved arrow indicates that an attachment is hidden from view. *All illustrations are of the right side of the body.*



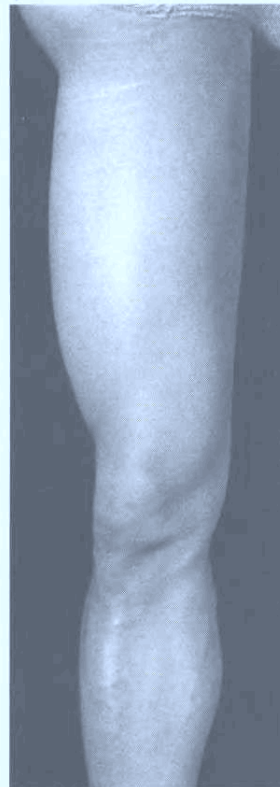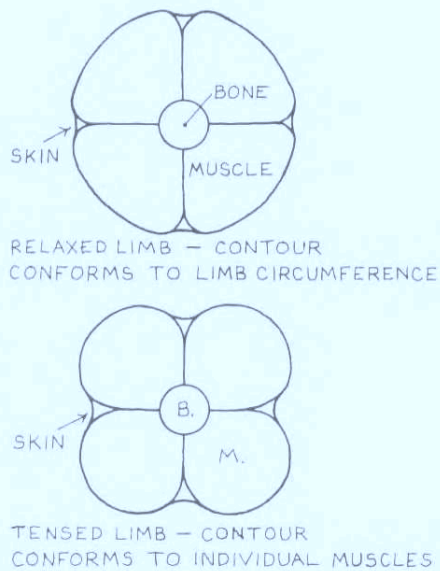
MUSCLE TYPES



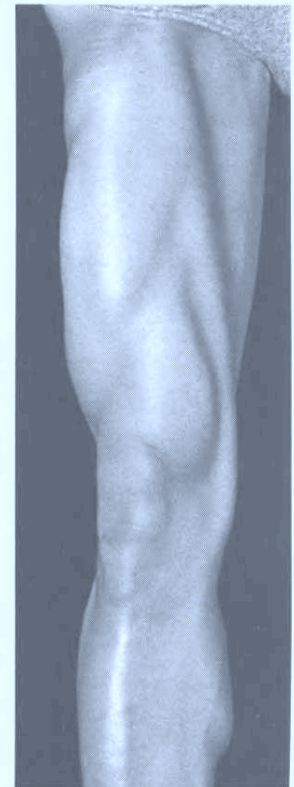BELLY-TENDON RELATIONSHIPS



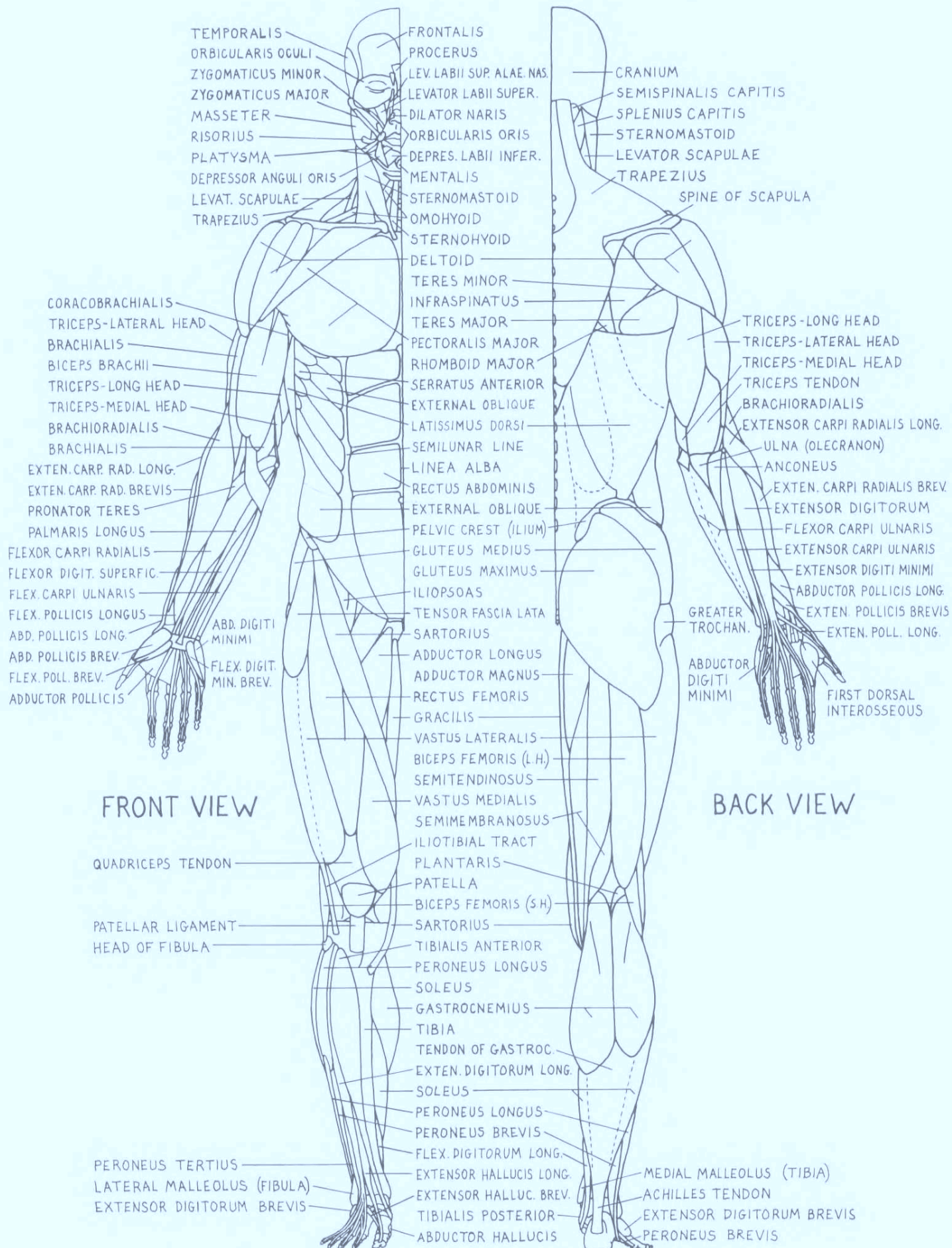
STYLIZED LIMB CROSS SECTION



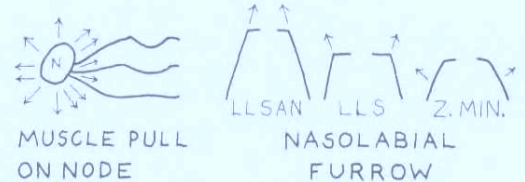
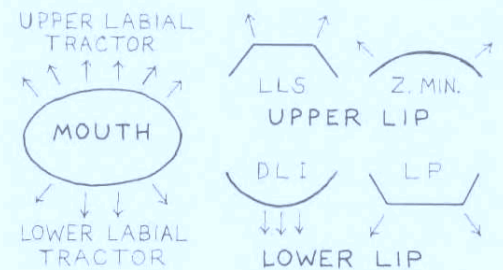
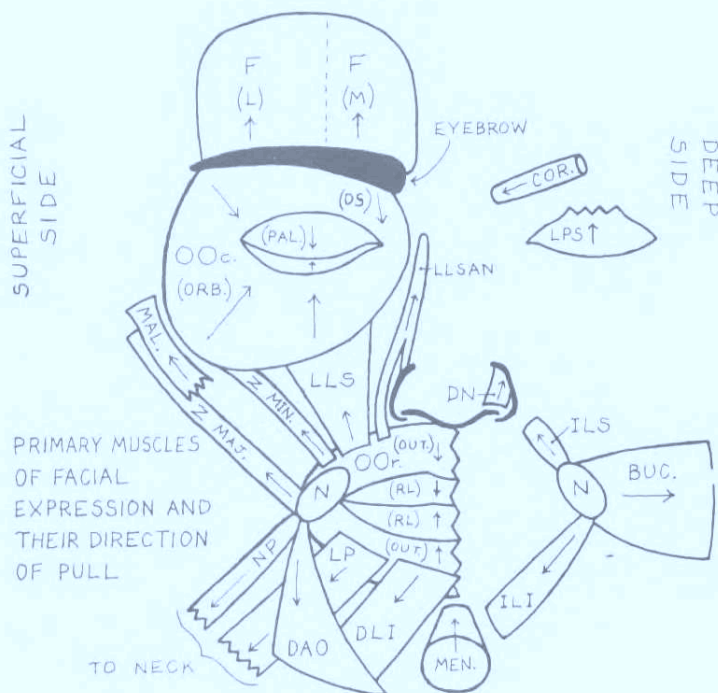
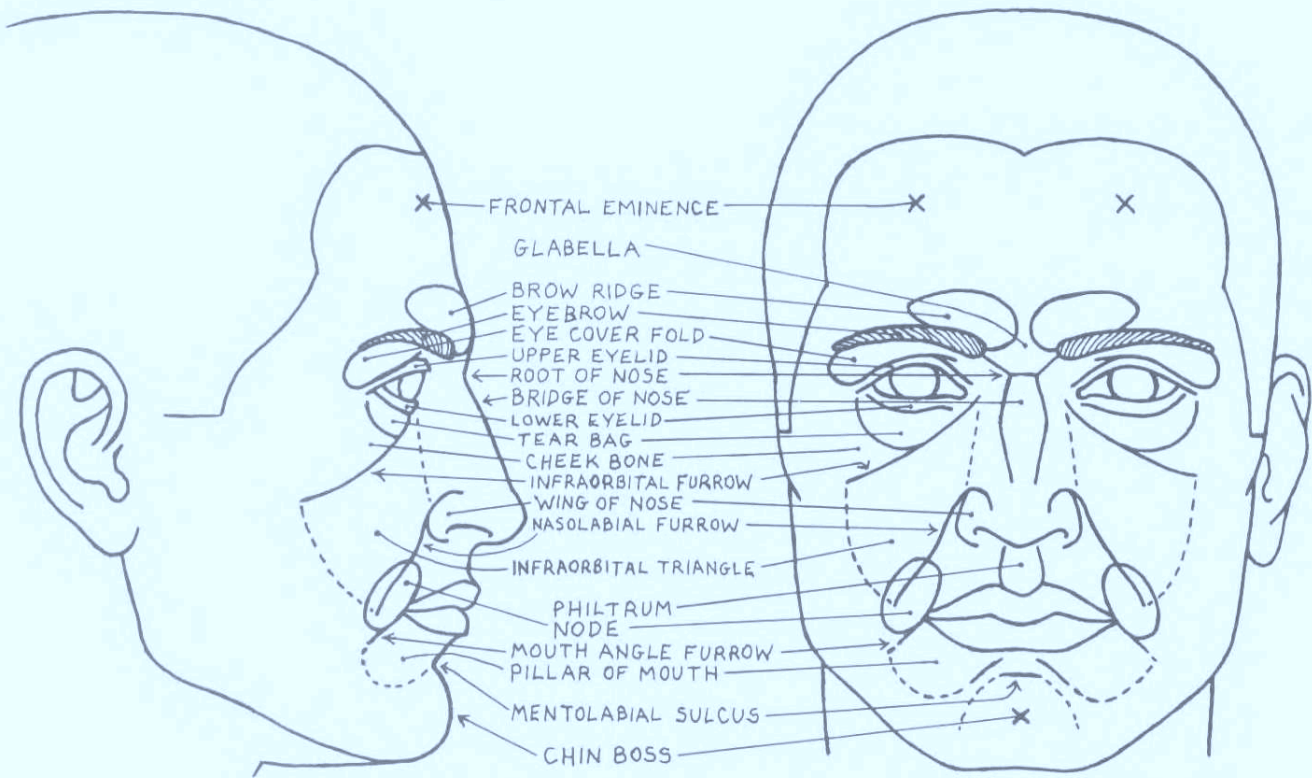
Relaxed limb



Tensed limb

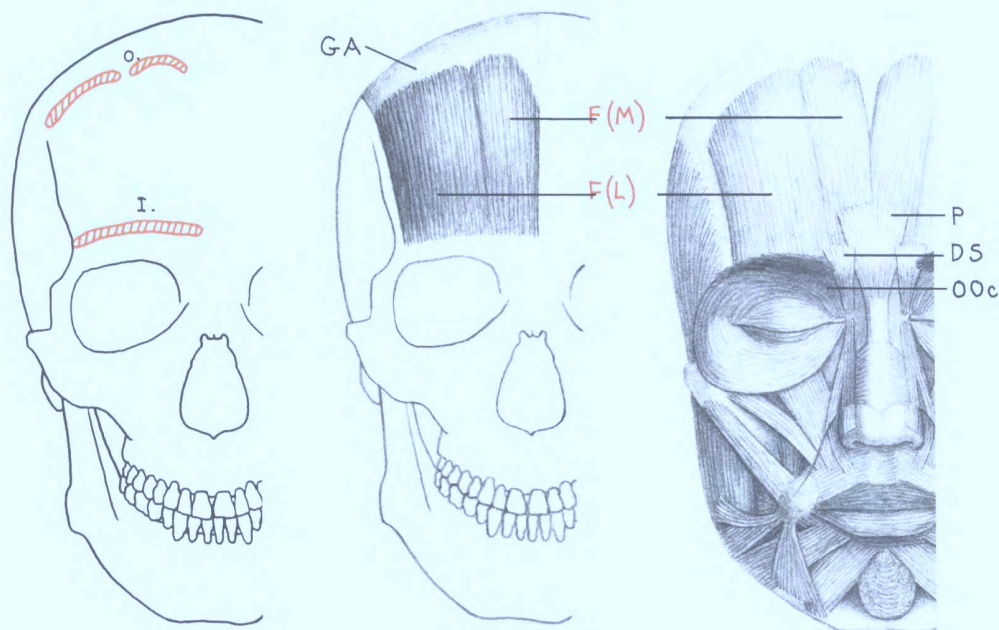


The Facial Muscles



BUC Buccinator COR Corrugator supercilii DAO Depressor anguli oris
 DLI Depressor labii inferioris DN Dilator naris DS Depressor supercilii
 F(L) Frontalis—lateral portion F(M) Frontalis—medial portion ILI Incisivus labii inferioris
 ILS Incisivus labii superioris LLS Levator labii superioris LLSAN Levator labii superioris alaeque nasi
 LP Labial platysma LPS Levator palpebrae superioris MAL Malaris MEN Mentalis N Node
 NP Nodular platysma OOc(ORB) Orbicularis oculi—orbital portion
 OOc(PAL) Orbicularis oculi—palpebral portion OOr(OUT) Orbicularis oris—outer portion
 OOr(RL) Orbicularis oris—red lip portion ZMAJ Zygomaticus major ZMIN Zygomaticus minor

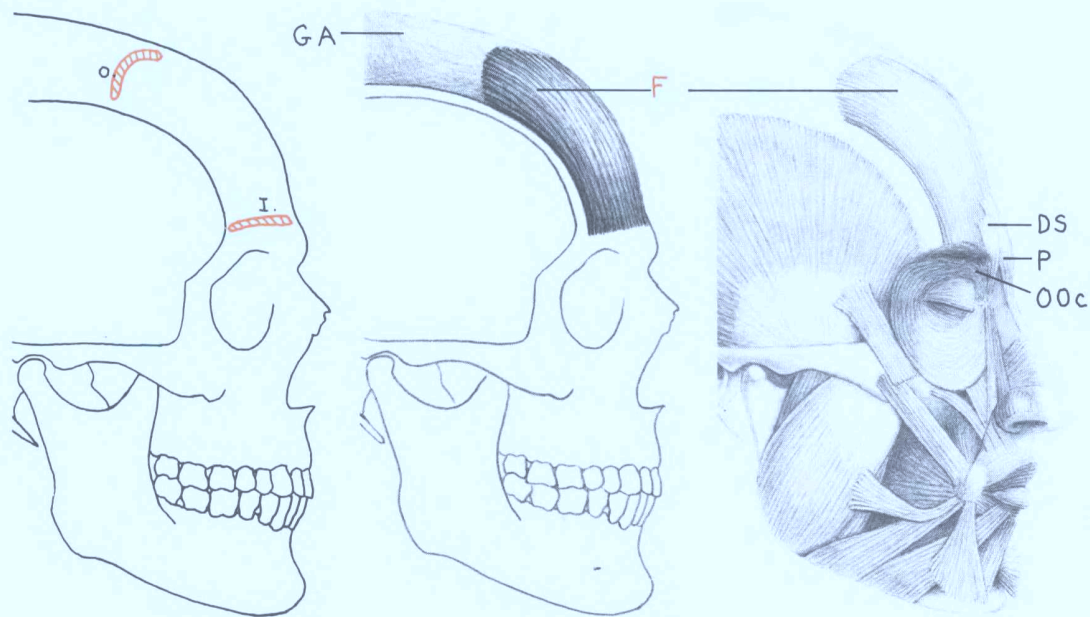
The Facial Muscles • FRONTALIS



MEDIAL + LATERAL PORTIONS



MEDIAL PORTION (+ CORRUG.)



MEDIAL + LATERAL PORTIONS



MEDIAL PORTION (+ CORRUG.)

DS Depressor supercilii F(L) Frontalis—lateral portion F(M) Frontalis—medial portion
GA Galea aponeurotica OOc Orbicularis oculi P Procerus

Frontalis

The **frontalis** is the anterior muscle belly of the extensive epicranial muscle.

The **epicranial muscle** consists of a broad layer of tendon (the galea aponeurotica) and thin muscle bellies; it covers the top and sides of the skull, from the brows in front to the base of the skull in back, and over to the tops of the ears.

ORIGIN The front edge of the galea aponeurotica, just posterior to the top of the forehead.

INSERTION The skin at the eyebrow and root of the nose, blending with the fibers of the procerus, orbicularis oculi, and corrugator supercilii.

ACTION *Medial and lateral portions together:* Raise the entire eyebrow, increasing its overall curvature (the central portion is pulled higher). They also pull the scalp (hairline) slightly forward as they pull on the galea aponeurotica. *Medial portion only:* Pulls up the medial end of the eyebrow. *Lateral portion only:* Pulls the middle and lateral end of the eyebrow upward, giving the eyebrow a strong curvature.

The medial portions of both sides of the face always contract together and are almost always accompanied by contraction of the corrugator supercilii (as in sadness). The lateral portion only occasionally contracts by itself, and usually in one eyebrow only.

STRUCTURE The frontalis is divisible functionally into medial and lateral parts. The two frontalis bellies of the head are in contact with each other at their lower portion, on the midline of the forehead.

EFFECT Contraction of the frontal bellies produces horizontal wrinkles across the forehead. The wrinkles are superiorly curved above each eyebrow and dip downward on the centerline. When only the medial part of the frontal belly contracts, horizontal wrinkles form on the center of the forehead only. In this case the medial

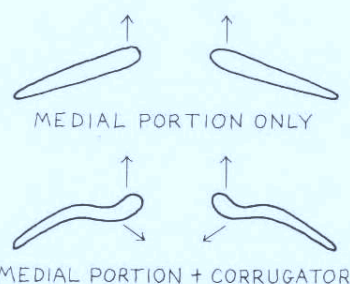
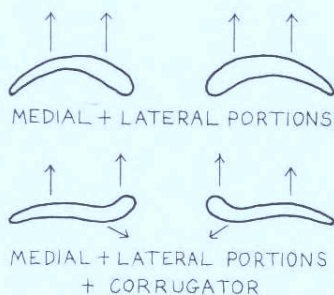
ends of the eyebrows are pulled upward. However, depending on the position (obliquity) of the eyebrows in the resting position, the medial ends may not appear to have been raised. Horizontal wrinkles on the center of the forehead are diagnostic of medial frontalis contraction. Because the corrugator typically contracts when only the medial frontalis contracts, the eyebrow develops a “kinking” near its medial end or an overall S-shaped curvature; its medial end is pulled upward by the medial frontalis, and its center is pulled downward by the corrugator. As a person ages, the forehead wrinkles do not fully disappear when the frontal bellies are relaxed.

When the eyebrows are raised, the root of the nose becomes thinner and the glabella becomes smooth. Raising the eyebrows also pulls the skin between the eyebrow and upper eyelid upward, exposing more of the eyelid. The skin below the eyebrow (the eye cover fold) then loses its form (its bulging quality) and becomes stretched over the bone beneath, revealing the form of the bony orbit. The distance between the medial end of the eyebrow and the inner corner of the eye increases; this is especially noticeable when only the medial portions are contracted.

When the eyebrows are raised, the ears also rise slightly.

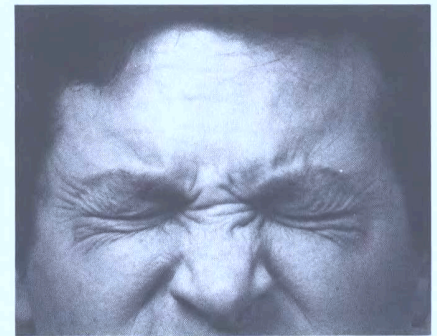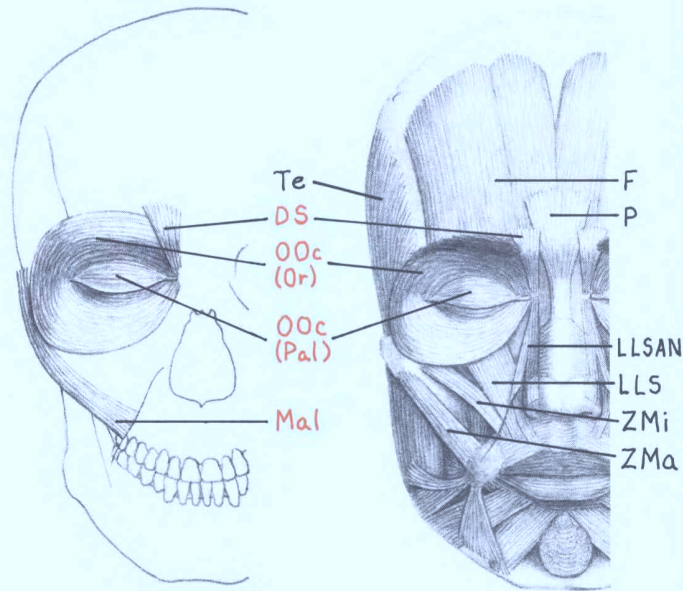
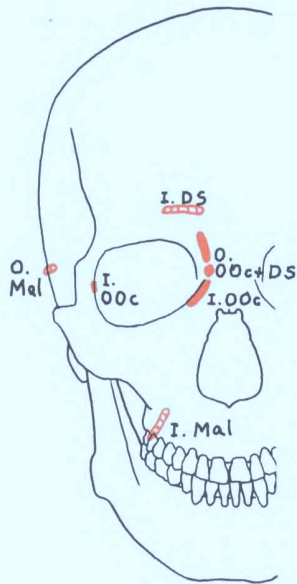
EXPRESSION *Medial and lateral portions of both sides of the face:* surprise, astonishment; fear, fright, horror; interest, attention; questioning, doubt. *Medial portions of both sides of the face (with corrugator):* sadness, grief, suffering; sometimes fear. *Medial and lateral portions of one side of the face:* inquisitiveness, skepticism. *Lateral portion of one side of the face:* sly, devious look.

Contraction of the entire frontalis is often used as a greeting signal or for conversational emphasis. This use is not an expression of emotion.




EYEBROWS

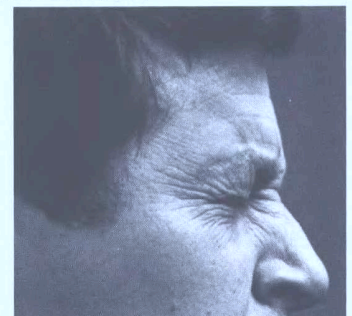
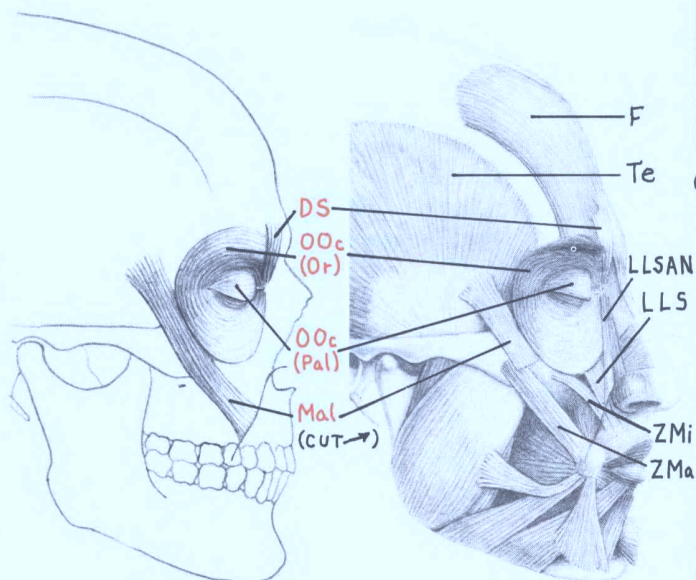
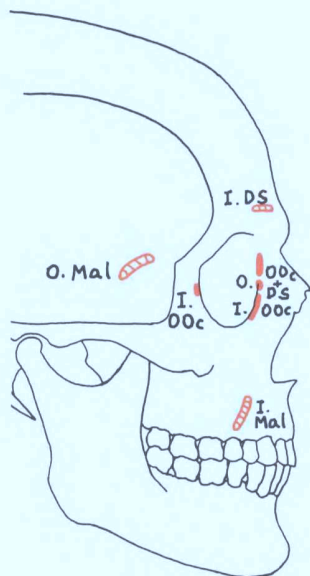
The Facial Muscles • ORBICULARIS OCULI



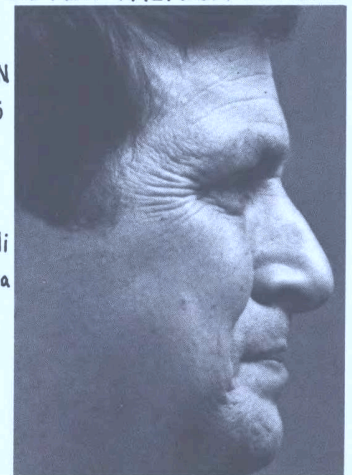
OUTER+PALPEBRAL PORTIONS



OUTER PORTION



OUTER+PALPEB. PORTIONS



OUTER PORTION

DS Depressor supercilii F Frontalis LLS Levator labii superioris
 LLSAN Levator labii superioris alaeque nasi Mal Malaris OOc Orbicularis oculi
 OOc(Or) Orbicularis oculi—orbital portion OOc(Pal) Orbicularis oculi—palpebral portion
 P Procerus Te Temporalis ZMa Zygomaticus major ZMi Zygomaticus minor

Corrugator Supercilii

ORIGIN The bone at the medial end of the superciliary arch, near the upper inner corner of the orbit.

INSERTION The skin of the middle portion of the eyebrow, and the skin of the forehead immediately above it. The fibers interlace with fibers of the frontalis and orbicularis oculi.

ACTION Pulls the middle section of the eyebrow downward and medially in an oblique direction, thereby pulling the brows together. It usually works simultaneously with the procerus and depressor supercilii to lower the eyebrows and pull them together. It can work without these muscles, pulling the eyebrows together, when the eyebrows are raised by the frontalis. Both sides usually work together, except when one eyebrow is pulled downward and the other upward.

STRUCTURE The corrugator supercilii is a narrow, elongated muscle. Most of the muscle is deep to the orbicularis oculi, but the lateral tips of its fibers pierce the orbicularis to pass superficially and insert into the skin.

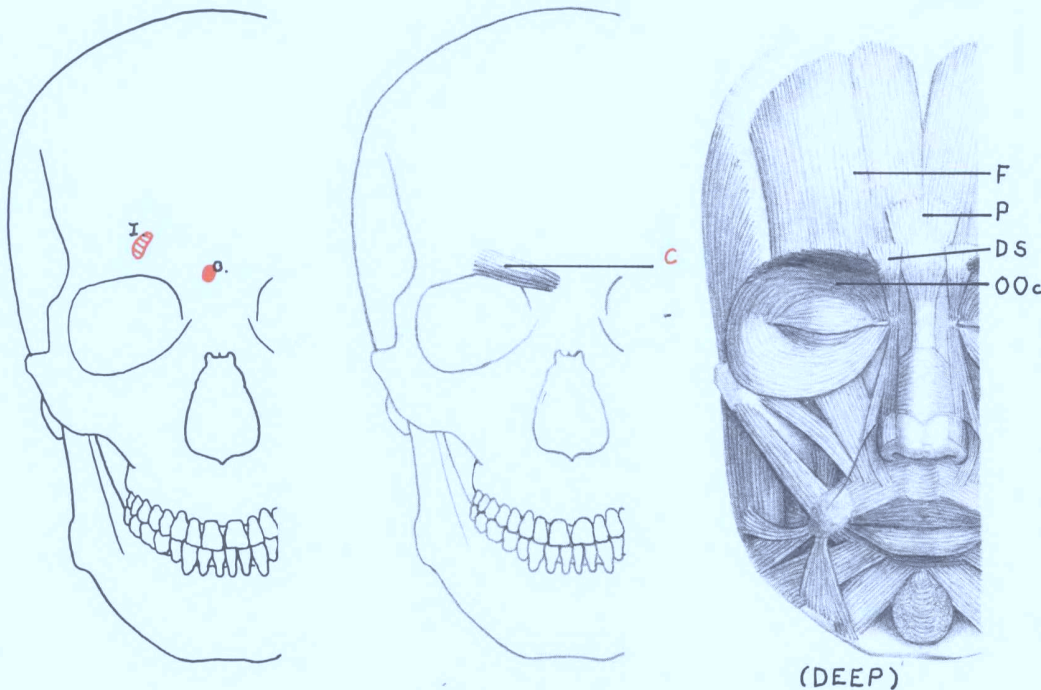
EFFECT The corrugator supercilii typically creates strong vertical or slightly oblique wrinkles and vertical bulges on the glabella between the medial ends of the eyebrows. It also swells the skin at the medial end of the eyebrow into a wide, thick, crescent-shaped bulge. This action

pulls the brows shelflike over the eyes, shading them from strong light.

A depression forms in the skin above the middle of the eyebrow (actually closer to the medial end) as the corrugator contracts. It often gives the eyebrow an S-shaped curve—the eyebrow develops a central downward dip (usually close to the medial end) as the muscle pulls the middle portion of the eyebrow downward and inward. This is especially noticeable if the medial portion of the frontalis is also lifting the medial end of the eyebrow. The corrugator may also create a long, oblique, shallow furrow on the lateral side of the front of the forehead. This furrow is directed upward and outward from the medial end of the eyebrow or from the skin depression located above the middle of the eyebrow.

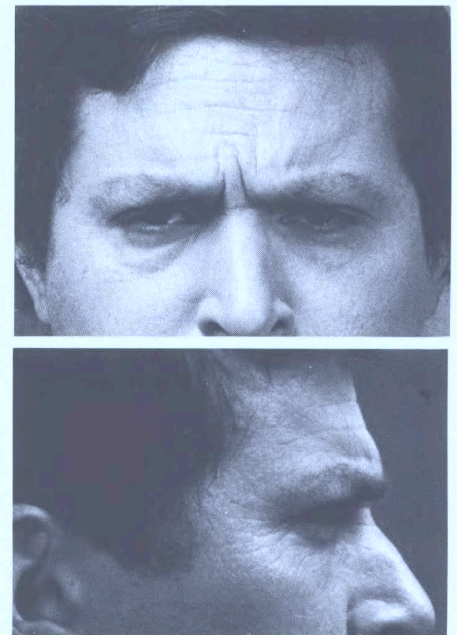
The lowering of the brow by the corrugator narrows the eye opening by pushing the skin below the eyebrow and upper eyelid downward.

EXPRESSION Anger; sadness, suffering, grief, pain; frowning; interest, thoughtful reflection, concentration (focused thought), curiosity, confusion. The corrugator can be considered a muscle of negative feelings, being typically used in sadness, fear, and anger. Concentration and determination, which also make strong use of the corrugator, may be regarded as unresolved stressful (negative) states.



(DEEP)

CS Corrugator supercilii DS Depressor supercilii F Frontalis OOc Orbicularis oculi P Procerus



The Facial Muscles • LEVATOR PALPEBRAE SUPERIORIS

Levator Palpebrae Superioris

ORIGIN Deep in the back of the eye socket, from the roof of the orbit.

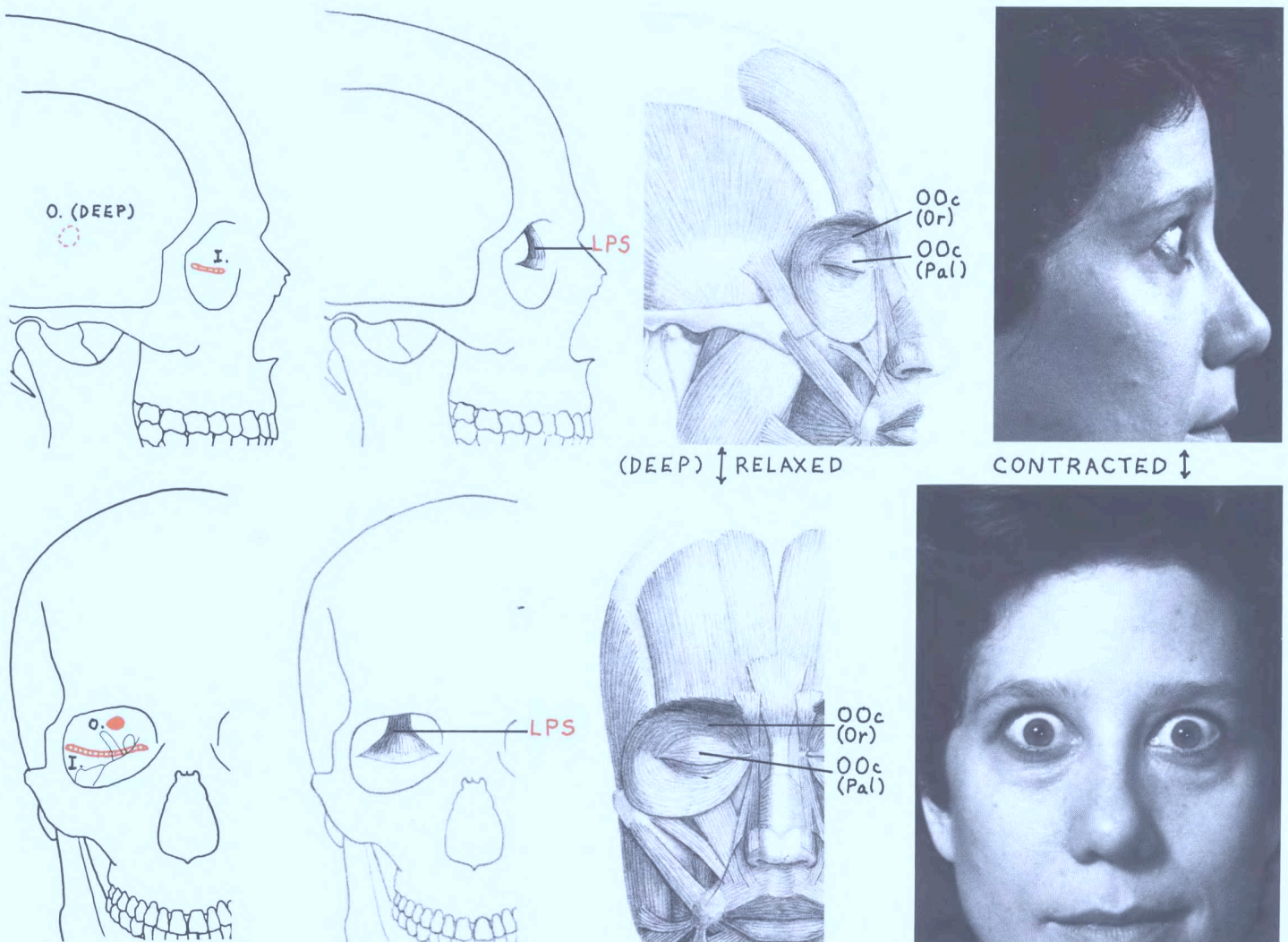
INSERTION The entire lower edge of the upper eyelid.

ACTION Raises the upper eyelid. It holds the eye open in the normal neutral position. Expression develops only after the eyelid has been raised above this position.

STRUCTURE The levator palpebrae superioris is a long muscle which passes over the eyeball, deep in the eye socket, along the roof of the orbit. Narrow behind, it widens as it advances anteriorly, becoming aponeurotic before inserting into the margin of the upper eyelid.

EFFECT Exposes the upper portion of the iris and the white of the eye (sclera) above the iris. By continued action it pulls the upper eyelid back so it disappears from view under the eye cover fold.

EXPRESSION Slight raising of the upper eyelid beyond the normal open eye produces a staring, fixed gaze or the expression of surprise. Full contraction produces intense expressions ranging from fear, terror, shock, astonishment, and intense joy to a blank, hypnotic look. Slight relaxation of the muscle (causing the upper eyelid to droop) with the eye still remaining partially open suggests drowsiness or intoxication, especially if the frontalis is also contracted in an attempt to hold the eyes open by raising the eyebrows. This expression exposes more of the upper eyelid, which has descended onto the upper portion of the iris. Upper eyelid droop and gentle eye closure (when the lower eyelid does not rise) are caused by relaxation of the levator palpebrae superioris, not by contraction of the orbicularis oculi.



DS Depressor supercilii F Frontalis LPS Levator palpebrae superioris

The Facial Muscles • PROCERUS

Procerus (Pyramidalis Nasi)

ORIGIN The fascia covering the lower part of the nasal bones and the upper part of the lateral nasal cartilages.

INSERTION The skin between the eyebrows and on the lower portion of the center of the forehead. Its fibers blend with fibers of the frontalis in the same region.


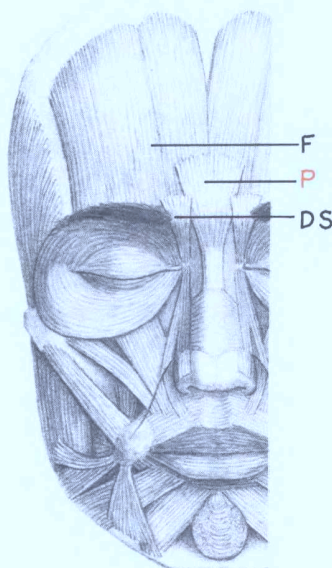
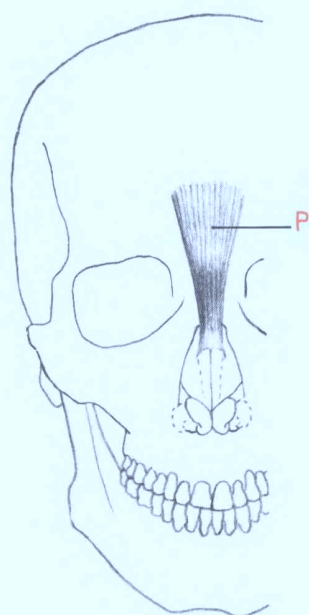
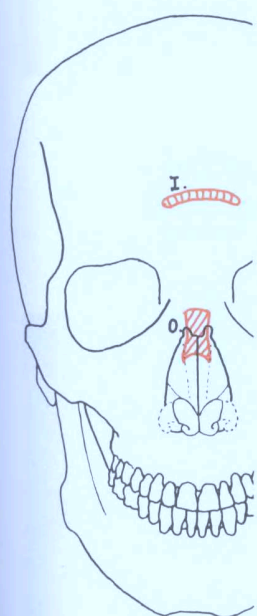
ACTION Pulls down the skin of the middle of the forehead and the medial ends of the eyebrows. This muscle works in conjunction with the corrugator supercilii and depressor supercilii to lower the medial ends of the eyebrows. The

procerus automatically contracts when the levator labii superioris alaeque nasi is tensed. It can be seen working by itself if the eyebrows are first raised by the frontalis and then the levator labii superioris alaeque nasi is contracted.


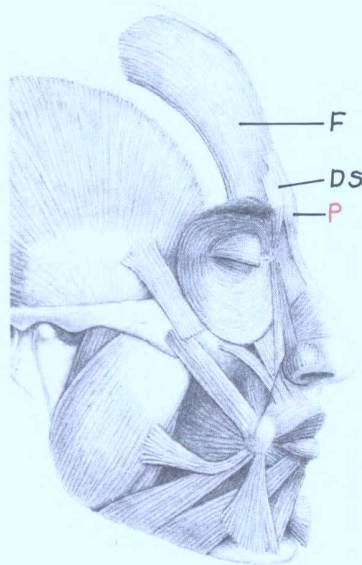
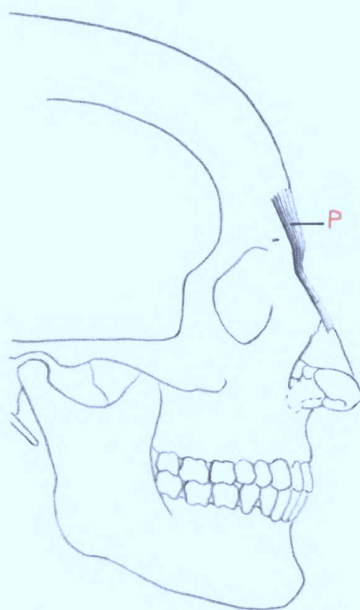
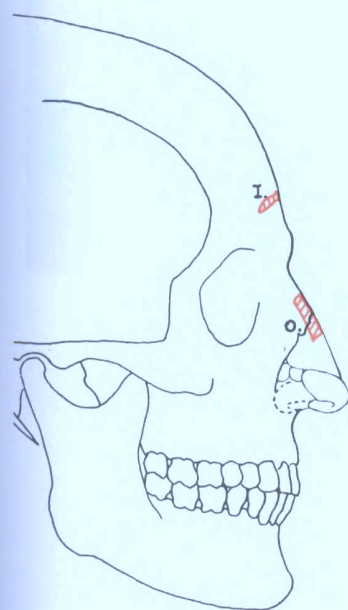
STRUCTURE The procerus muscles of both sides form a single triangular sheet of muscle between the eyebrows.

EFFECT The procerus may occasionally produce a horizontal wrinkle across the bridge of the nose.

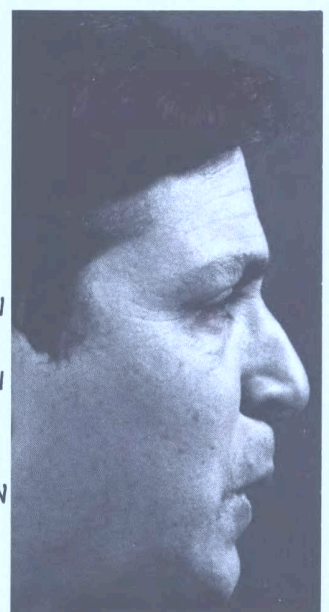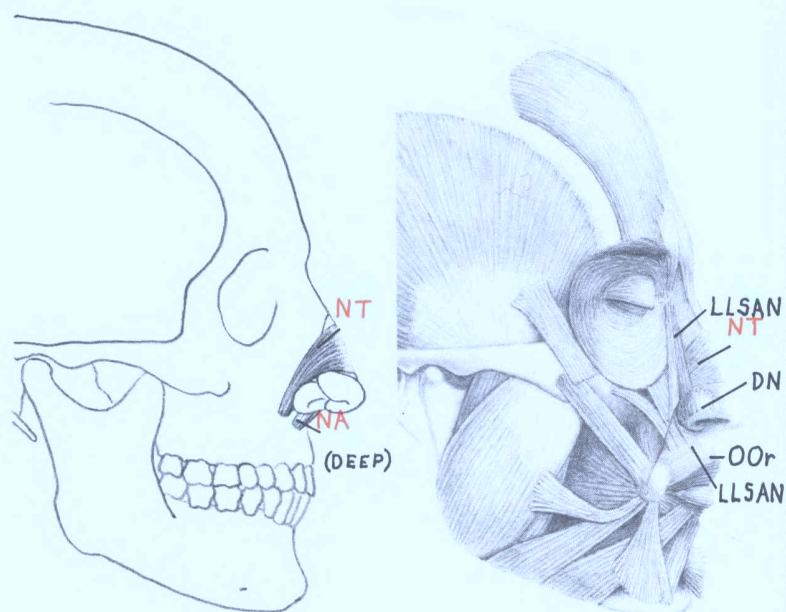
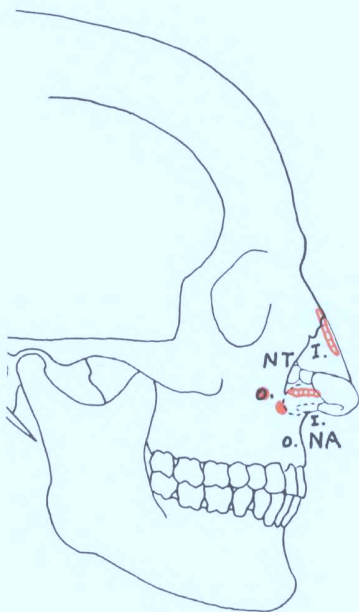
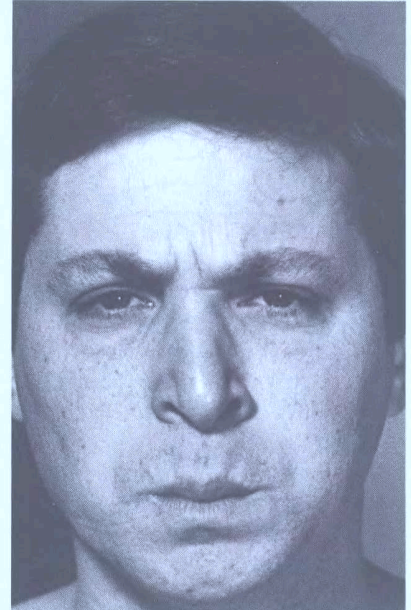
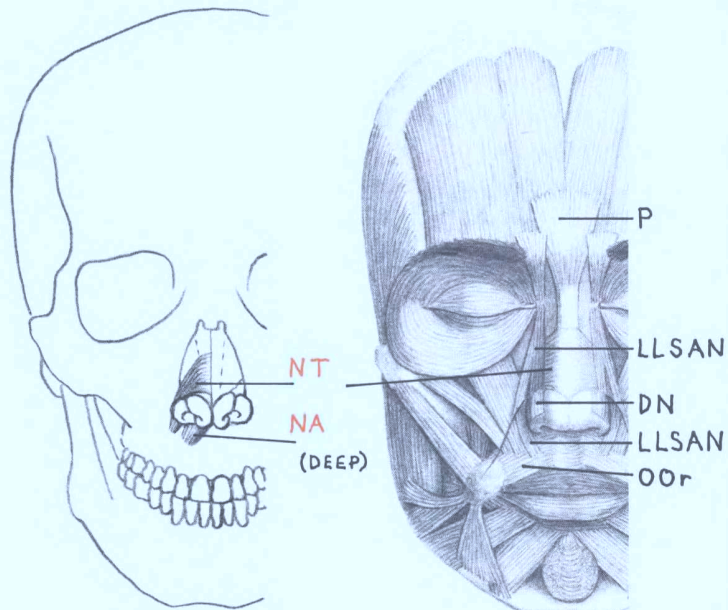
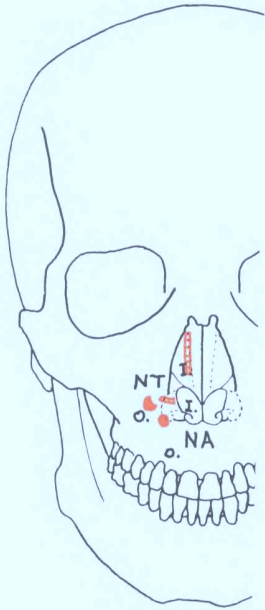
EXPRESSION Anger, aggression, pain; frown, concentration; contributes to disgust.



PROCERUS + CORRUGATOR ↑↓



OOc(Or) Orbicularis oculi—orbital portion OOc(Pal) Orbicularis oculi—palpebral portion P Procerus



DN Dilator naris LLSAN Levator labii superioris alaeque nasi NA Nasalis—alar part
NT Nasalis—transverse part OOr Orbicularis oris P Procerus

The Facial Muscles • DILATOR NARIS

Dilator Naris (Alaris)

ORIGIN Edge of the nasal notch of the maxilla (bony origin) and the lesser alar cartilages and lower edge of the lateral crus of the greater alar cartilage (cartilaginous origins).

INSERTION The skin at the inferior margin of the wing of the nose.

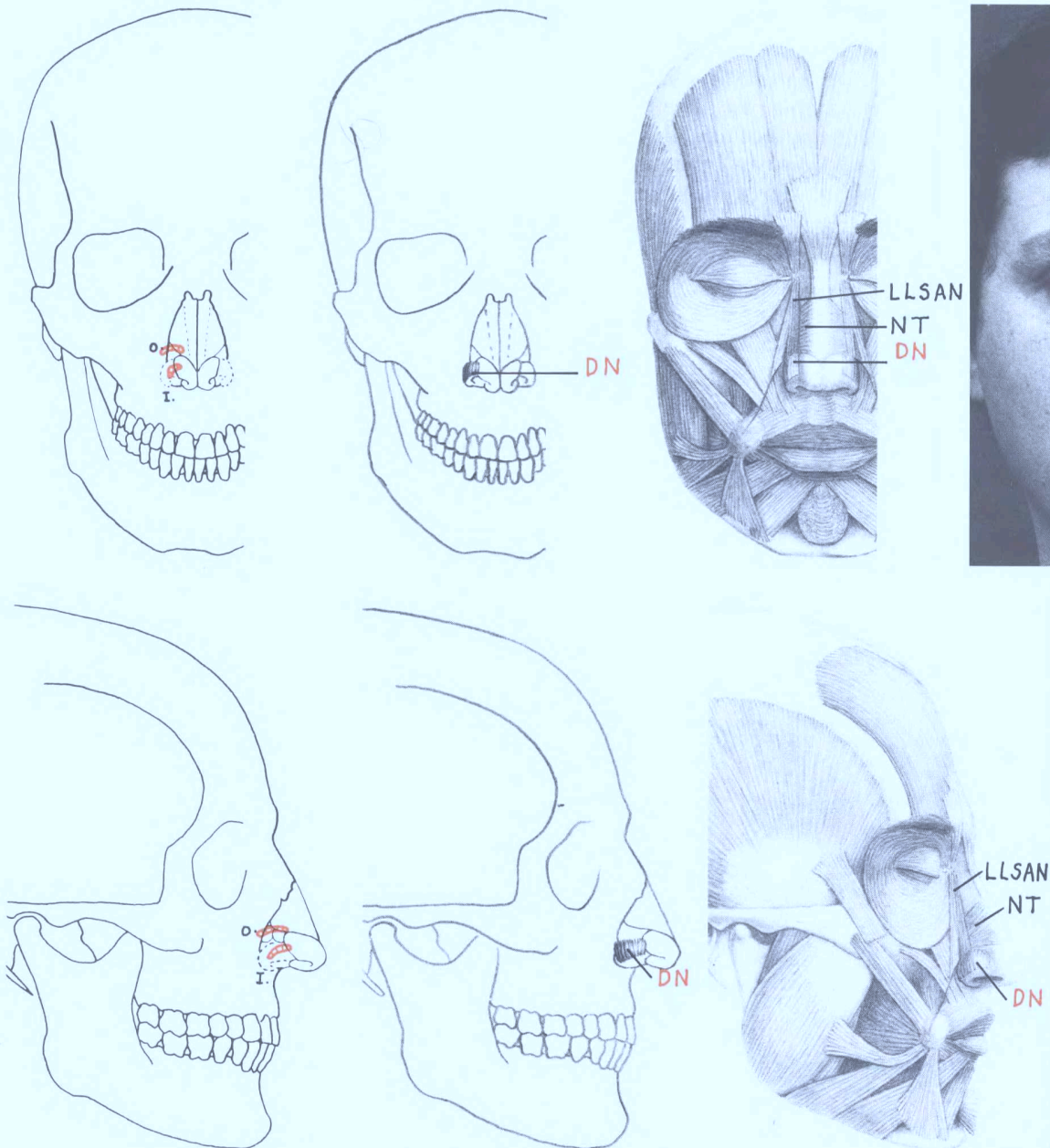
ACTION Dilates (flares) the wing of the nose. Both sides work simultaneously.

STRUCTURE The dilator naris is a very thin

rectangular muscle that lies on the outer surface of the wing of the nose.

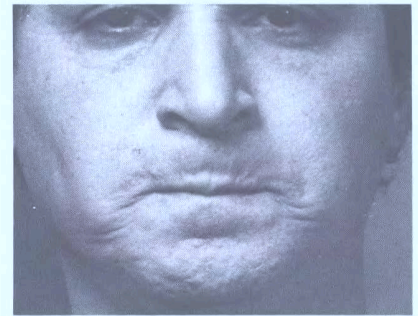
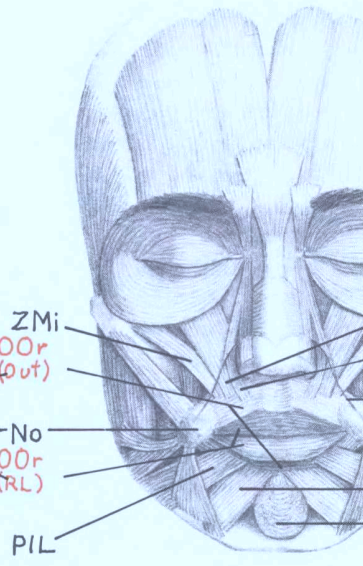
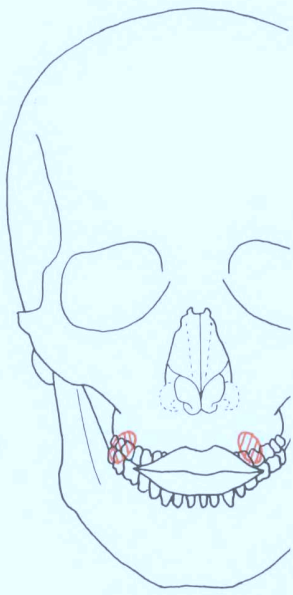
EFFECT Enlarges the opening of the nostril. The upper edges of the wings of the nose become depressed (pulled medially), and the furrow at the upper edge of the wing becomes more pronounced. In side view, the middle of the lower edge of the wing is raised, exposing more of the nostril.

EXPRESSION Passion; anger, rage; labored breathing, exertion.




DN Dilator naris LLSAN Levator labii superioris alaeque nasi NT Nasalis—transverse part

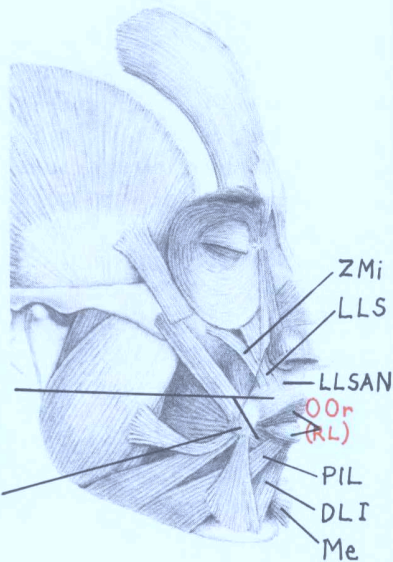
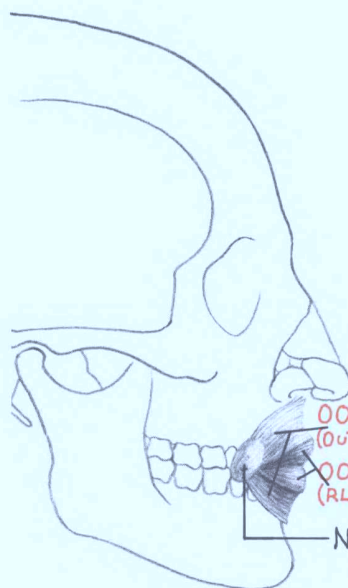
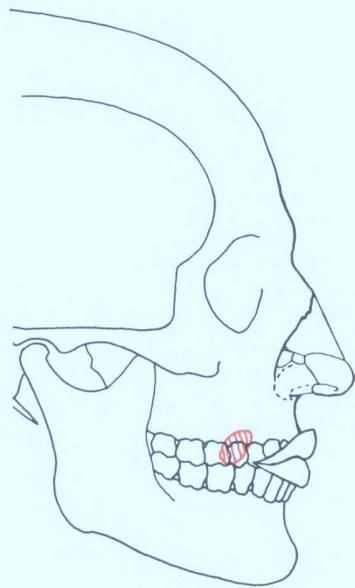
The Facial Muscles • ORBICULARIS ORIS



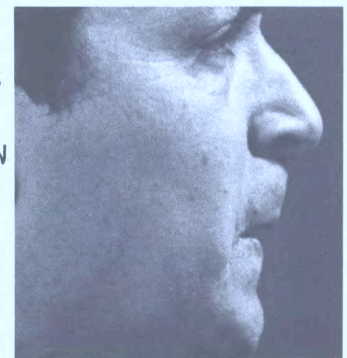
OUTER PORTION



RED LIP PORTION



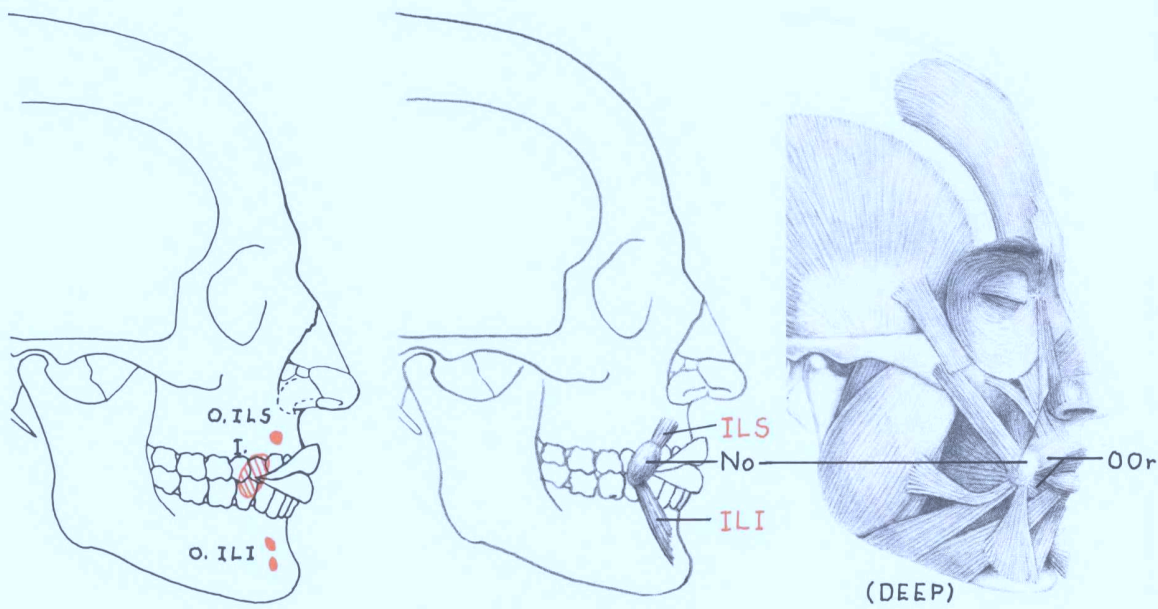
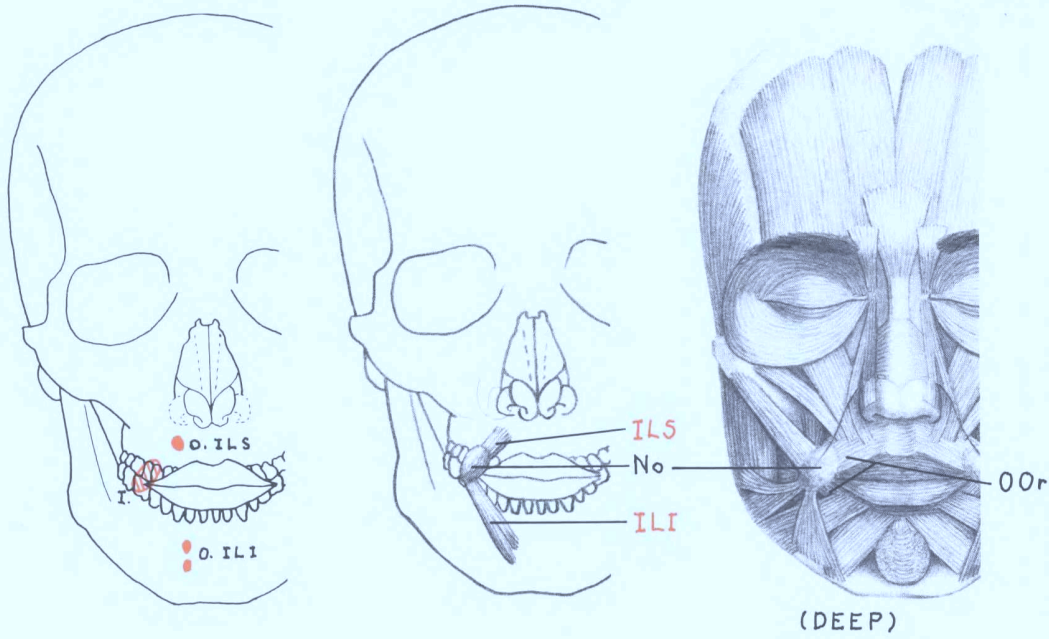
OUTER PORTION



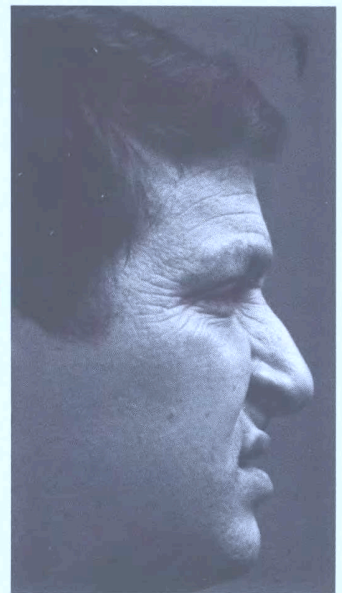
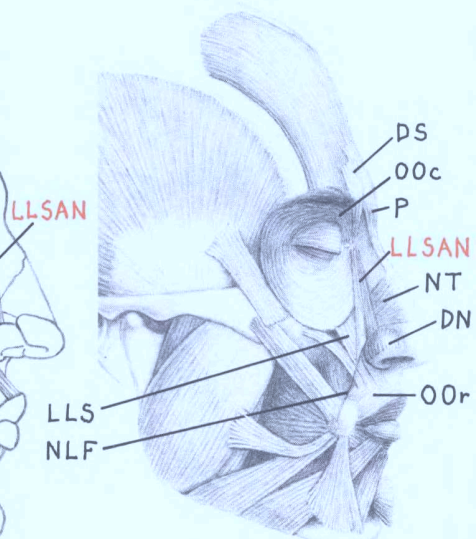
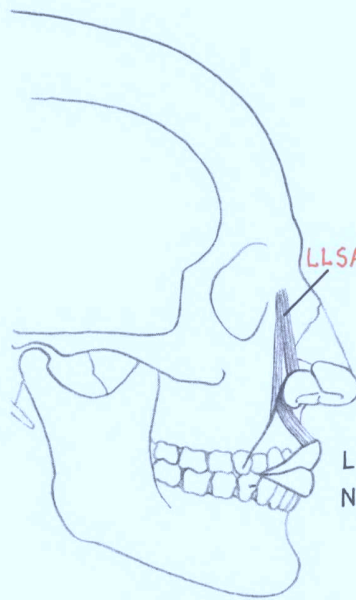
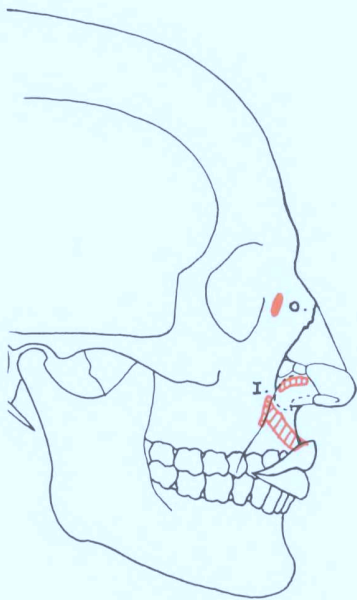
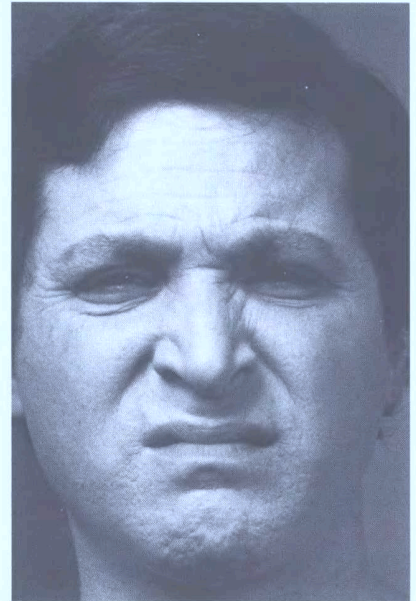
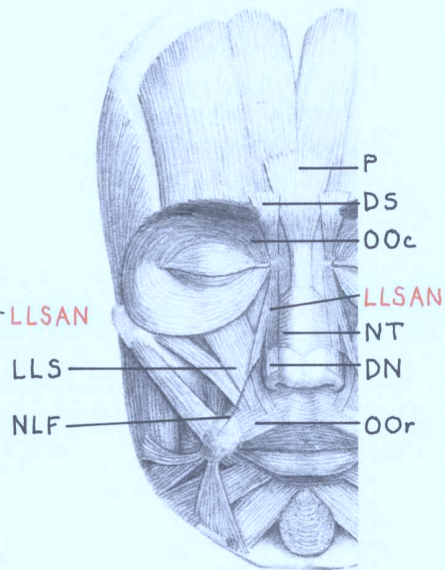
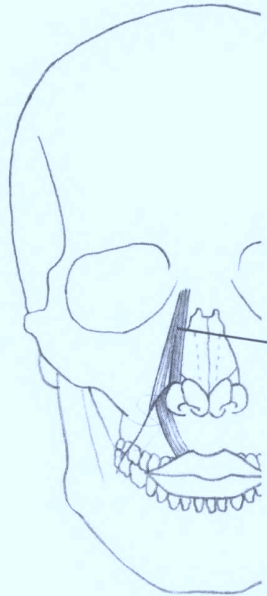
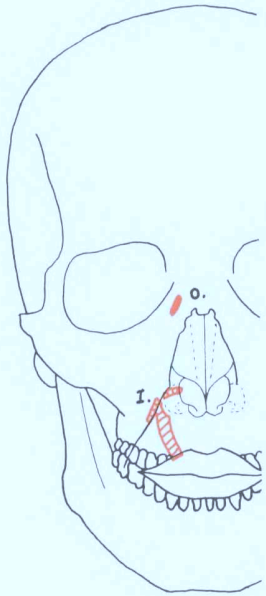
RED LIP PORTION

DLI *Depressor labii inferioris* LLS *Levator labii superioris* LLSAN *Levator labii superioris alaeque nasi*
 Me *Mentalis* NLF *Nasolabial furrow* No *Node* OOr(Out) *Orbicularis oris—outer portion*
 OOr(RL) *Orbicularis oris—red lip portion* PIL *Platysma—labial portion* ZMi *Zygomaticus minor*

The Facial Muscles • INCISIVUS LABII SUPERIORIS AND INFERIORIS

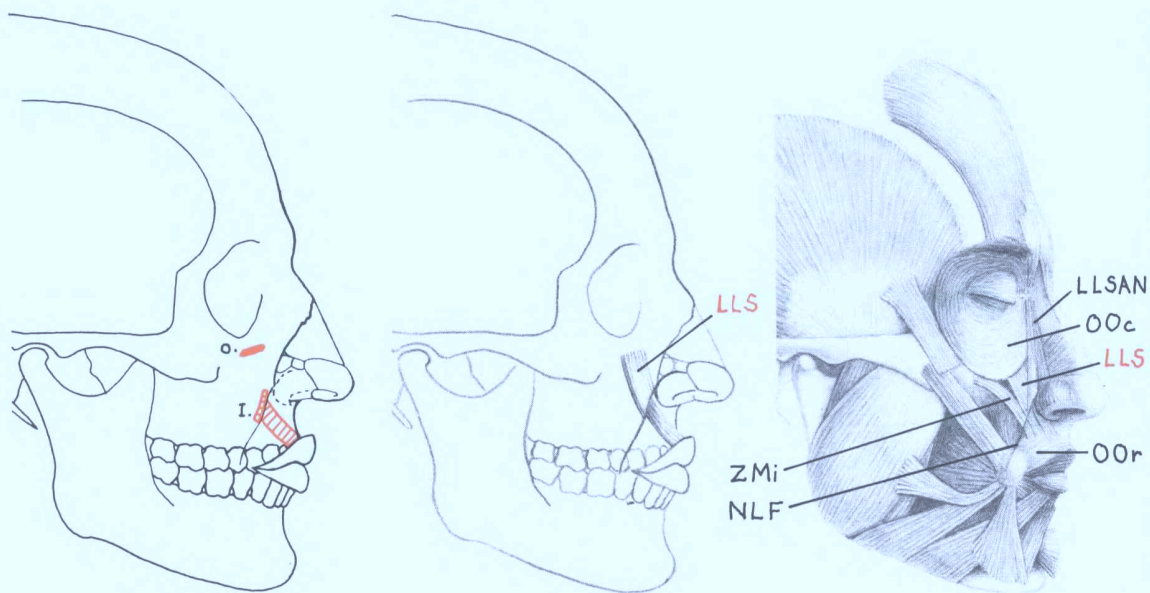
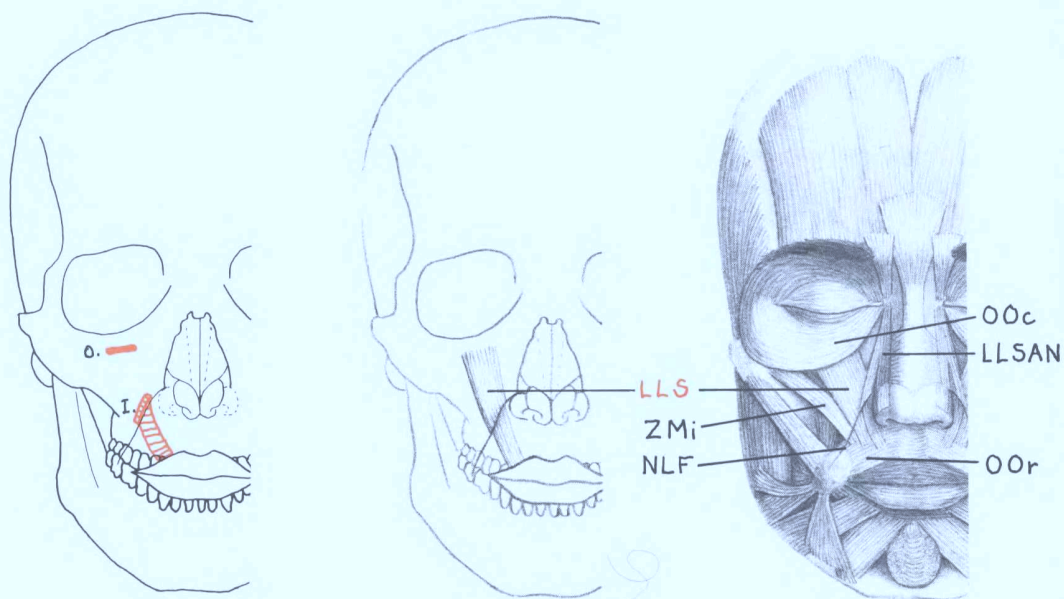


ILI Incisivus labii inferioris ILS Incisivus labii superioris No Node OOr Orbicularis oris



DN Dilator naris DS Depressor supercilii LLS Levator labii superioris
 LLSAN Levator labii superioris alaeque nasi NLF Nasolabial furrow NT Nasalis—transverse part
 OOc Orbicularis oculi OOr Orbicularis oris P Procerus

The Facial Muscles • LEVATOR LABII SUPERIORIS



LLS Levator labii superioris LLSAN Levator labii superioris alaeque nasi NLF Nasolabial furrow
 OOc Orbicularis oculi OOr Orbicularis oris ZMi Zygomaticus minor

The Facial Muscles • ZYGOMATICUS MINOR

Zygomaticus Minor (Quadratus Labii Superioris— Zygomatic Head)

ORIGIN The front surface of the zygomatic bone, below the lateral edge of the orbit (below the outer corner of the eye).

INSERTION The skin of the middle section of the nasolabial furrow and into the cheek fat. Other fibers continue further downward to the red lip, passing over as well as through the mass of the orbicularis oris (see insertion of levator labii superioris).


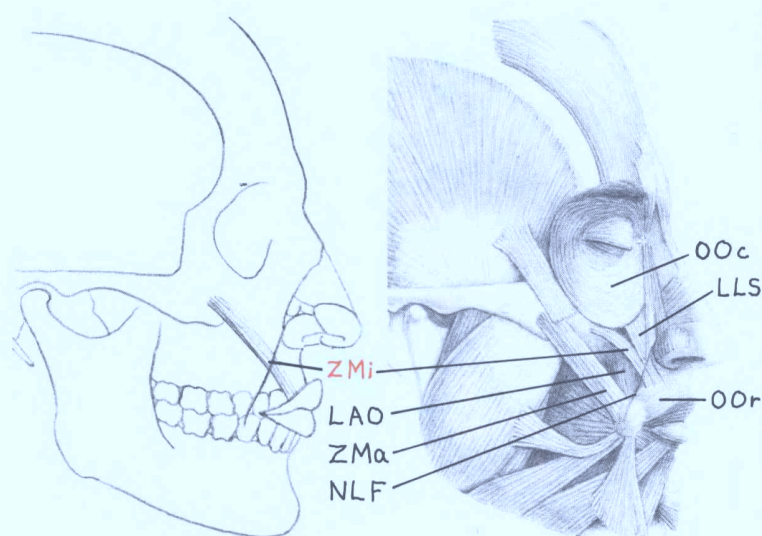
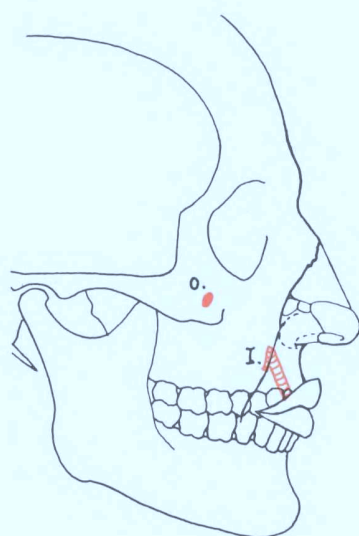

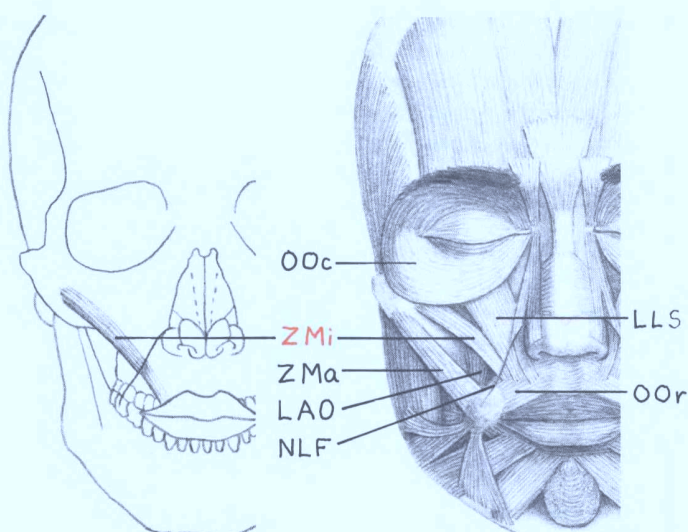
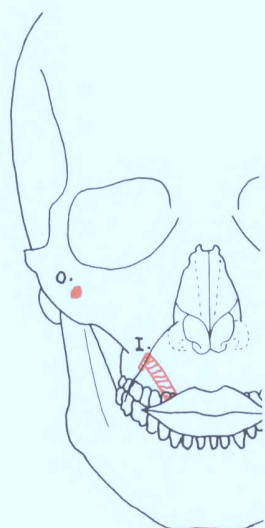
ACTION Pulls the middle section of the nasolabial furrow and the middle portion of one side of the upper lip outward and slightly upward. This is a subtle, oblique pull, whereas the

pull of the levator labii superioris is straight up. The zygomaticus minor does not pull the angle of the mouth.

STRUCTURE From its origin, this small muscle passes medially and then curves downward. It lies deep to the orbicularis oculi at its origin.

EFFECT The zygomaticus minor deepens the portion of the middle section of the nasolabial furrow located midway between the level of the bottom of the nose and the top of the upper lip.

EXPRESSION Sadness. It pulls the upper lip into the crying position. The zygomaticus minor does not express disgust or happiness, although its action may look similar to disgust.



LAO Levator anguli oris LLS Levator labii superioris NLF Nasolabial furrow No Node

The Facial Muscles • LEVATOR ANGULI ORIS

Levator Anguli Oris (Caninus)

ORIGIN The canine fossa of the maxilla, below the middle of the lower edge of the orbit.

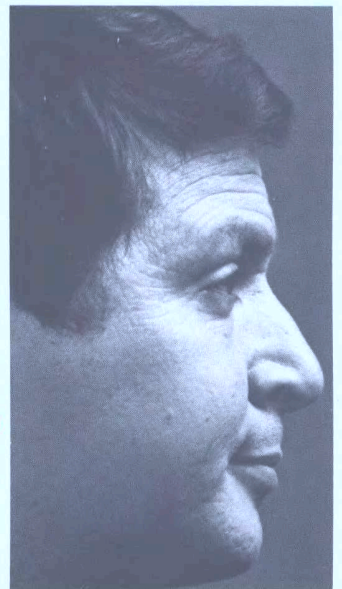
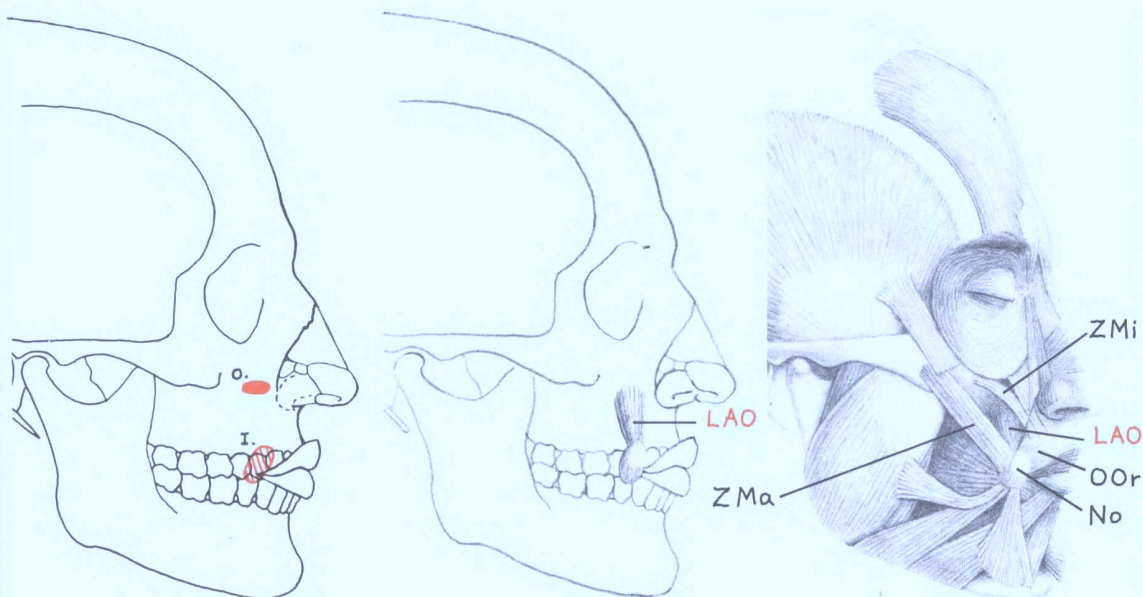
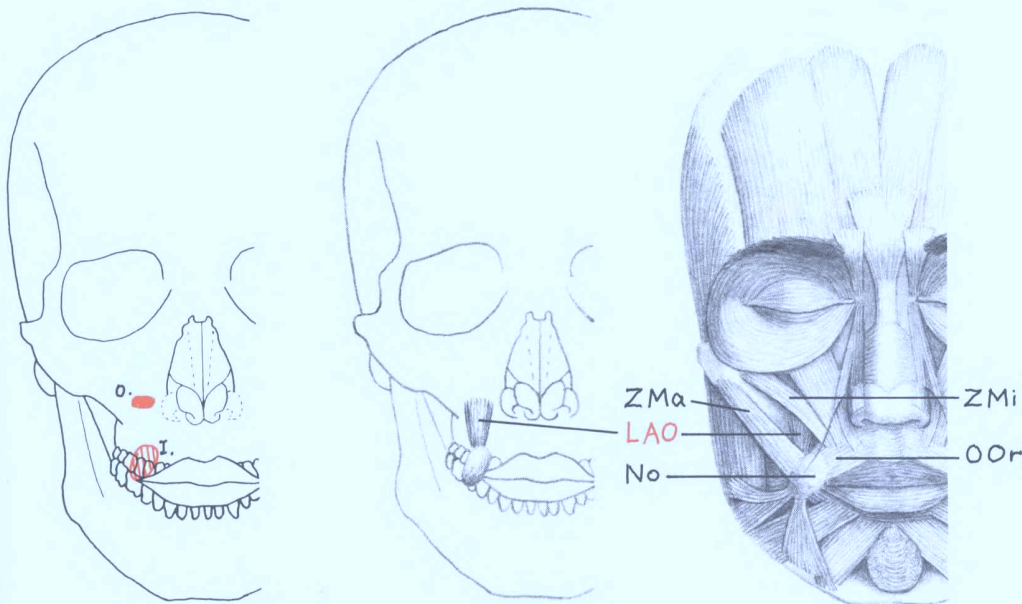
INSERTION The muscular node at the angle of the mouth.

ACTION Pulls the node, and therefore the angle of the mouth (not the upper lip), straight up. This is a difficult action to do voluntarily.

STRUCTURE This somewhat fan-shaped muscle converges inferiorly into the node. It lies deep to other facial muscles.

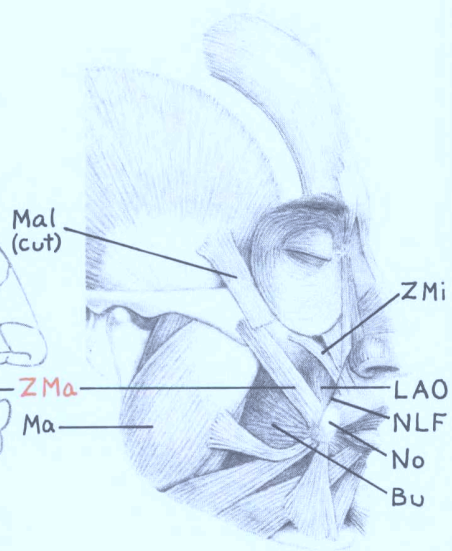
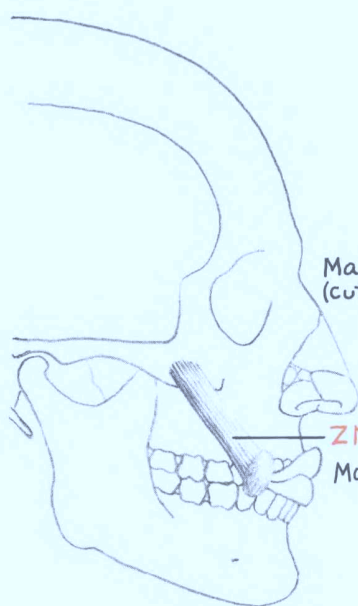
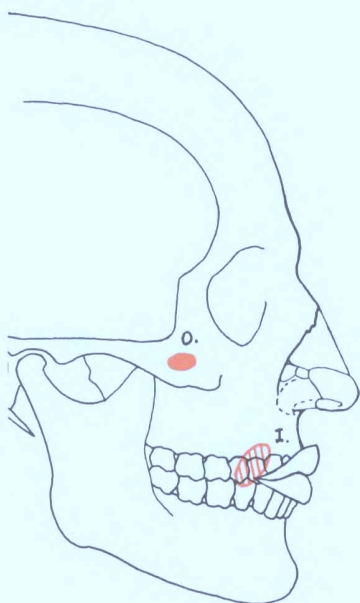

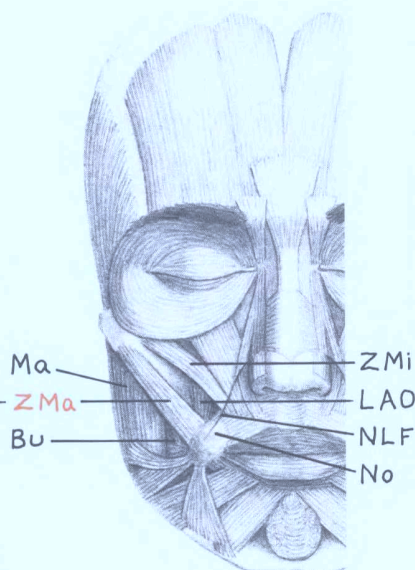
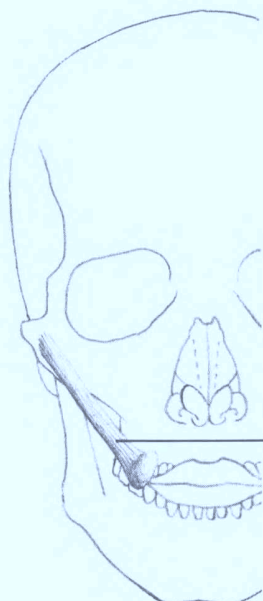
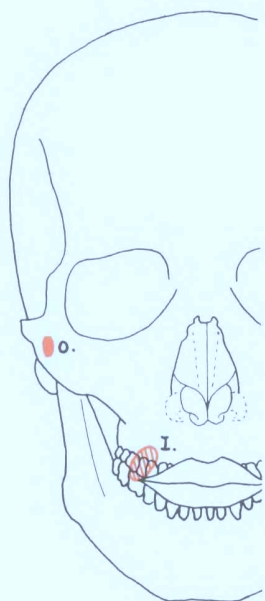
EFFECT Pulling the angles of the mouth straight up, the levator anguli oris curves the mouth line upward at its ends. This is a rounder, tighter curvature than that caused by the zygomaticus major during a normal, true smile. The levator anguli oris also stretches the lips. The front of the cheek is lifted and puffed out. The nasolabial furrow rises and moves laterally.

EXPRESSION Uncomfortable, uncertain, or "stupid" smile. This muscle is probably not used in expressing the basic emotions; it may be used primarily to stabilize the node.



OOc Orbicularis oculi OOr Orbicularis oris ZMa Zygomaticus major ZMi Zygomaticus minor

The Facial Muscles • ZYGOMATICUS MAJOR



Bu Buccinator LAO Levator anguli oris Ma Masseter Mal Malaris NLF Nasolabial furrow
No Node ZMa Zygomaticus major ZMi Zygomaticus minor

The Facial Muscles • RISORIOUS

Risorius

ORIGIN The fascia of the cheek overlying the masseter muscle (a nonbony origin).

INSERTION The muscular node at the angle of the mouth and sometimes into the posterior edge of the upper end of the depressor anguli oris.

ACTION Pulls the node, and therefore the angle of the mouth, backward and outward—*horizontally*—toward the ear lobe. This very weak action is probably used for creating subtle movements of the mouth during speech.

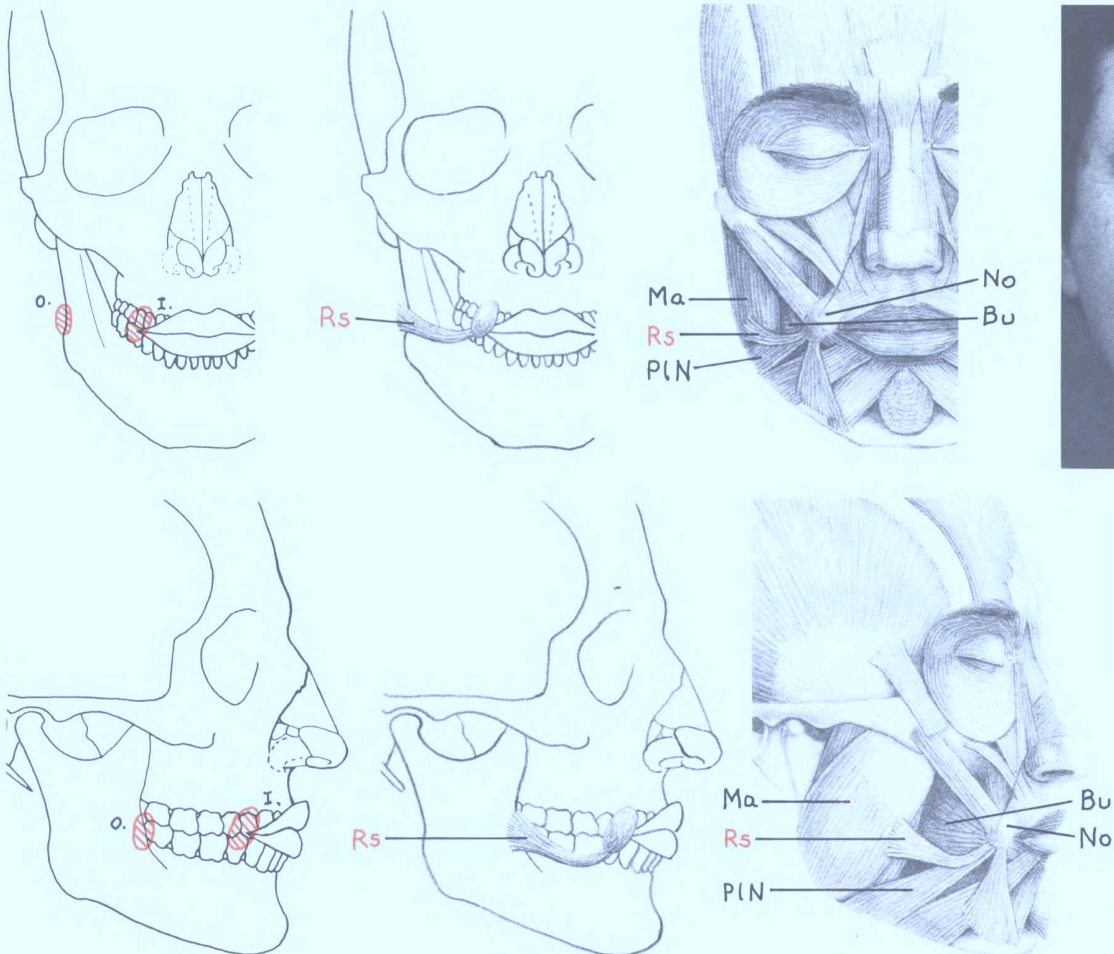
Strong retraction of the angle of the mouth is produced by the nodular portion of the platysma, which also pulls it slightly downward.

STRUCTURE The risorius is one of the most variable of the facial muscles. A good percent-

age of people have no risorius at all, while others have an expansive one. In some individuals, the muscle is present on one side of the face only. The nodular platysma, however, is present in all people. Structurally, the risorius ranges from a triangular muscular sheet that converges into the node to a narrow band that may contain only a few strands of muscular fiber.

EFFECT The risorius widens the mouth, stretching and flattening the lips. It pulls the lower end of the nasolabial furrow outward and backward.

EXPRESSION When present, the risorius may contribute to facial expressions that involve retraction of the angle of the mouth, especially smiling (happiness), along with the more powerful zygomaticus major.



Bu Buccinator Ma Masseter No Node PIN Platysma—nodular portion Rs Risorius

The Facial Muscles • BUCCINATOR

Buccinator

ORIGIN The outer surfaces of the upper and lower jaws, just above and below the three back molars respectively, and from a tendinous band that spans across the posterior end of these bony origins.

INSERTION Into the muscular node at the angle of the mouth.

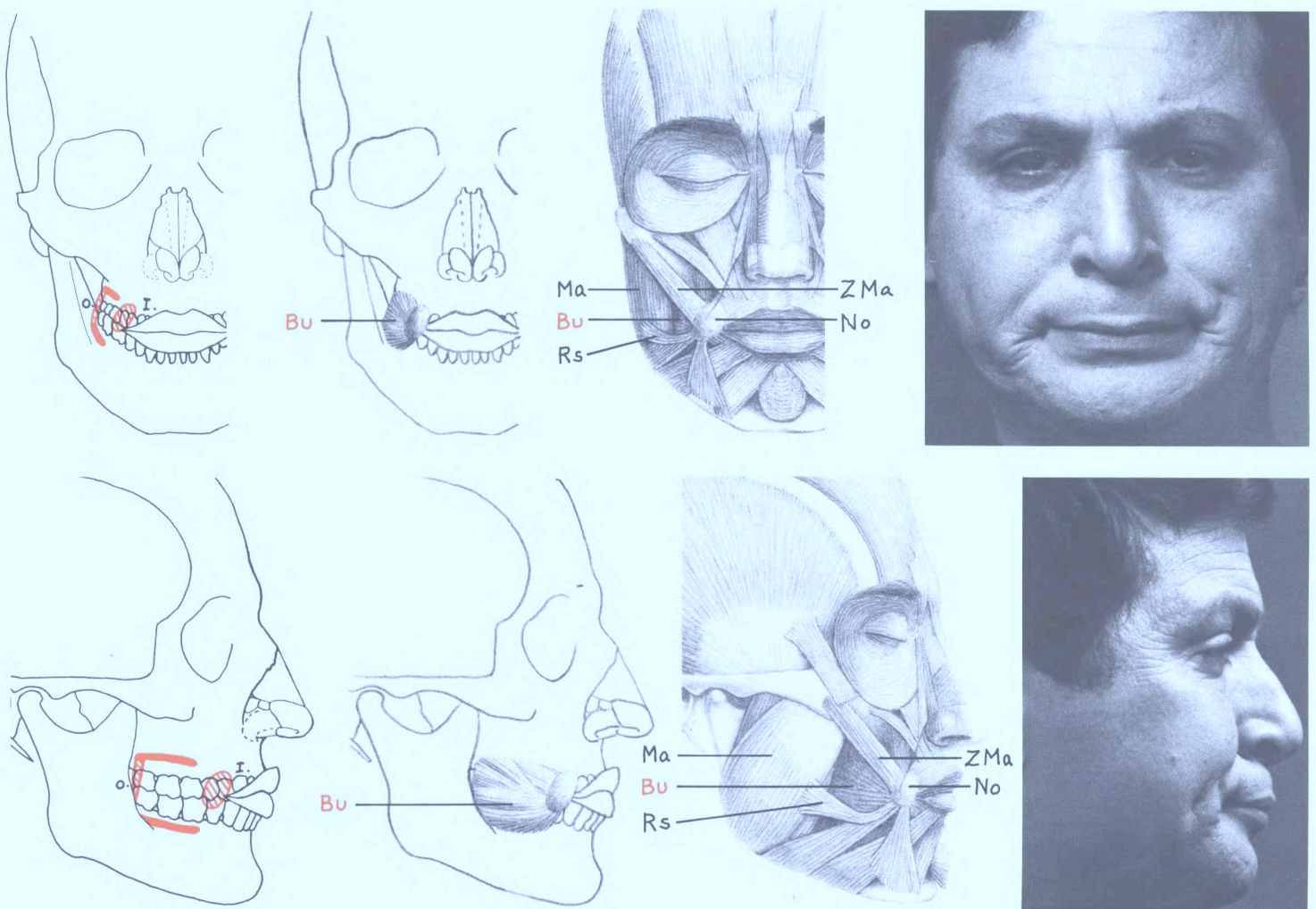
ACTION The buccinator pulls the *medial* edge of the node and the angle of the mouth (the extreme lateral end of the mouth line) *straight back* (posteriorly, not laterally), and usually slightly upward. It compresses the cheeks to force out air after they have been distended (or prevents them from being distended) and keeps food between the teeth while chewing.

STRUCTURE This relatively deep, quadrilateral muscle forms the lateral wall of the cheek, lying on the outside of the teeth. The thick buc-

cal (cheek) fat pad lies on the muscle's outer surface.

EFFECT The angle of the mouth is pulled inward or puckered inward and is usually also pulled slightly upward, curving the mouth line slightly upward at its ends. Lines may radiate from the angle of the mouth, especially one that passes outward and downward. The lips are widened and elongated as they are pulled around the cylinder of the muzzle, and the fleshy prominence of the chin is widened and flattened slightly. The lower end of the nasolabial furrow may deepen, while the cheek tissue just lateral to the dimpled angle of the mouth develops several bulged forms.

EXPRESSION Sarcastic smirk, annoyance, contempt, disapproval. These emotions are expressed by either unilateral or bilateral contraction of the buccinator.



ZMa Zygomaticus major

Depressor Anguli Oris
(Triangularis; Triangularis Menti)

ORIGIN *Deep head (long head):* A line on the outside of the body of the mandible, extending forward to the mental tubercle. This line is variable in length—often the long head arises only from the mental tubercle at the corner of the chin. *Superficial head (caput latum):* The fascia covering the platysma and depressor labii inferioris.

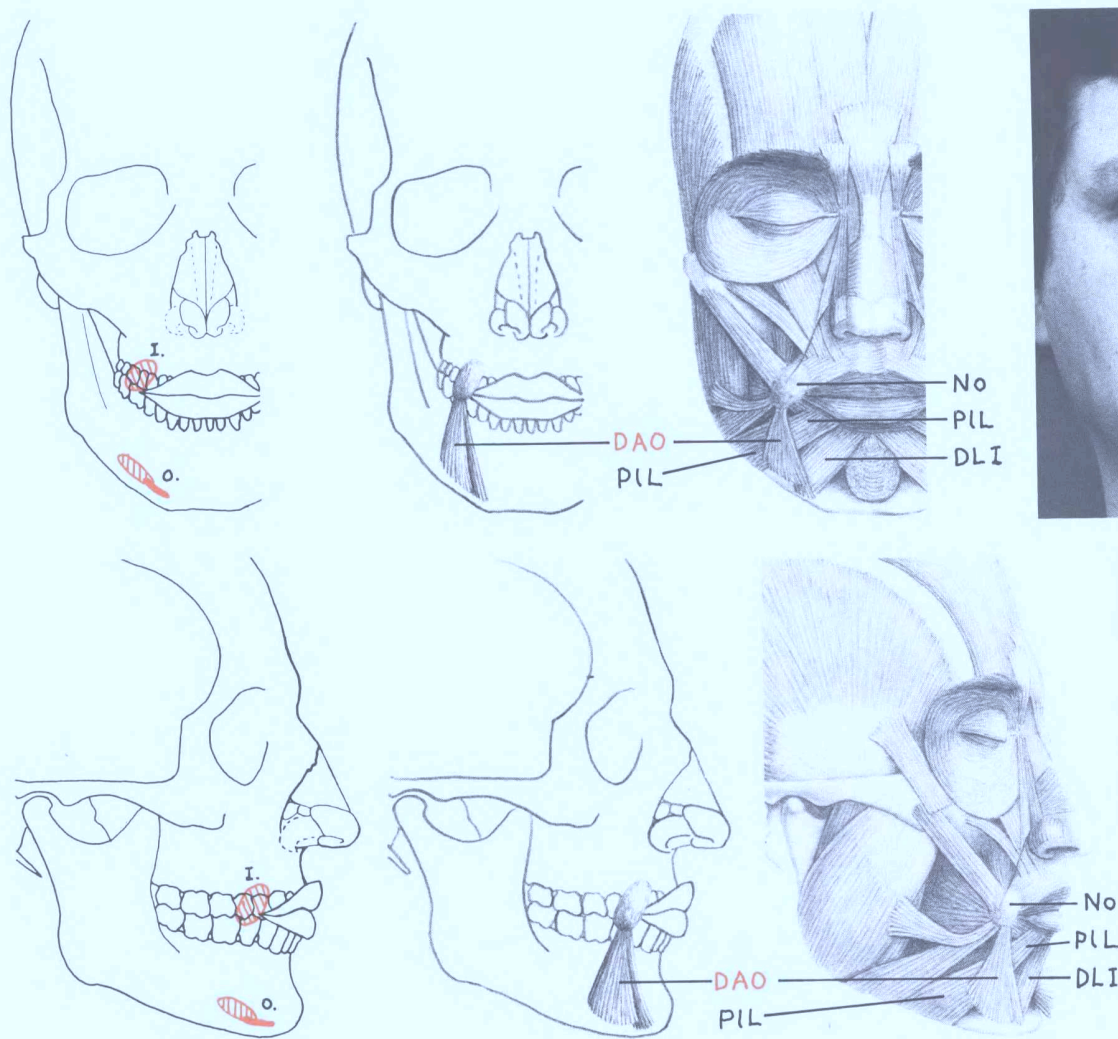
INSERTION The muscular node at the angle of the mouth.

ACTION Pulls the node (and angle of the mouth) only slightly downward and laterally from its normal resting position. This muscle is the antagonist of the zygomaticus major, and the long head may be seen on the surface as a raised ridge during strong smiling action as the zygomaticus pulls the node upward and outward.

STRUCTURE The depressor anguli oris is made up of two layers: a superficial head arising from fascia, and a deep head arising from bone. The deep head is often narrow and strap-like, arising from the small bony area of the mental tubercle. Together, both heads create a fan-shaped muscle that converges into the node.

EFFECT The depressor anguli oris curves the mouth downward at its outer corners, which also lengthens the nasolabial furrow while deepening its lower end (producing the “long face” of sadness). It widens the mouth slightly and stretches the lips, flattening them. Strong contraction will produce several bulging forms below and lateral to the angle of the mouth. The furrow descending obliquely from the angle of the mouth is deepened and prolonged.

EXPRESSION Sadness, grief, sorrow, depression; disgust.



DAO Depressor anguli oris DLI Depressor labii inferioris Me Mentalis No Node

Depressor Labii Inferioris
(Quadratus Labii Inferioris; Quadratus Menti)

ORIGIN An oblique line on the outside of the body of the mandible, just superior to the origin of the depressor anguli oris.

INSERTION The skin of the medial portion of each half of the lower lip, almost up to the red part, and into the substance of the orbicularis oris. The fibers of these muscles of each side of the face blend at the midline just below the lower lip.

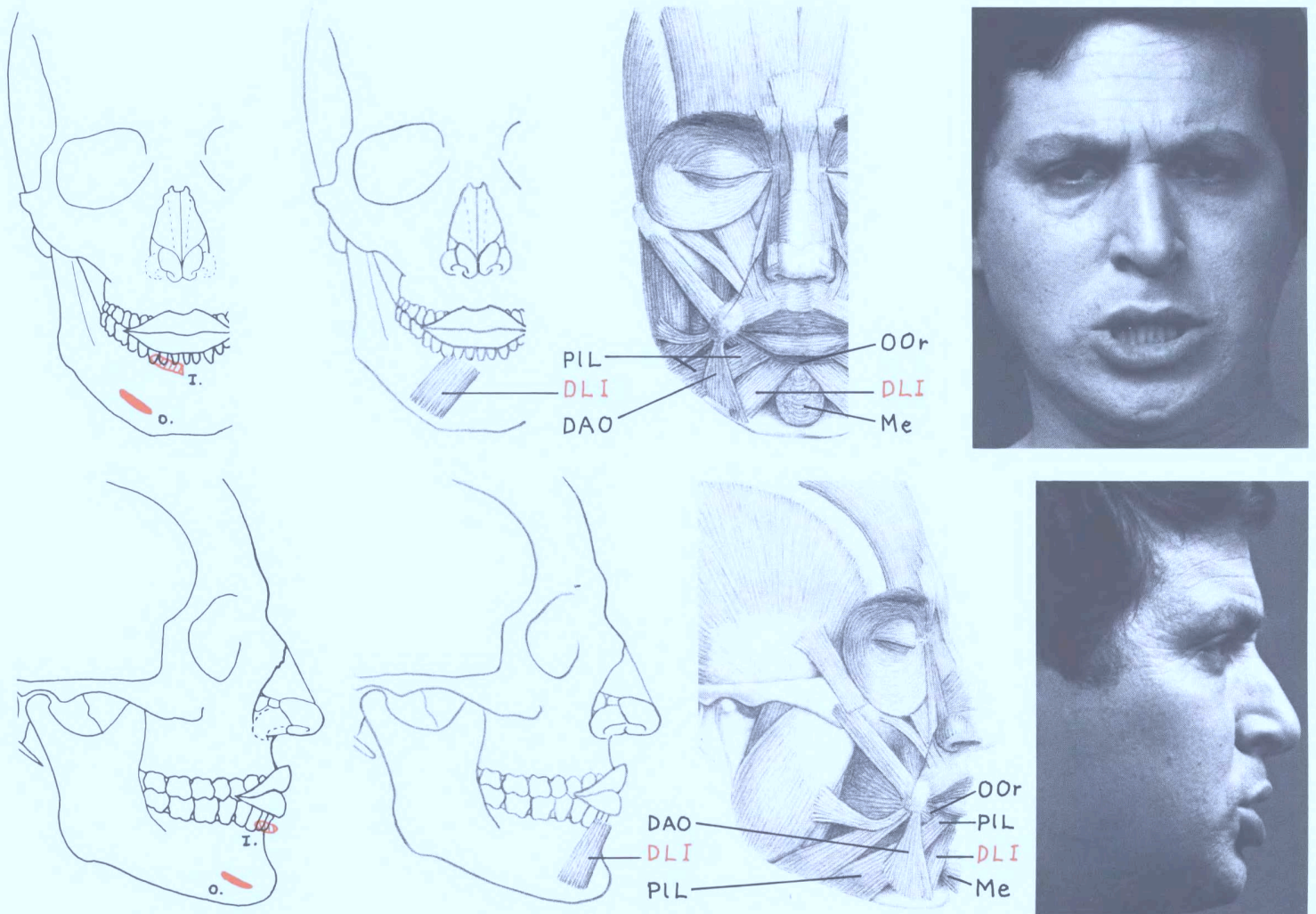
ACTION The muscles of both sides contract together to pull the middle third of the entire lower lip straight downward. This parts the lips, exposing the teeth and lower gum (also see

action of labial platysma). The depressor labii inferioris assists in eversion of the lower lip, exposing the inside wet mucous membrane. Its medial fibers push the chin prominence downward.

STRUCTURE The depressor labii inferioris is a quadrilateral muscle. Its lower lateral portion lies deep to fibers of the depressor anguli oris and the labial platysma.


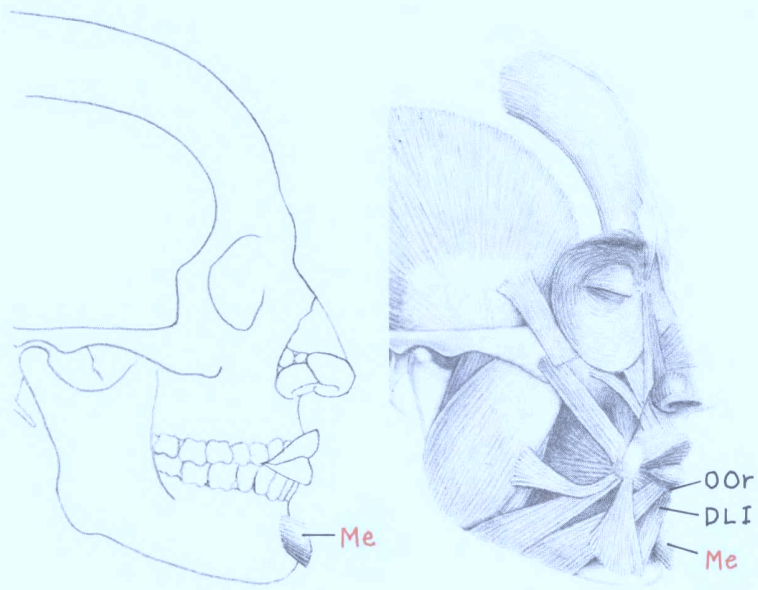
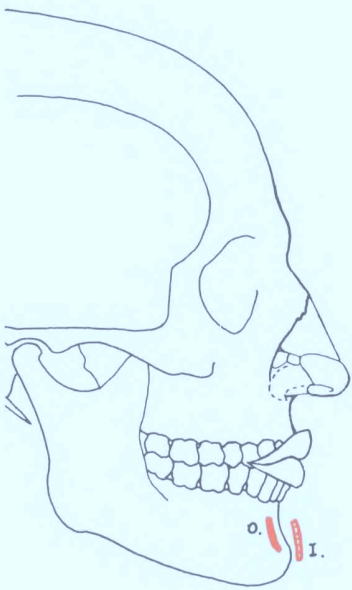
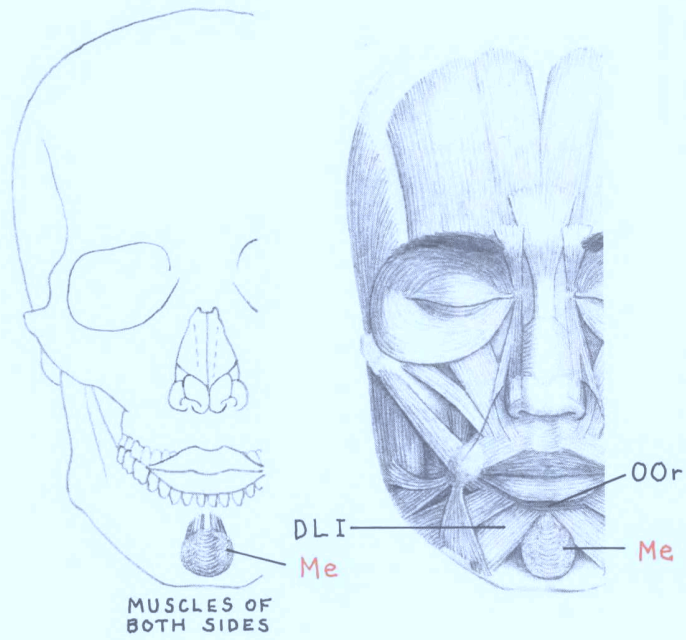
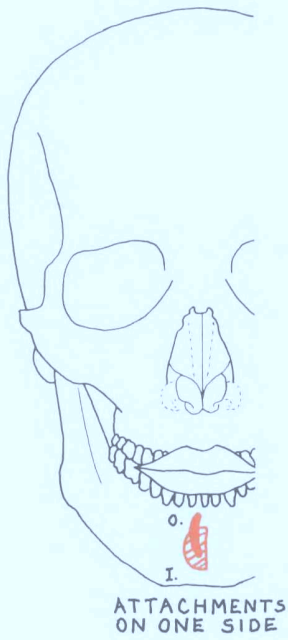
EFFECT The lower lip curves downward at its center. A horizontal skin fold (the mentolabial sulcus) below the lower lip may develop or deepen. The fleshy prominence of the chin is pushed downward. The mouth does not widen.

EXPRESSION Primarily used in speaking.



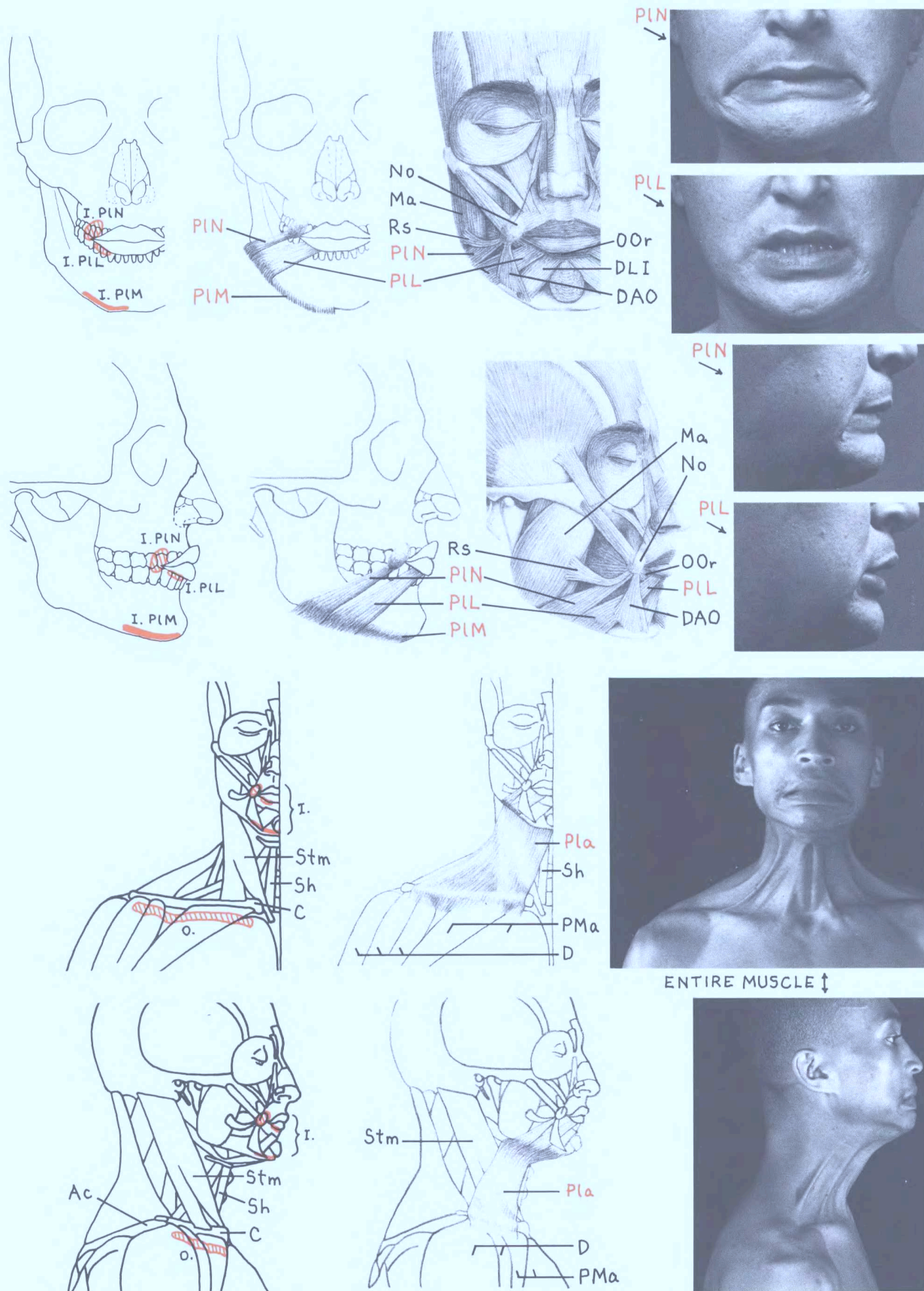
OO Orbicularis oris PIL Platysma—labial portion

The Facial Muscles • MENTALIS



DLI *Depressor labii inferioris* Me *Mentalis* OO *Orbicularis oris*

The Facial Muscles • PLATYSMA



Ac Acromion C Clavicle D Deltoid DAO Depressor anguli oris DLI Depressor labii inferioris
 Ma Masseter No Node OOr Orbicularis oris Pla Platysma PIL Platysma—labial portion
 PIM Platysma—mandibular portion PIN Platysma—nodular portion PMa Pectoralis major
 Rs Risorius Sh Sternohyoid Stm Sternomastoid

Expression of the Emotions

come slightly parted. When the levator labii superioris alaeque nasi contracts unilaterally, skin wrinkles form on that side of the nose only.

- The corners of the mouth are pulled *straight back* (posteriorly, not laterally) and dimpled, on both sides or on one side only (buccinator).

Disgust and contempt are closely related yet distinct, and are grouped together.

Disgust often blends with anger and surprise. It is brought about by the actual experiencing of unpleasant sights, tastes, smells, or tactile experiences, or just by the thought of them. Sticking the tongue out, as in an attempt to remove undesired matter from the mouth, is an extreme form of disgust. Vomiting is the ultimate disgust reaction.

Contempt is the expression of condescension toward people, with a feeling of superiority felt, or hoped for, by the expresser. The head may be tipped back so the eyes look down at the other person. In this position, the nose is raised and the upper eyelids are lowered.

Interest/Excitement

Variations of the basic emotion (type/intensity): alertness, brightness, attentiveness, expectancy and anticipation.

Appearance and muscle action:

- The eyebrows are raised, producing horizontal wrinkles across the entire forehead (frontalis—both medial and lateral portions).
- The eyebrows may be pulled together (in either their normal or raised positions), creating vertical furrows between them (corrugator supercilii).
- The mouth is open and may be relaxed or rounded and pursed (incisivus labii superioris and inferioris).
- The head may be advanced forward.

Interest/excitement is also characterized by a focused gaze with continuous eye tracking of

the person or object of interest. Slight turning of the head so as to direct the ear toward the sound stimulus may also be present. Interest/excitement is the opposite of boredom, and often accompanies other emotions (happiness, fear). It is similar to surprise, but surprise is a very brief emotion. If the appearance of surprise lasts for an extended period of time, it is probably interest/excitement.

Pain/Distress

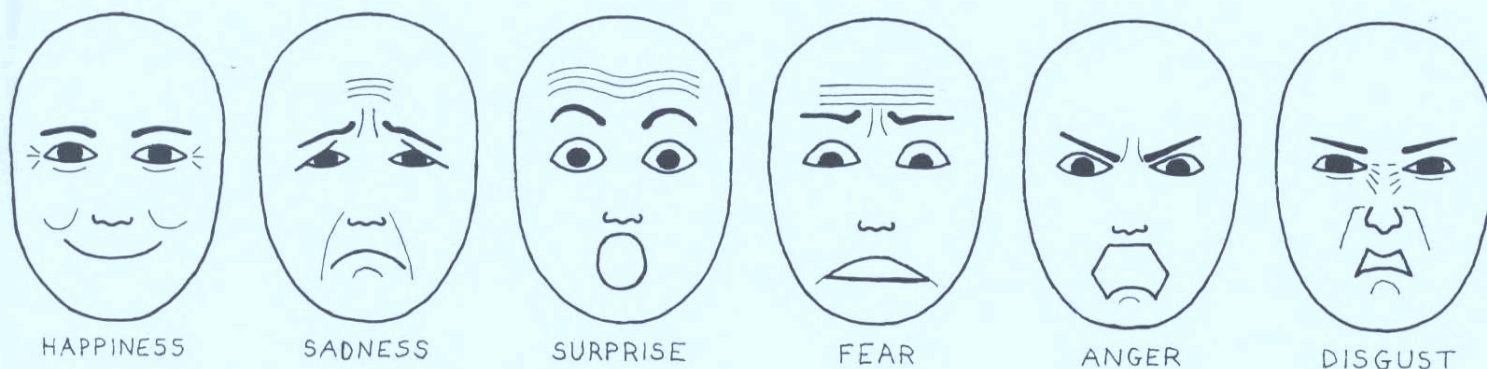
Variations of the basic sensation (type/intensity): Discomfort, ache, hurt, unbearable pain.

Appearance and muscle action:

- The eyes are completely and tightly closed for long periods of time; the cheeks are raised (orbicularis oculi—both orbital and palpebral portions).
- The eyebrows are pulled together and downward (corrugator supercilii, procerus, depressor supercilii).
- The mouth is usually wide open, and the lips are squared-off in preparation for crying or screaming. The angles of the mouth are pulled outward and downward (upper labial tractors, labial and nodular platysma).
- The mouth may be tightly pressed together, and the jaw tightly clenched (orbicularis oris—outer portion, mentalis, nasalis—transverse portion, temporalis, masseter).
- High skin ridges appear on the neck (all three parts of the platysma).

Pain/distress is usually characterized by intense muscular contraction. It is often accompanied by sadness, crying, or screaming.

Author's note: The complex subject of what actually constitutes the emotions, and their expression on the face, is still under much discussion in the psychological literature.



Expression of the Emotions



Neutral



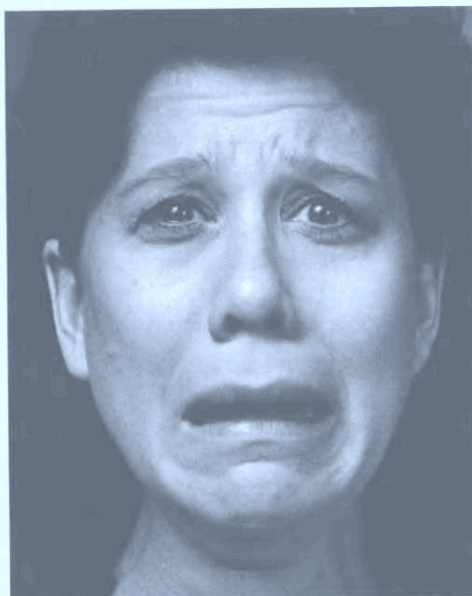
Happiness—closed mouth




Happiness—open mouth



Sadness—closed mouth



Sadness—open mouth




Surprise

Expression of the Emotions



Fear



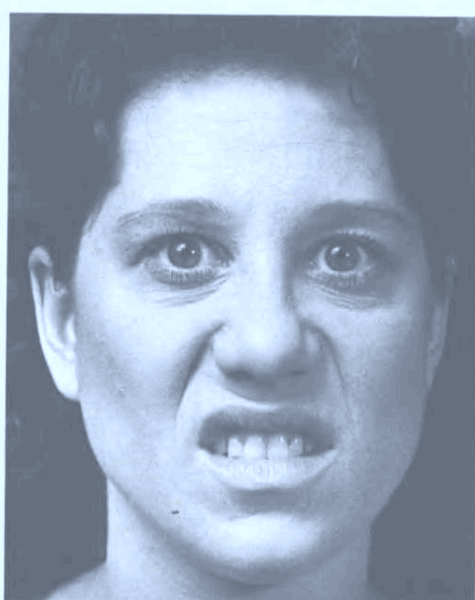Anger—closed mouth



Anger—open mouth



Disgust—Levator labii superioris alaeque nasi

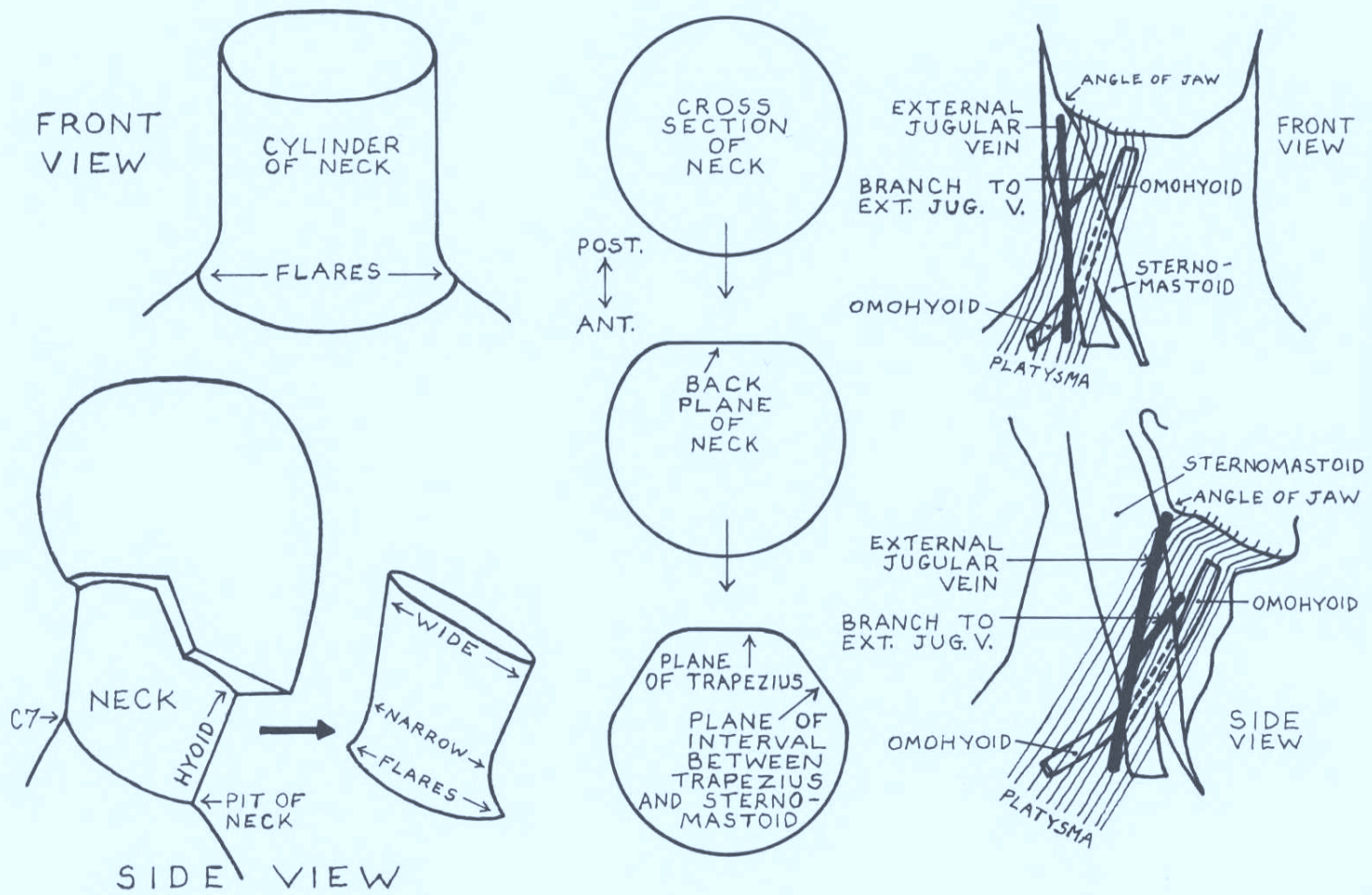


Disgust—Levator labii superioris

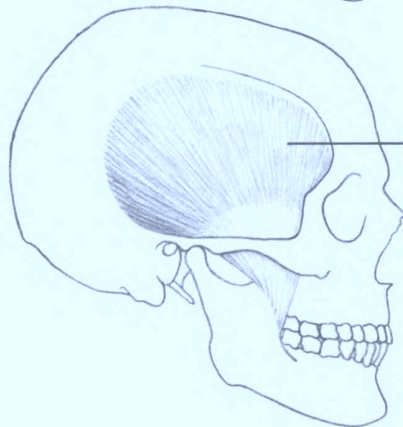
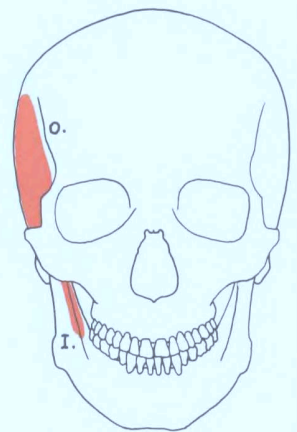
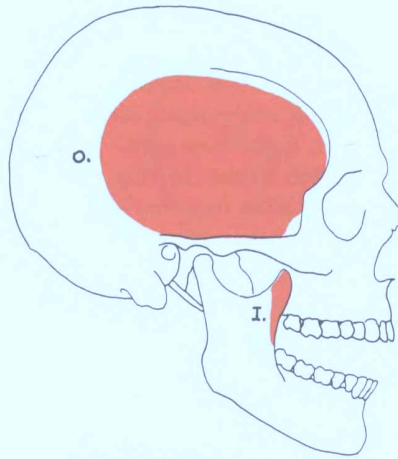


Contempt

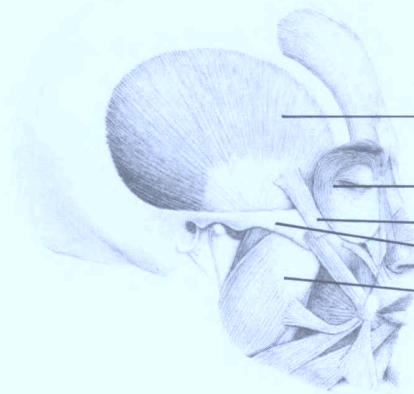
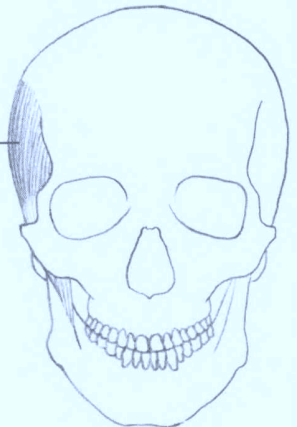The Head and Neck Muscles



The Head and Neck Muscles • TEMPORALIS



Te



Te

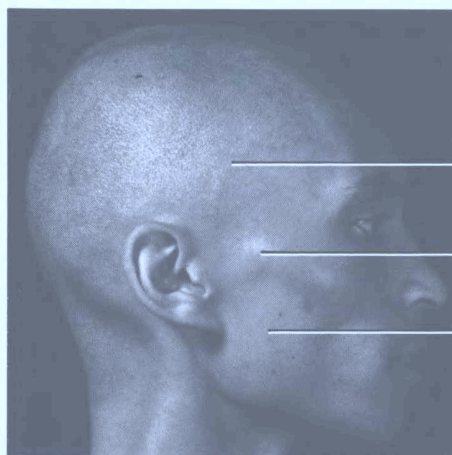
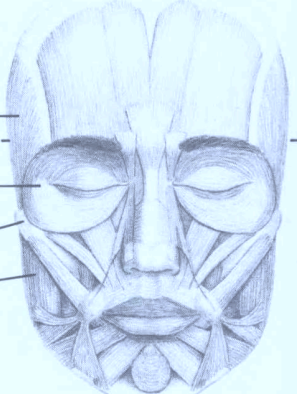
A---

OOc

Mal

ZA

Ma



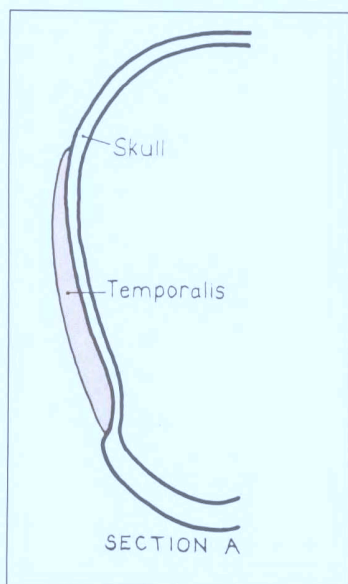
Te

ZA

Ma



Ma Masseter Mal Malaris OOc Orbicularis oculi Te Temporalis ZA Zygomatic arch



Temporalis

ORIGIN Entire temporal fossa on the side of the skull and the deep surface of the temporal fascia covering the muscle.

INSERTION Apex and deep surface of the coronoid process of the mandible (jaw bone) and into the front edge of the ramus of the mandible almost as far down as the last molar.

ACTION Lifts the mandible, which closes the jaw; the posterior fibers pull the jaw backward. The temporalis holds the jaw closed when the head is upright, and it clenches the teeth for chewing.

STRUCTURE The temporalis is a flat, fan-shaped muscle, thin at its margin, that fills the depression on the side of the skull. The side of the skull (the area of origin of the temporalis) and the inner surface of the temporal fascia (which covers the temporalis) form a flattened container from whose inside surfaces the temporalis originates. The fibers of the temporalis converge into a strong tendon deep to the zygomatic arch.

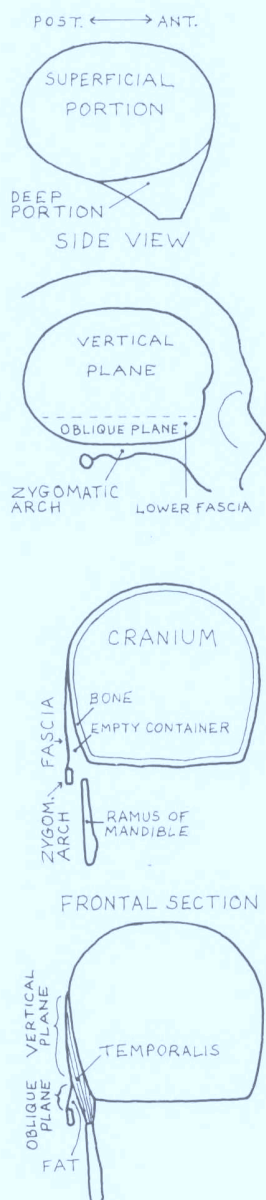
The superficial portion of the temporalis produces a horizontal oval relief on the surface when seen. The anterior portion of the muscle may be slightly recessed from the outer bony portion of the orbit, which then becomes prominent. The posterior portion of the temporalis is usually covered by hair.

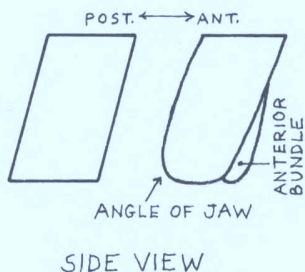
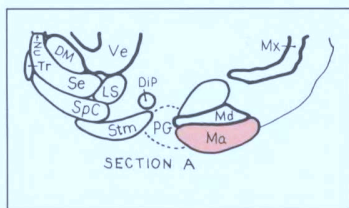
The **temporal fascia** is a strong, dense layer of fascia that lies on top of the temporalis, attaching to the skull just beyond the margin of the muscle (the muscle attaches to the inferior temporal line on the skull; the temporal fascia continues past it to attach to the superior temporal line). Inferiorly (a short distance superior to the zygomatic arch), the temporal fascia leaves the surface of the temporalis to attach to the upper edge of the zygomatic arch. At this point, a substantial accumulation of fat lies be-

neath the fascia (on top of the muscle). The plane of this lower fascia is basically oriented obliquely outward and upward, in contrast to the vertical orientation of the larger portion of the temporal fascia, which lies on the temporalis muscle belly. Because the plane of the lower fascia is directed slightly upward, it receives more light than the vertical temporalis. The lower fascia flows into the zygomatic arch, creating a single, rounded, horizontal form on the side of the cheek. There is usually no visible separation between the top edge of the zygomatic arch and lower portion of the fascia. The plane of the lower fascia gradually blends into the plane of the temporalis.

Because the lower portion of the fascia spans over to the zygomatic arch, the temporalis never appears to actually pass under the zygomatic arch. The bony zygomatic arch itself is usually not sharply defined. Only occasionally does it show clearly.

At the temple (posterior to the bony orbit of the eye and superior to the zygomatic arch), the temporalis is seen bulging when the jaw is closed (the belly is shortened and thickened) and sinking in when it is opened (the belly is stretched and thinned). When the jaw is fully opened, however, the condyle and ramus of the mandible move forward, compressing the fat and muscular tissue in front of them. This pushes the fat lodged under the zygomatic arch upward, which bulges the lower portion of the temporal fascia outward. The advancing mandibular condyle and compressed tissue also bulge the masseter muscle below the zygomatic arch outward (laterally), the net result being that the horizontal zygomatic arch becomes recessed between the fatty bulge above and the muscular bulge below. This is unusual, because stretched and elongated muscles always become thinner, increasing the projection of adjacent bony areas.





Masseter

ORIGIN *Superficial part:* Anterior two-thirds of the inferior border of the zygomatic arch, continuing forward to the zygomatic process of the maxilla. *Deep parts:* Inner (deep) surface of the entire zygomatic arch.

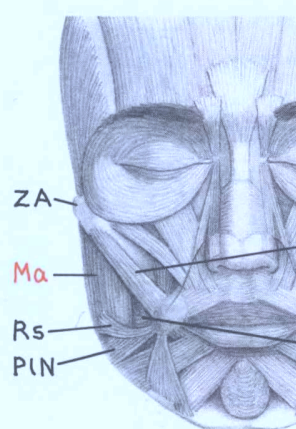
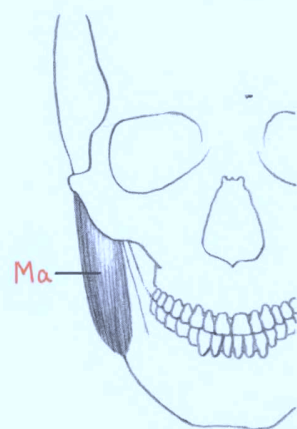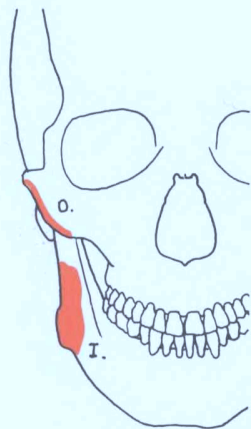
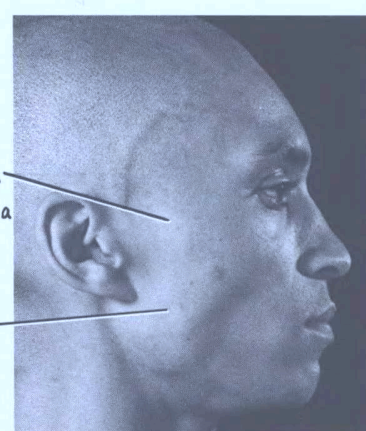
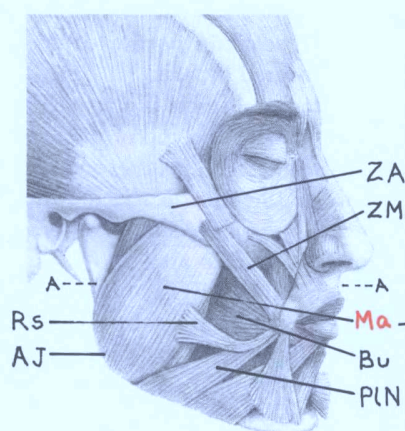
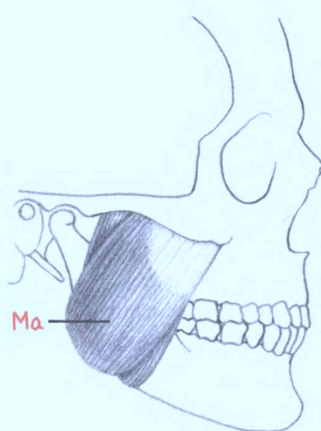
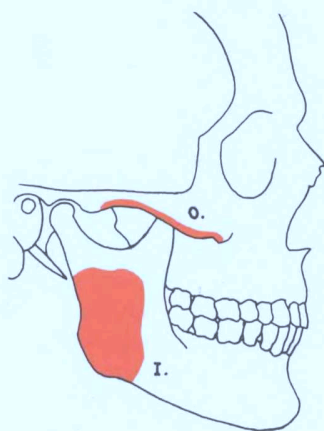
INSERTION Lateral surfaces of the coronoid process, ramus, and angle of the jaw.

ACTION Closes the jaw by lifting the mandible; clenches the teeth for chewing.

STRUCTURE The masseter is a thick quadrilateral muscle that lies obliquely on the side of the jaw. It is directed from the lower margin of the zygomatic arch and cheekbone downward and backward to the angle of the jaw. Only its superficial portion is seen. When clenching the

teeth because of tension, or when chewing, the bulge of the masseter belly can be seen separating into several thin, elongated, parallel bundles, directed along the overall axis of the form of the muscle. The most anterior of these bundles shows up on the lower half of the front edge of the belly. The entire front edge of the muscle may be seen if the cheek fat is thin, whereas the back edge is not distinct as it is softened by the overlying parotid gland.

The surface planes of the masseters' on both sides of the head usually converge slightly inferiorly, but may at times be parallel or even diverge inferiorly. The surface of the masseter may flow into the surface of the zygomatic arch (no separation), or the superior end of the masseter may be recessed slightly, leaving the lower edge of the zygomatic arch defined.



AJ Angle of jaw Bu Buccinator DiA Digastric—anterior belly Hy Hyoid bone Ma Masseter
Md Mandible Mo Molar Mx Maxilla My Mylohyoid PG Parotid gland

The Head and Neck Muscles • MYLOHYOID

Mylohyoid

ORIGIN A line along the anterior three-quarters of the inner surface of the body of the lower jaw.

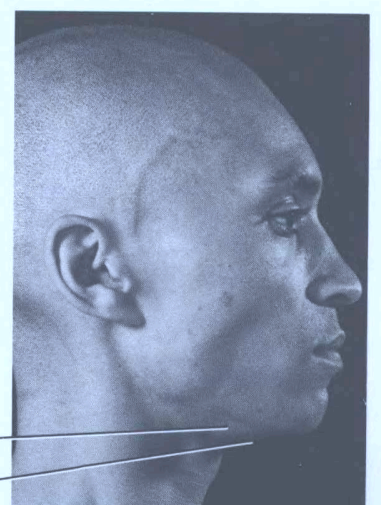
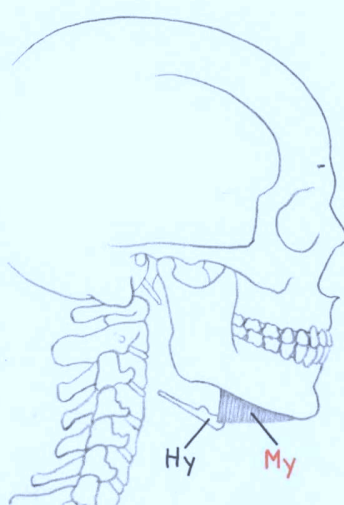
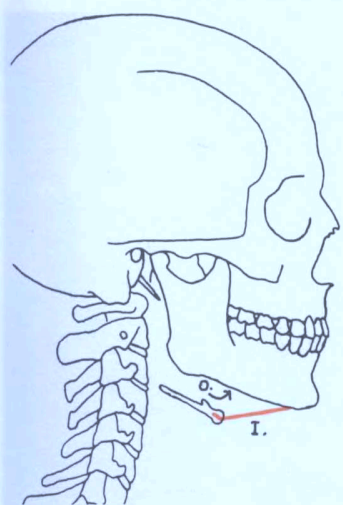
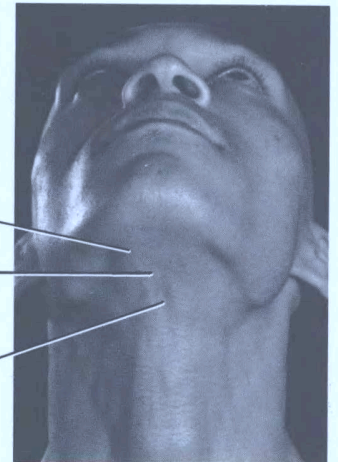
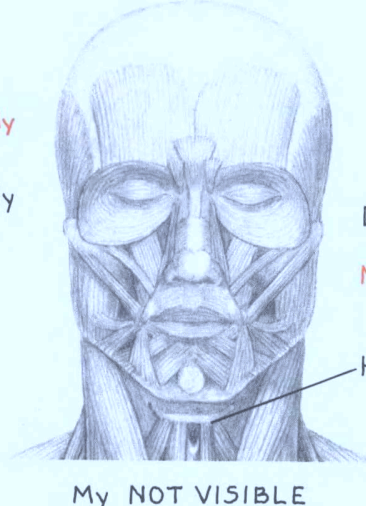
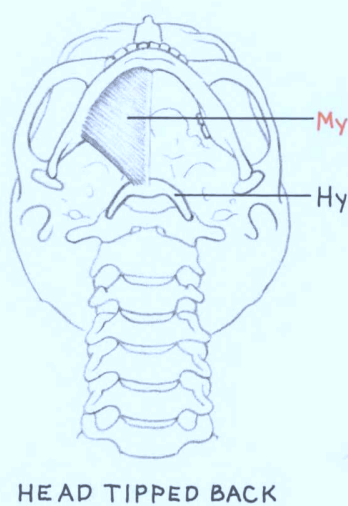
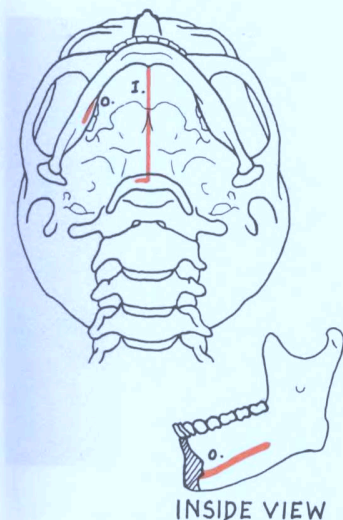
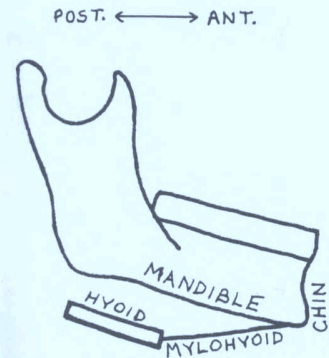
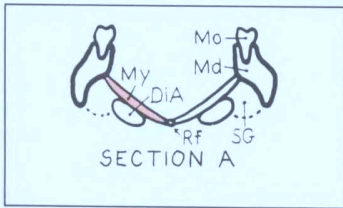
INSERTION A median tendinous line, or raphe (actually part of the mylohyoid itself), which passes from the midline at the bottom of the chin to the midline on the front of the hyoid bone. Most of the muscular fibers of the mylohyoid insert into this raphe (the fibers from the muscles of both sides meet here), while the most posterior fibers insert directly into the front surface of the hyoid bone.

ACTION Lifts the floor of the mouth and the hyoid bone when swallowing.

STRUCTURE The mylohyoid is a flat, sheet-like triangular muscle. The muscles of both

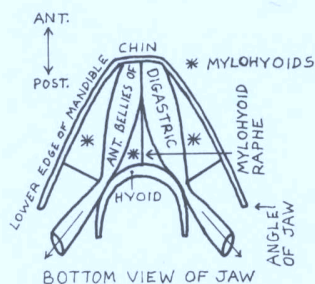
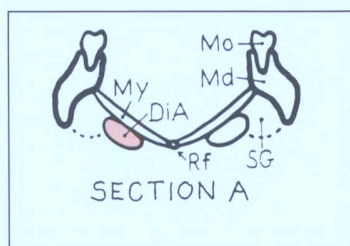
sides span the bottom of the jaw and are upwardly recessed from the lower border of the body of the mandible at their lateral edges (their origins). The overlying anterior bellies of the digastric, submandibular glands, and fat join with the mylohyoids in creating the **bottom plane of the jaw**.

The mylohyoid of each side passes medially and *downward* to its insertion on the median raphe and hyoid bone. Looking at the side view of the bottom plane of the jaw, its profile (at the midline) passes backward and slightly downward (is almost *horizontal*), whereas the line of the bottom edge of the mandible passes backward and slightly upward (is *oblique*).



PIN Platysma—nodular portion Rf Raphe Rs Risorius SG Submandibular gland
ZA Zygomatic arch ZMa Zygomaticus major

The Head and Neck Muscles • DIGASTRIC



Digastric (Biventer Mandibulae)

ORIGIN The mastoid notch on the bottom of the mastoid process of the skull.

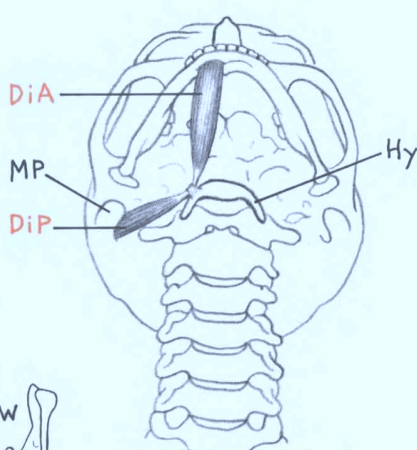
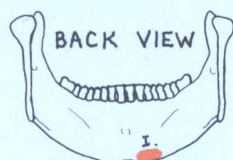
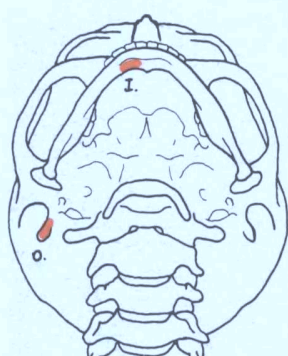
INSERTION The lower edge of the deep surface of the mandible behind the chin (just off the midline).

ACTION Opens the mouth by pulling the front of the lower jaw down; lifts the hyoid bone.

STRUCTURE The digastric consists of two bellies, an anterior and a posterior, that are connected end to end by a short, centrally located tendon. The tendon is hooked to the side

of the body and greater horn of the hyoid bone by a fibrous sleeve through which it passes.

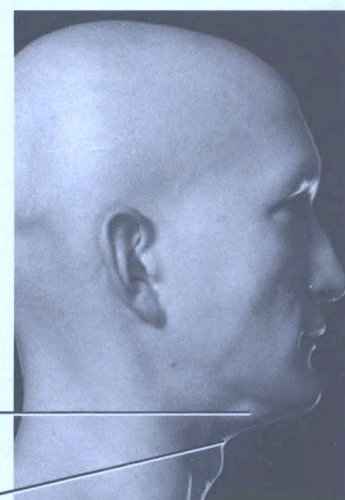
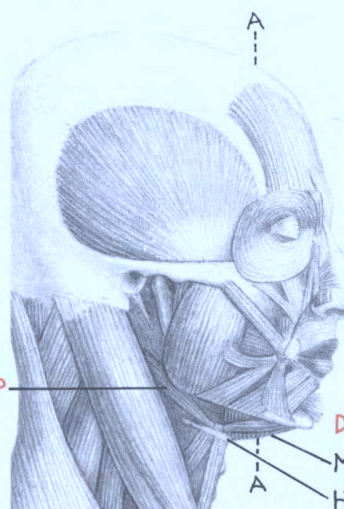
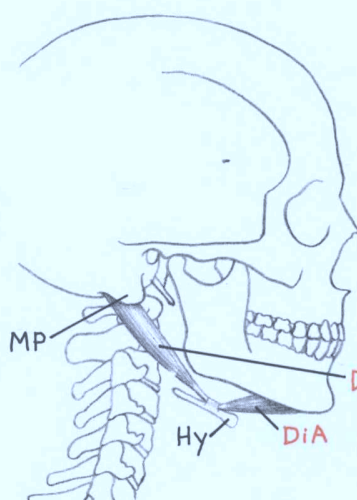
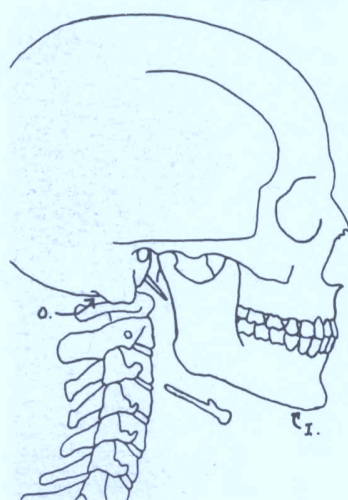
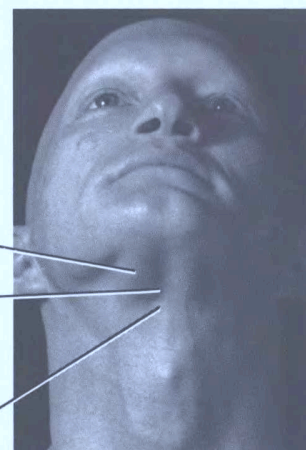
The anterior belly of the digastric is larger and thicker than the posterior belly. The anterior belly sometimes appears as a subtle elongated relief that is directed posteriorly and slightly laterally. It lies on the bottom plane of the lower jaw, on the surface of the mylohyoid muscle. When the head is extended, exposing the bottom of the jaw, the muscles of both sides can sometimes be seen diverging posteriorly from the chin. The posterior belly is covered by the parotid gland.



HEAD TIPPED BACK

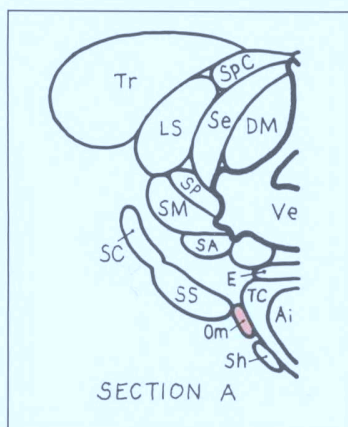


DIGASTRIC NOT VISIBLE



DiA Digastric—anterior belly DiP Digastric—posterior belly Hy Hyoid bone LS Levator scapulae
MP Mastoid process My Mylohyoid Om Omohyoid SC Sternomastoid—clavicular head

The Head and Neck Muscles • OMOHYOID



Omohyoid

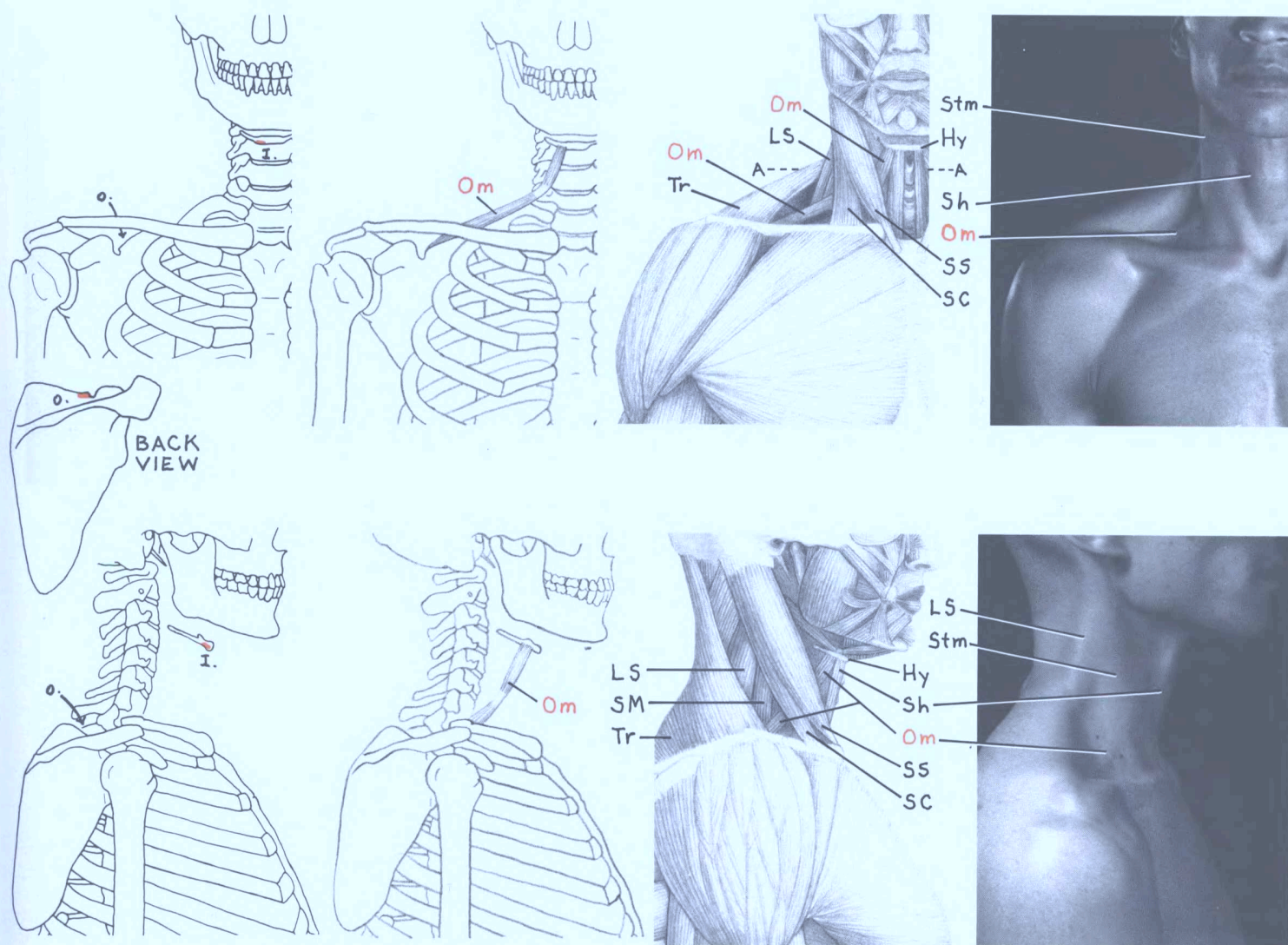
ORIGIN A short line on the superior border of the scapula, just medial to the notch at the base of the coracoid process, and sometimes from a ligament that crosses this notch.

INSERTION Inferior border of the side of the body of the hyoid bone toward the front (just lateral to the insertion of the sternohyoid).

ACTION Pulls the hyoid bone down.

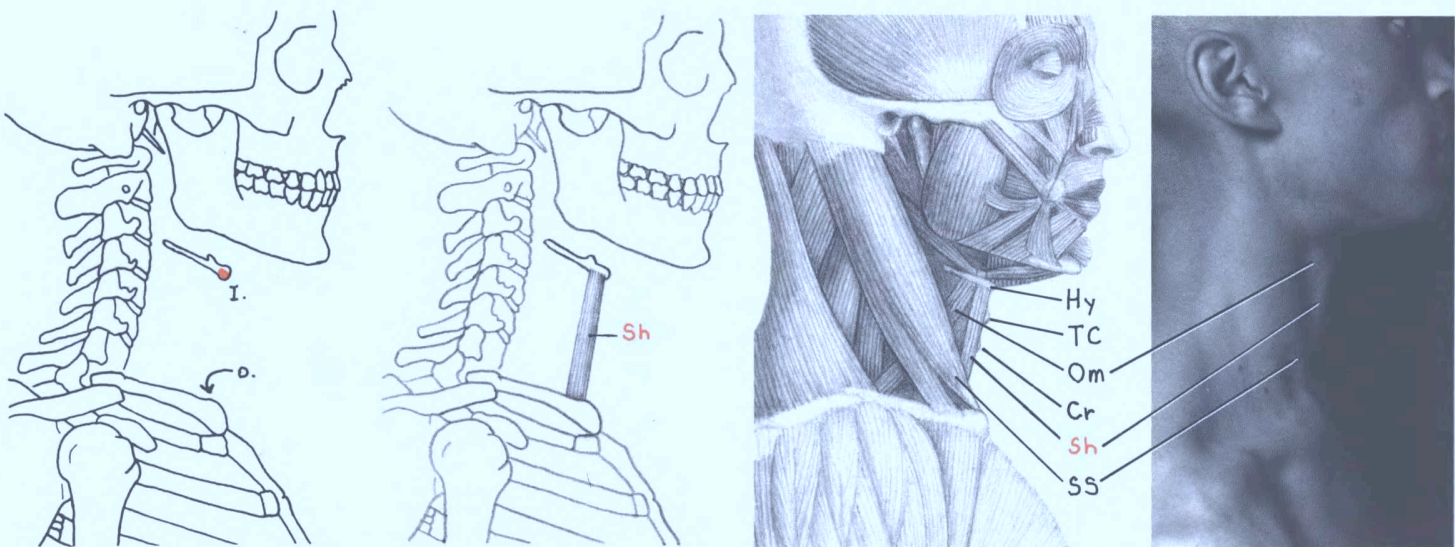
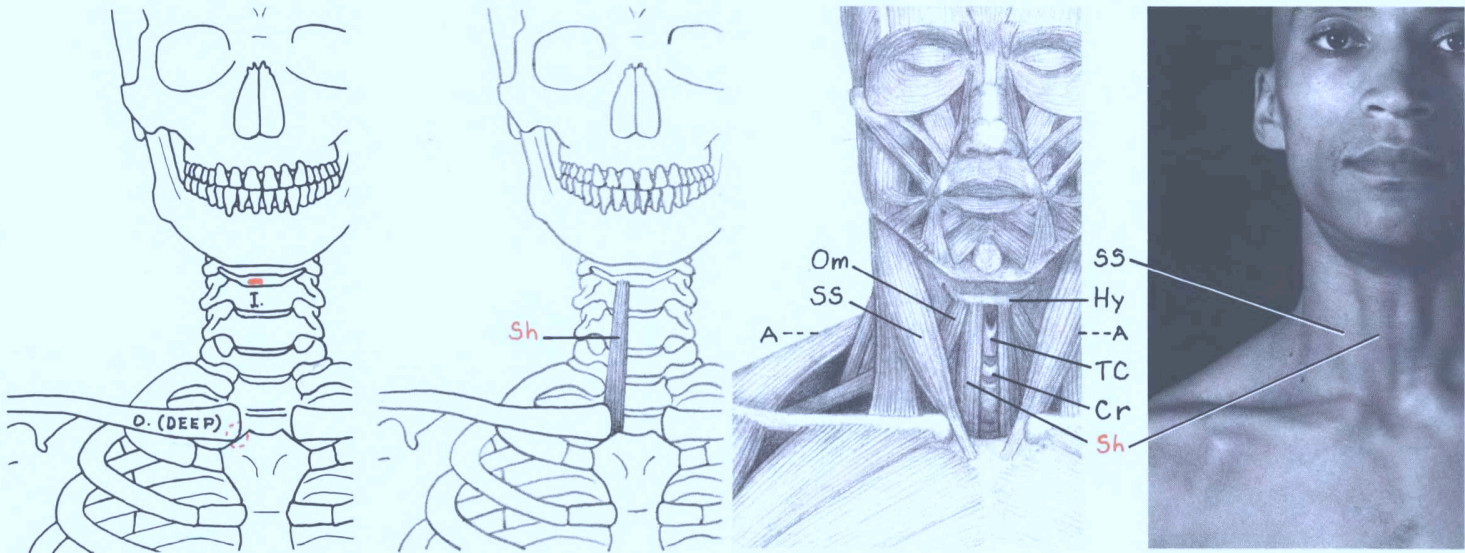
STRUCTURE The omohyoid consists of two narrow, flat bellies—a superior and an inferior—connected end to end by a short tendon. The tendon lies under the sternomastoid mus-

cle. The omohyoid bends at this tendon as it ascends upward and forward on the side of the neck. The omohyoid is occasionally seen, part directly, part indirectly, when speaking, when the muscles on the bottom of the jaw are tensed or when the head is fully turned to one side. When contracted, it straightens between its two points of attachment, lifting the sternomastoid in the process. The tendinous portion beneath the sternomastoid is then seen as a thick, oblique, cordlike relief whose form is continued both superiorly and inferiorly by the now visible superficial bellies.

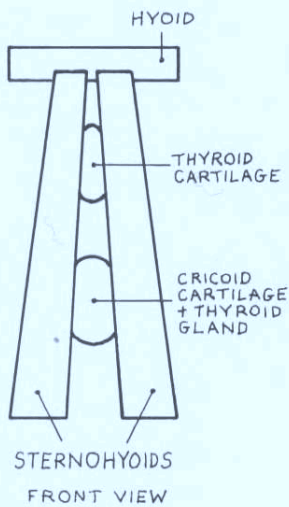
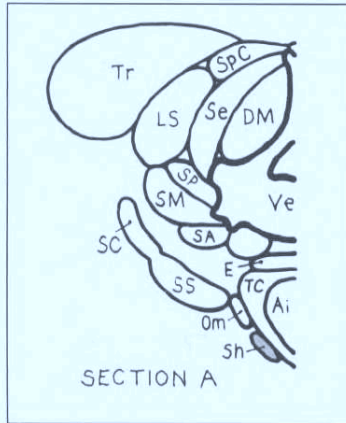


SG Submandibular gland Sh Sternohyoid SM Scalenus medius SS Sternomastoid—sternal head
Stm Sternomastoid TC Thyroid cartilage Tr Trapezius Ve Vertebra

The Head and Neck Muscles • STERNOHYOID



Cr Cricoid cartilage Hy Hyoid bone Om Omohyoid Sh Sternohyoid
 SS Sternomastoid—sternal head TC Thyroid cartilage



Sternohyoid

ORIGIN Posterior surface of the medial end of the clavicle; the upper lateral portion of the posterior surface of the manubrium of the sternum near the notch for the clavicle; and the ligament between these two bones.

INSERTION Lower border of the anterior portion of the body of the hyoid bone, just to the side of the midline.

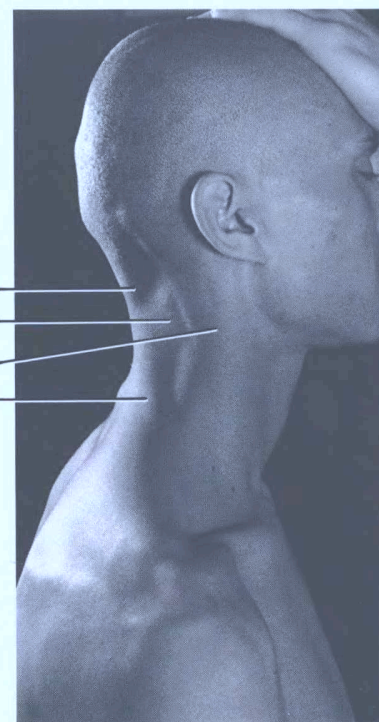
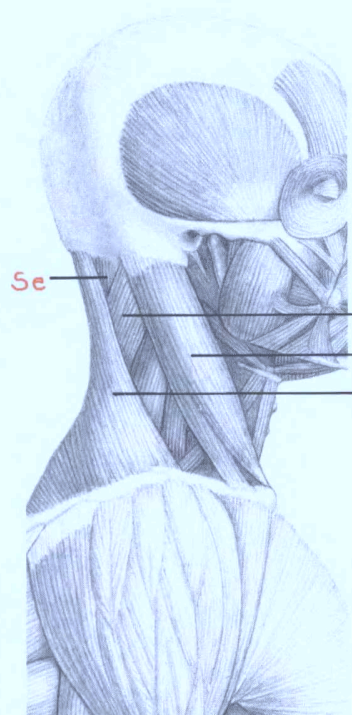
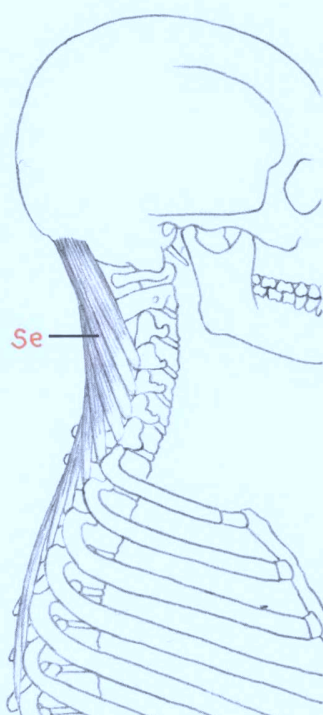
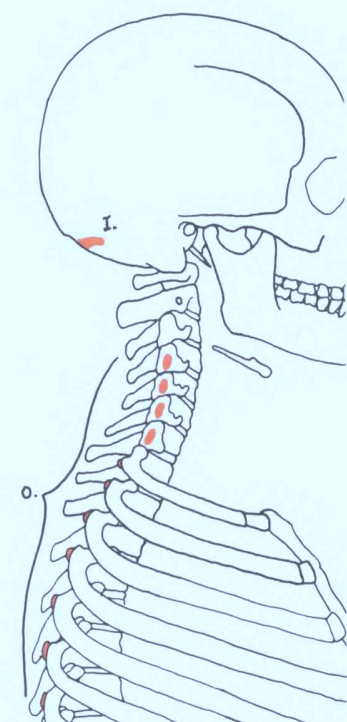
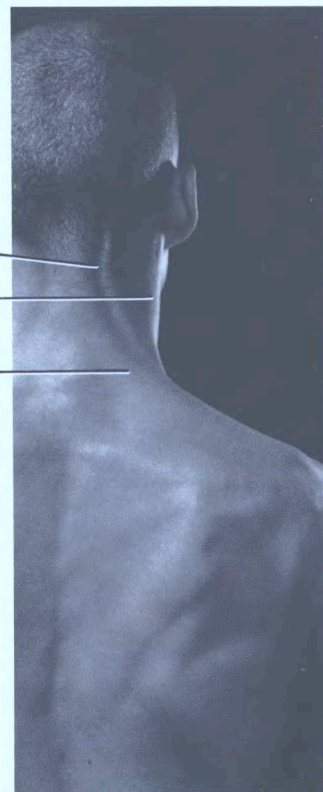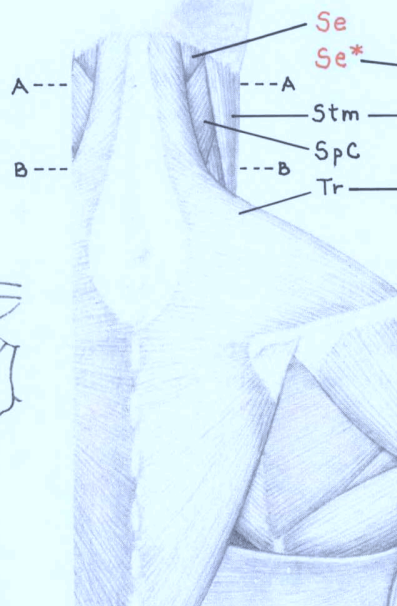
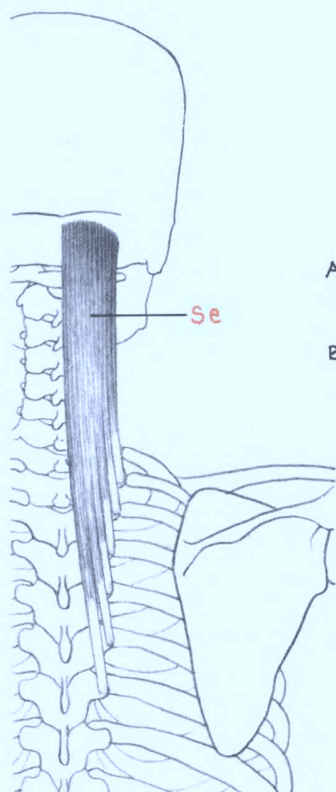
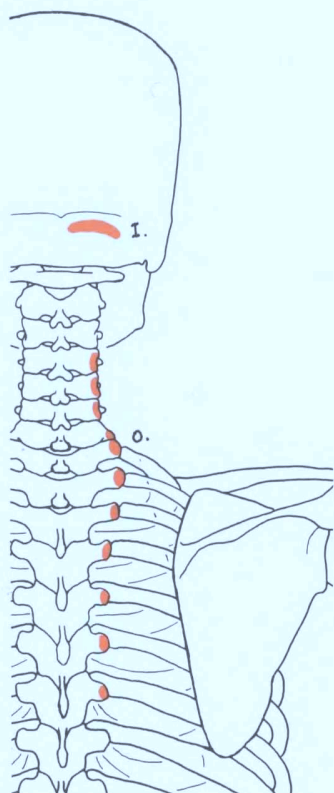
ACTION Pulls the hyoid bone down, as in swallowing; assists in flexion of the head and neck.

STRUCTURE The sternohyoid is a thin, narrow, straplike muscle located on the front of the neck, just to the side of the midline. Commonly separated by a short distance at the pit of the neck, the muscles of both sides converge

as they ascend, but never actually touch. The space between the two muscles therefore narrows superiorly. The thyroid and cricoid cartilages and the thyroid gland are partly covered by these muscles, but are subcutaneous in the interval between them. The narrow, flat form of the sternohyoid lies on top of, but doesn't conceal, the forms of the throat (thyroid and cricoid cartilages, thyroid gland).

When contracting, the sternohyoids occasionally appear as two raised straps on the front of the neck, oftentimes confused with the anterior edges of the platysma. The anterior edge of the platysma is more stringy, more oblique, and located more laterally than the almost vertical sternohyoids. Also, the platysma passes *over* the sternomastoid, whereas the sternohyoid passes *under* it.

The Head and Neck Muscles • SEMISPINALIS CAPITIS



DM Deep muscle Nu Nuchal ligament Se Semispinalis capitis SpC Splenius capitis
Stm Sternomastoid Tr Trapezius * Under trapezius

Semispinalis Capitis (Complexus)

ORIGIN Tips of the transverse processes of the vertebrae from the seventh cervical down to the sixth or seventh thoracic vertebrae and from the articular processes of the fourth through sixth cervical vertebrae.

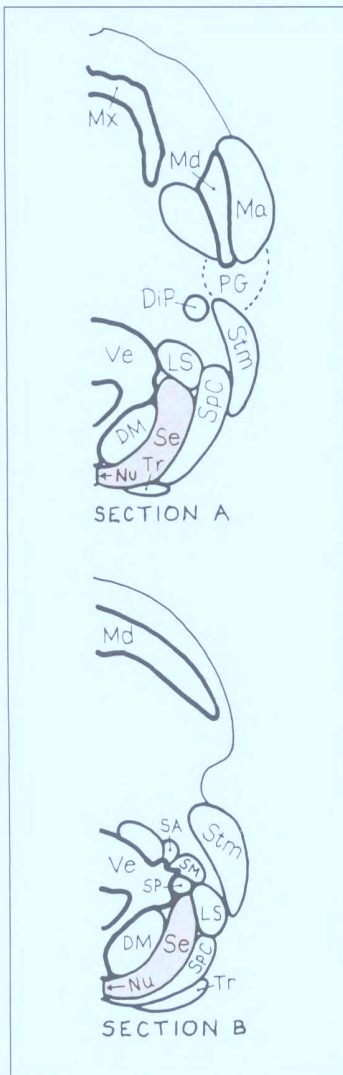
INSERTION An elongated area on the base of the skull between the superior and inferior nuchal lines of the occipital bone, just lateral to the midline.

ACTION Extends the head and rotates it so that the face is directed to the opposite side.

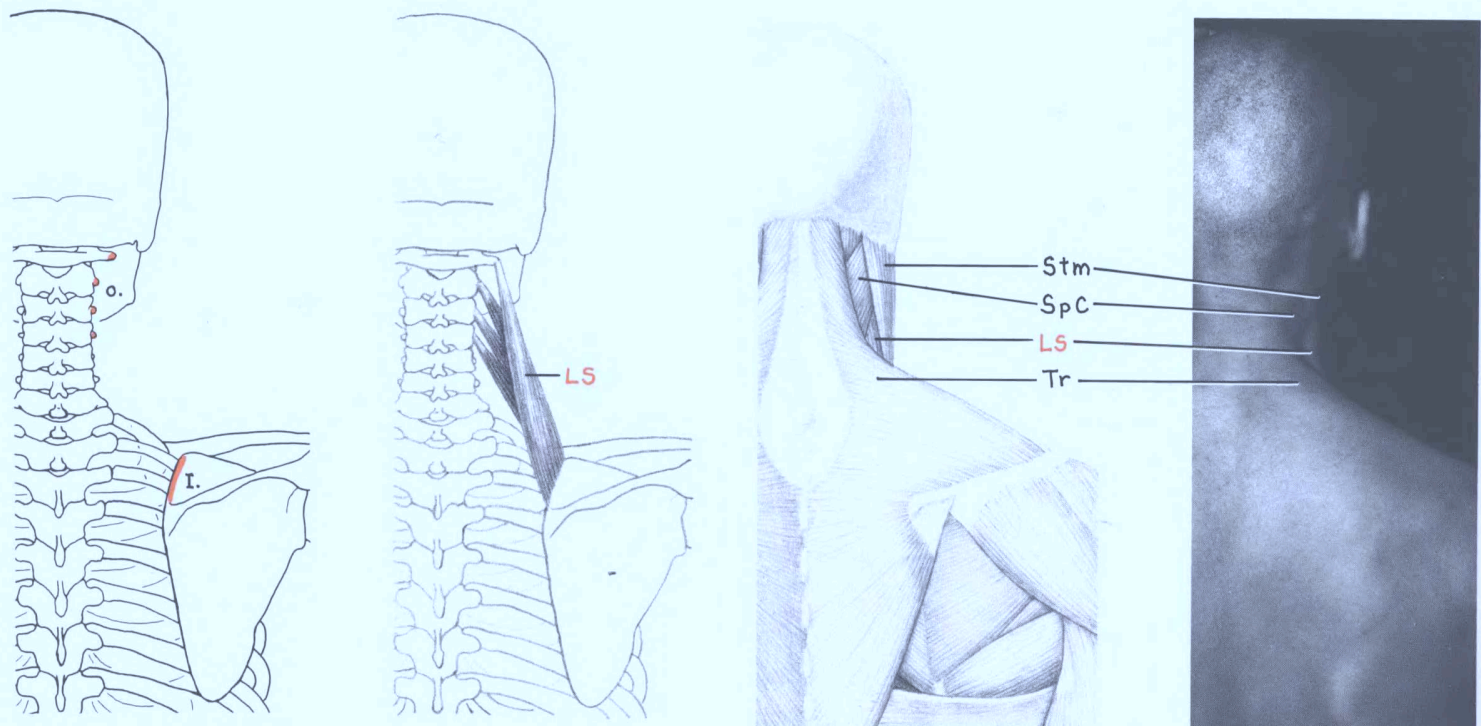
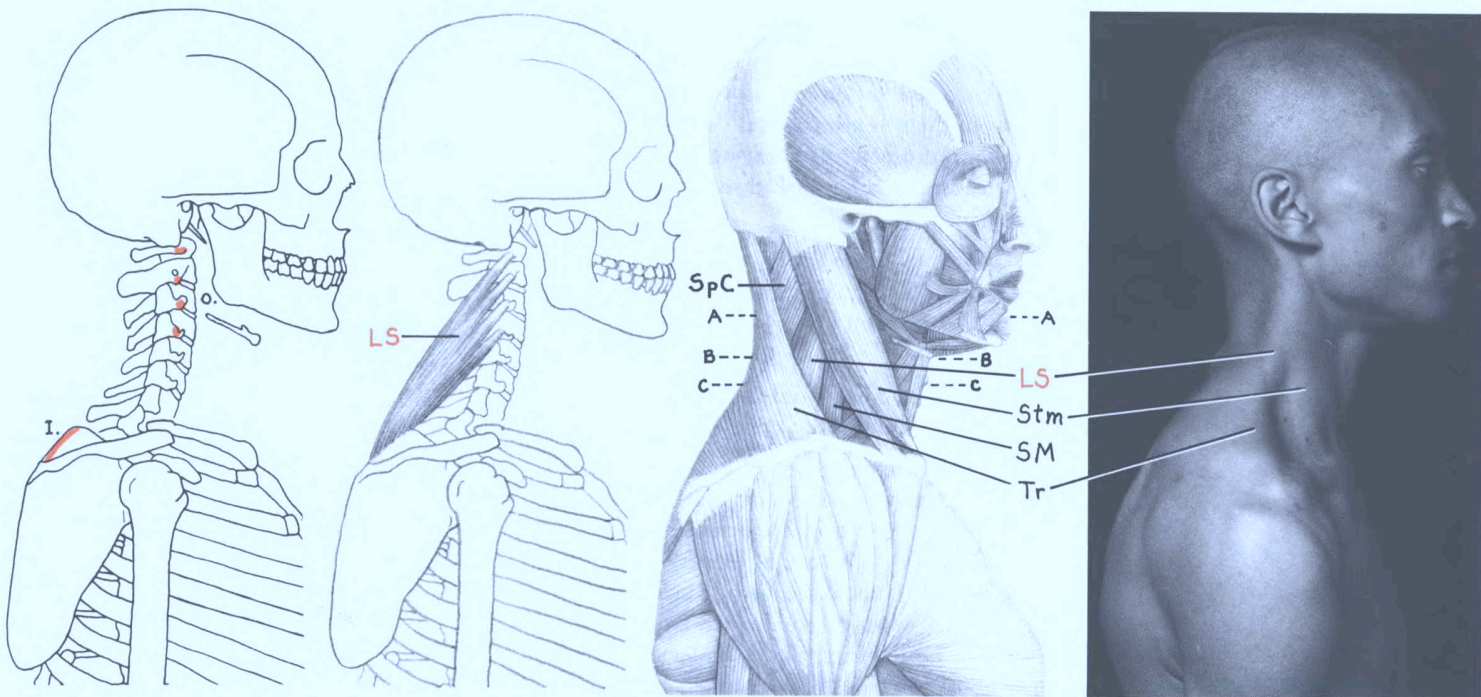
STRUCTURE Primarily a deep muscle on the back of the neck that thickens as it ascends, the semispinalis capitis makes an important contribution to the form of this region. (A very small part of it is actually subcutaneous just below the skull, but is never distinctly seen and is usually covered by the hair.) It lies under the thin uppermost portion of the trapezius, and *both* muscles create the muscular column on the back of the neck immediately to the side of the

nuchal ligament. These muscles of both sides of the body are therefore partly responsible for creating the two thick cords that characteristically appear on the back of the neck (except when the head is fully flexed). The furrow on the midline between these two columns (the posterior free edge of the nuchal ligament) deepens as it approaches the skull, ending superiorly at the external occipital protuberance (the cranial attachment of the nuchal ligament). A depression may form between the upper end of the semispinalis capitis and the sternocleidomastoid, in which the subcutaneous portion of the splenius capitis lies.

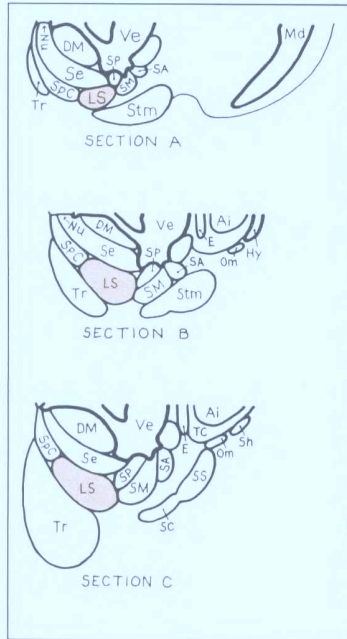
Basically vertical, the thick, somewhat flattened belly of the semispinalis capitis wraps around the deeper structures of the neck, best seen in cross section. The semispinalis capitis is part of the transversospinalis muscle group—the deepest muscle group of the back—which includes the multifidus. The medial portion of the semispinalis capitis, which tends to merge with the spinalis capitis, is called the **biventer cervicis**.



The Head and Neck Muscles • LEVATOR SCAPULAE



LS Levator scapulae Se Semispinalis capitis SM Scalenus medius SpC Splenius capitis
Stm Sternomastoid Tr Trapezius



Levator Scapulae

ORIGIN Transverse processes of the first four cervical vertebrae.

INSERTION Upper portion of the vertebral border of the scapula, between the superior angle and the base of the spine of the scapula.

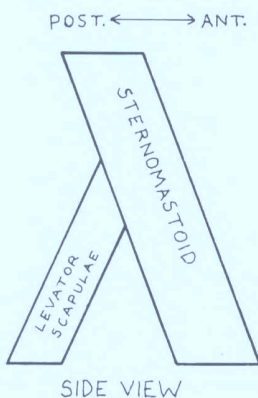
ACTION Raises the scapula while pulling it slightly medially. It assists in rotation of the scapula by raising the vertebral border, which produces downward rotation of the acromion. When the shoulder is fixed, it will bend the neck laterally.

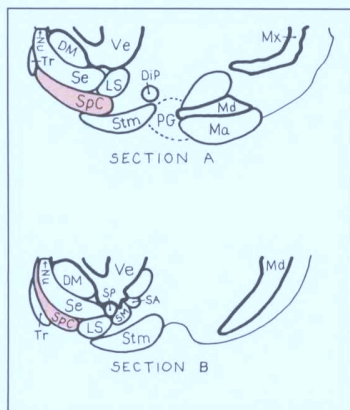
STRUCTURE Beginning deep in the side of the neck just below the skull, and ending deep in the back at the top of the shoulder, the levator scapulae is superficial only in its middle third, in the space between the sternomastoid and trapezius on the side of the neck. When the muscles located in this interval are defined, the levator scapulae is usually the most prominent. In side view, the axis of its narrow, cylindrical, subcutaneous form is oriented on a line directed from the earlobe to the deep superior angle of the scapula. The levator scapulae is located anterior to the splenius capitis, but whereas the

splenius capitis is directed downward and *medially* toward the midline of the back, the levator scapulae is directed downward and *laterally* toward the top of the scapula. The levator scapulae is the more prominent of the two, but they may also blend together.

The levator scapulae is located at the front edge of the **muscle mass of the back of the neck**. This mass is made up of the trapezius, semispinalis capitis, splenius capitis, and levator scapulae; it can be seen separating from the sternomastoid and the front half of the neck when the head is fully rotated to one side. The levator scapulae and scalenus medius are responsible for the width at the side of the base of the neck.

The levator scapulae is often difficult to see, regardless of muscular development. It is most likely to be seen in individuals with very little fat and in the elderly, especially when the arms are carrying weight and the shoulder is slightly raised, or when the neck is bent laterally against resistance. When seen, the combined forms of the levator scapulae and sternomastoid create an inverted V, with the upper end of the former passing deep to the latter.





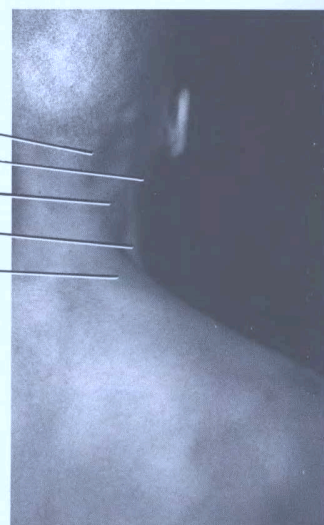
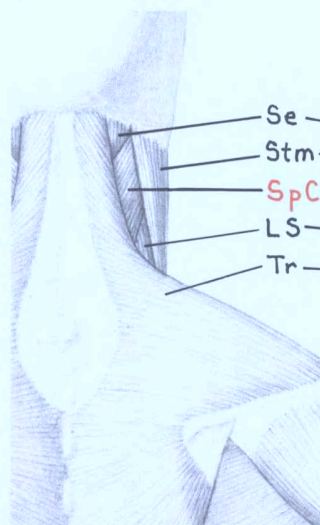
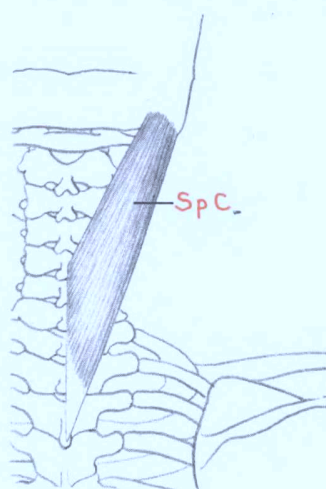
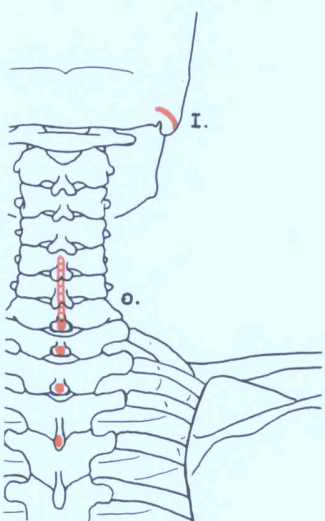
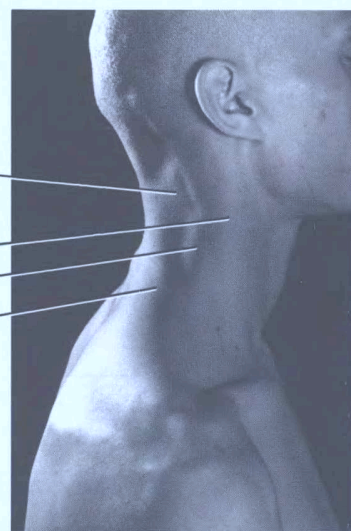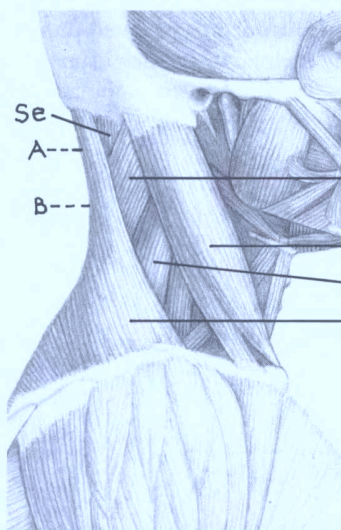
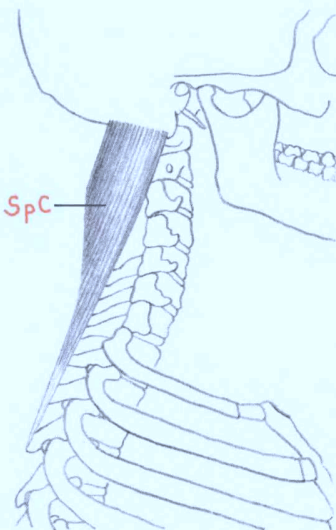
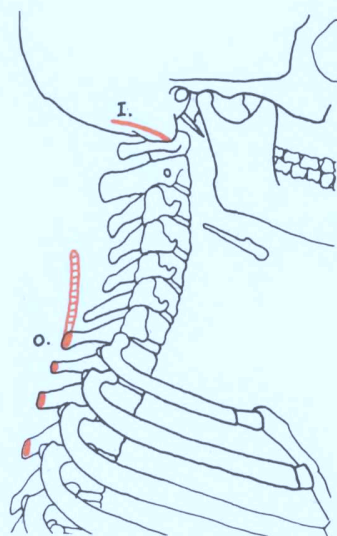
Splenius Capitis

ORIGIN The lower half of the posterior free edge of the nuchal ligament and the spinous processes of the seventh cervical and first three or four thoracic vertebrae.

INSERTION A line at the side of the base of the skull, just deep to the insertion of the sternomastoid, from the tip of the mastoid process extending back about two inches.

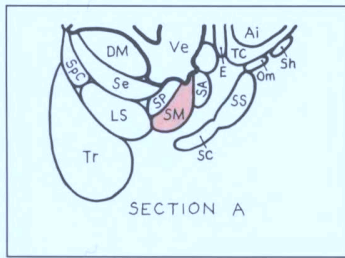
ACTION Rotates the head, turning it toward the same side as the active muscle. The muscles of both sides contracting together extend the head.

STRUCTURE The splenius capitis is a broad, sheetlike, inconspicuous muscle located on the back of the neck. Only a small area of its superior portion is superficial. When seen, its superficial portion is directed *to the mastoid process*. The front edge of the muscle, which lies at the back edge of the form of the levator scapulae, can be traced along a line from the tip of the mastoid process downward to the back of the base of the neck. The form of the levator scapulae is stronger and more pronounced than that of the splenius capitis.

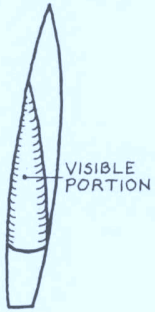


LS Levator scapulae Nu Nuchal ligament Om Omohyoid SA Scalenus anterior
SC Sternomastoid—clavicular head Se Semispinalis capitis SM Scalenus medius SP Scalenus posterior

The Head and Neck Muscles • SCALENUS MEDIUS



POST. ← ANT.



SIDE VIEW

Scalenus Medius

ORIGIN Transverse processes of the second through seventh cervical vertebrae (and occasionally from the atlas).

INSERTION Upper surface of the first rib, from its midpoint back to the tubercle.

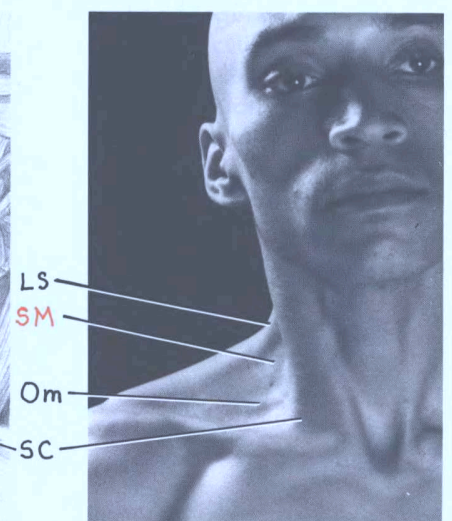
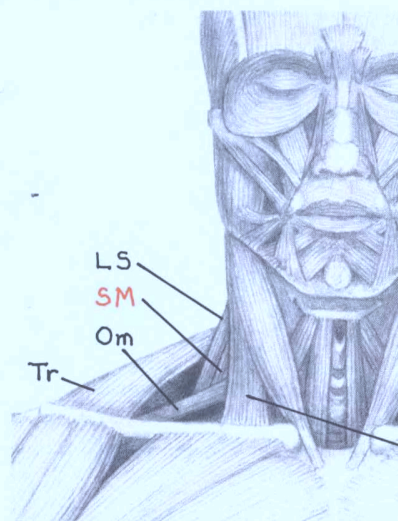
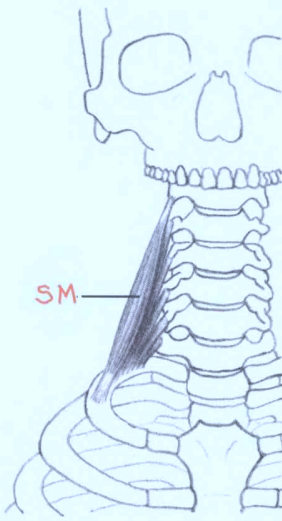
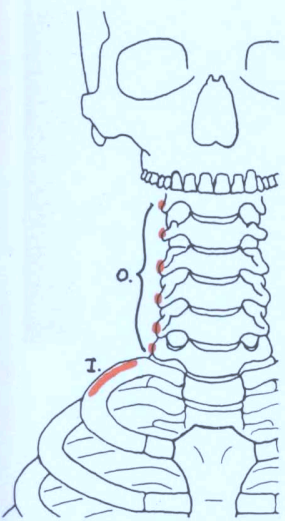
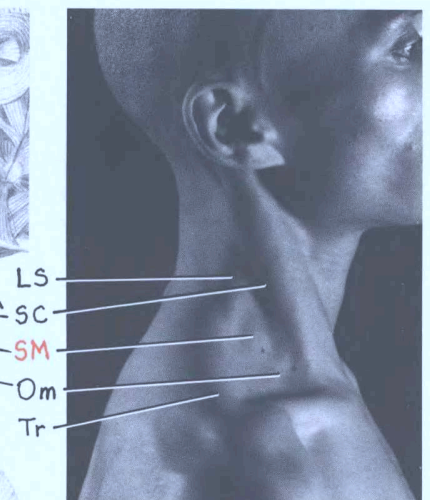
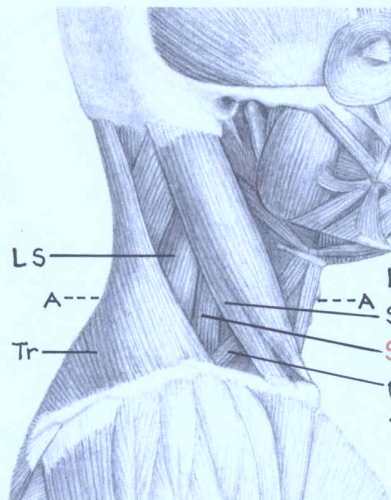
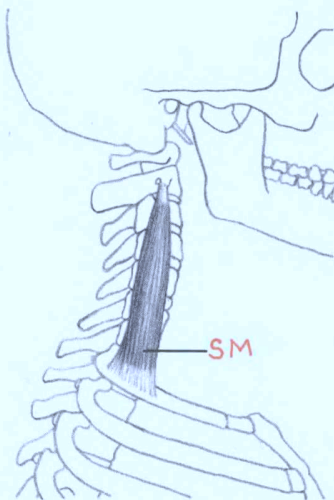
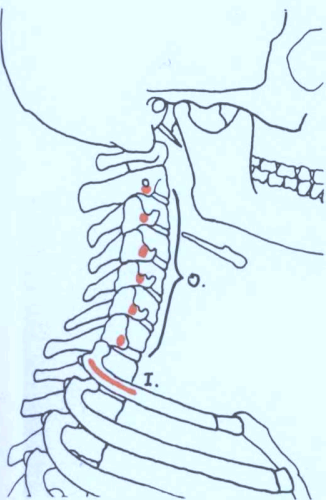
ACTION Bends the neck laterally; lifts the first rib during forced inspiration.

STRUCTURE Largest of the scalene muscles, the **scalenus medius** shows up on the middle of the lower half of the side of the neck, but not very prominently. It adds thickness to the bottom of the side of the neck where the neck flares, and is usually covered by some of the supraclavicular fat. The muscle appears as a

short, vertical, conical form, pointed superiorly, between the inverted V of the forms of the sternomastoid and levator scapulae. The scalenus medius may appear during forced inspiration.

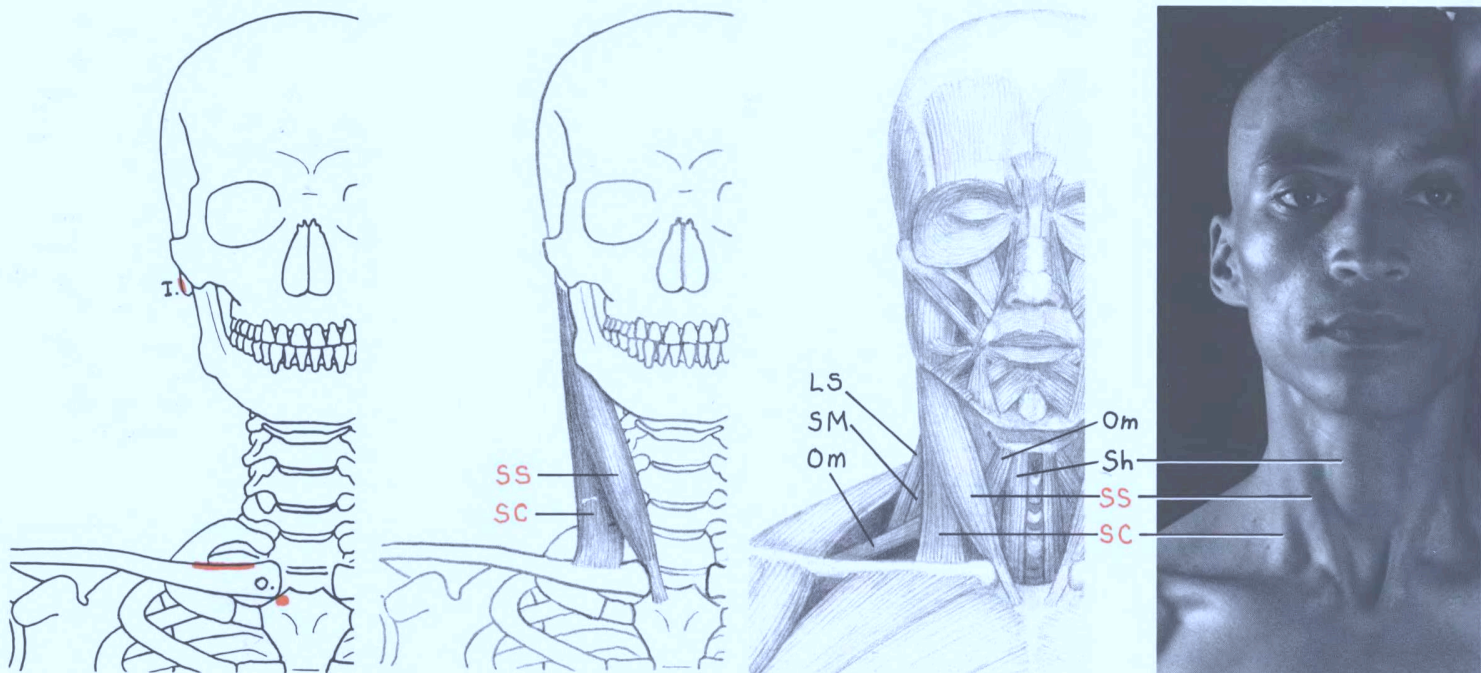
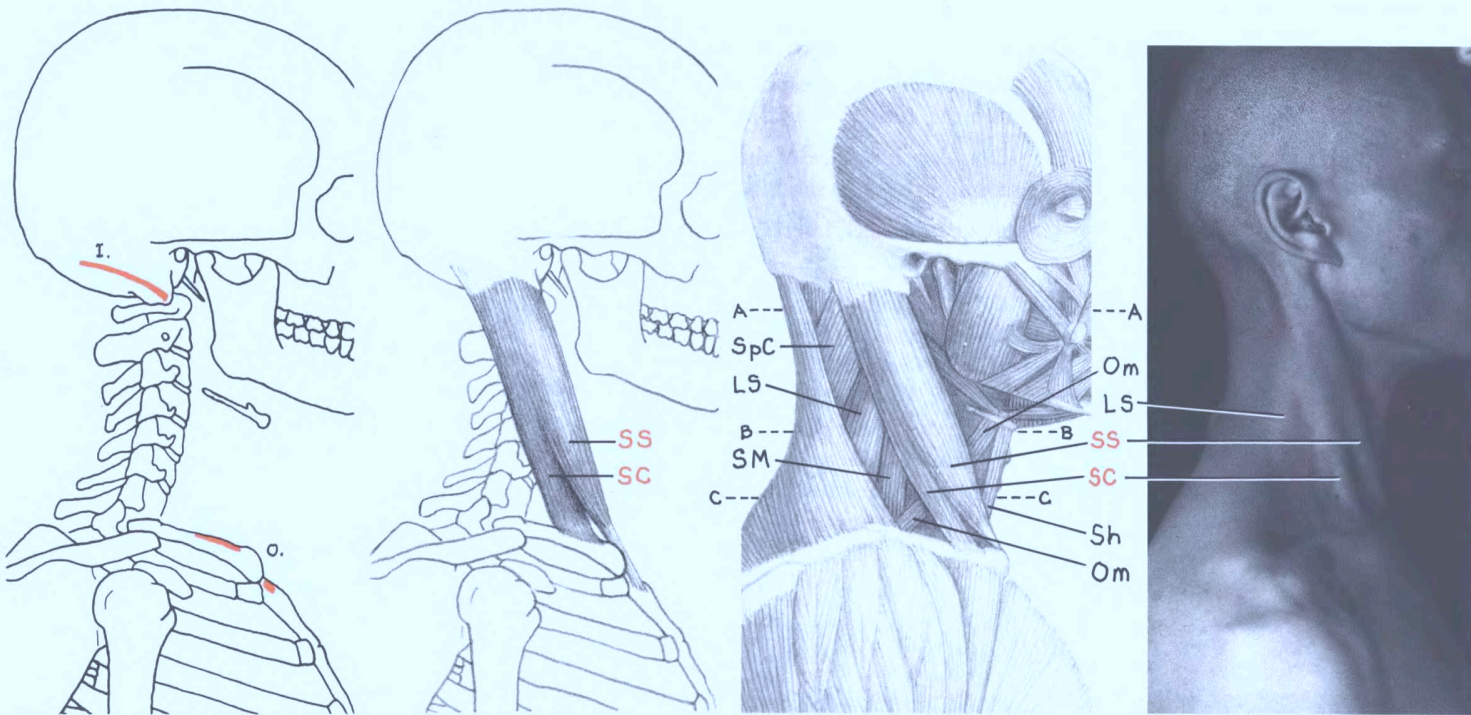
The **scalenus posterior**, arising from the transverse processes of the fourth through sixth cervical vertebrae, and inserting onto the top surface of the second rib posterior to its midpoint, is never distinct, but blends into the back of the form of the scalenus medius. The **scalenus anterior** is too deep to affect surface form.

At times, some of the nerves of the **brachial plexus** can be seen as a raised cordlike ridge passing down along the anterior edge of the form of the scalenus medius.

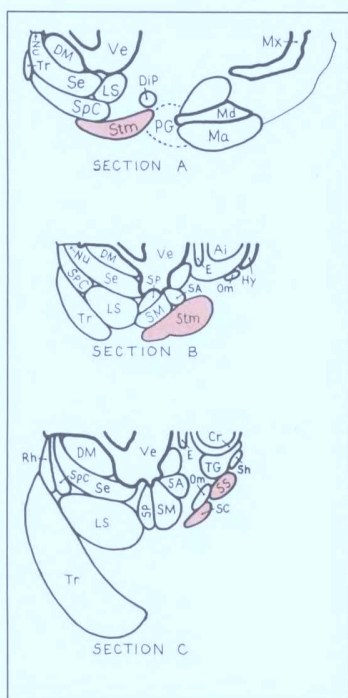


SpC Splenius capitis Stm Sternomastoid Tr Trapezius Ve Vertebra

The Head and Neck Muscles • STERNOCLEIDOMASTOID



LS Levator scapulae Mn Manubrium MP Mastoid process Om Omohyoid PG Parotid gland
 SA Scalenus anterior SC Sternomastoid—clavicular head Sh Sternohyoid SM Scalenus medius
 SpC Splenius capitis SS Sternomastoid—sternal head Stm Sternomastoid TG Thyroid gland



Sternocleidomastoid (Sternomastoid)

ORIGIN *Sternal head:* Upper part of the anterior surface of the manubrium of the sternum, near the midline. *Clavicular head:* Upper surface of the medial third of the clavicle, excluding the medial expansion of the clavicle. The area of origin extends downward onto the front surface of the clavicle.

INSERTION A line along the tip, anterior border, and lateral surface of the mastoid process of the skull (behind the ear), continued around posteriorly into the lateral part of the superior nuchal line of the occipital bone at the base of the skull.

ACTION Both sides together flex the head and neck forward. Acting alone, it will bend the head and neck laterally and rotate the face toward the opposite side.

STRUCTURE The sternocleidomastoid (sternomastoid) is a wide, basically straplike muscle, thickest at its center, that spirals obliquely down the side of the cylindrical form of the neck. It passes from behind the ear toward the pit of the neck, and stands out prominently in action. The single belly consists of two heads, which when tensed can be seen separating into the thicker, more prominent, *fusiform* sternal head and the wider, *flattened*, straplike clavicular ("cleido") head. The sternal head can be seen from origin to insertion; the clavicular head is usually visible on the lower half of the neck only (the upper half of the clavicular head blends into the dominant sternal head).

The superior end of the muscle (the single belly made up of its two fused heads) becomes aponeurotic, especially posteriorly, before it inserts into the skull. Inferiorly, the sternal and clavicular heads are usually separated by a small triangular interval just above the medial expansion of the clavicle.

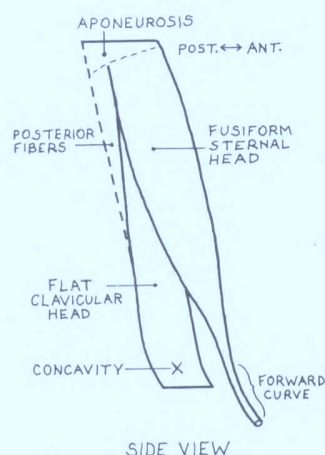
The **sternal head** tapers inferiorly into a strong tendon that appears round, conspicuous, and cordlike on the surface as it passes *medial* to the expanded medial end of the clavicle (not

in front of it). When the head (skull) faces forward, the inferior end of the sternal head curves slightly forward toward the sternum. When the head is completely rotated to one side, the sternal head becomes vertical and almost cylindrical in cross section, and forms the anterior profile of the neck. Along with the upper edge of the manubrium of the sternum, the tendons of the sternal heads of both sides of the body (not the medial ends of the clavicles) define the pit of the neck.

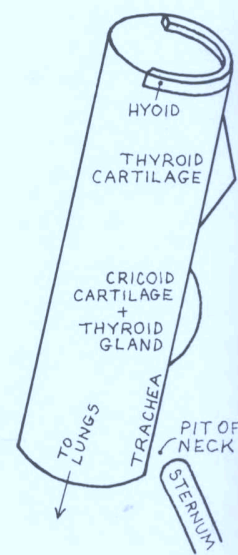
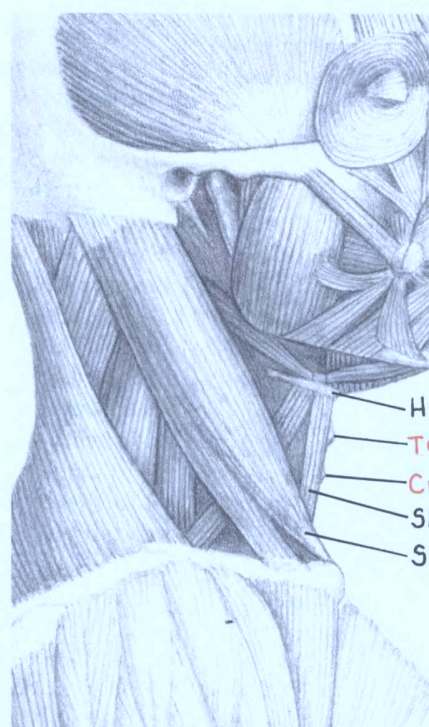
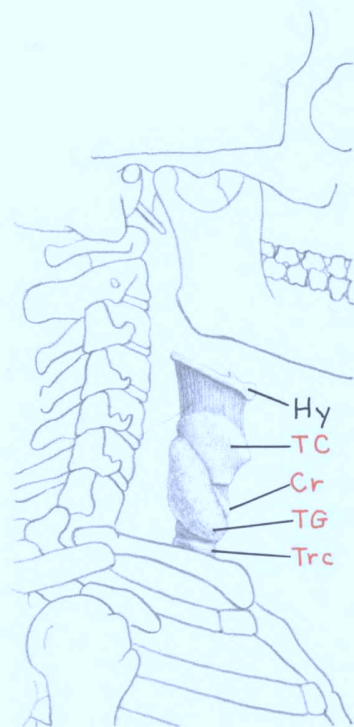
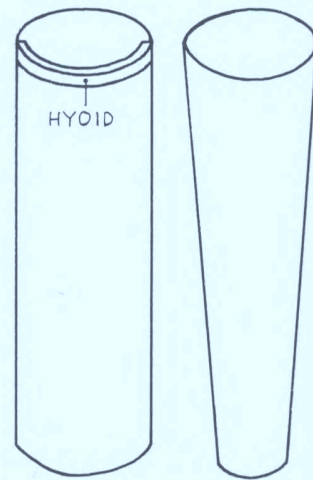
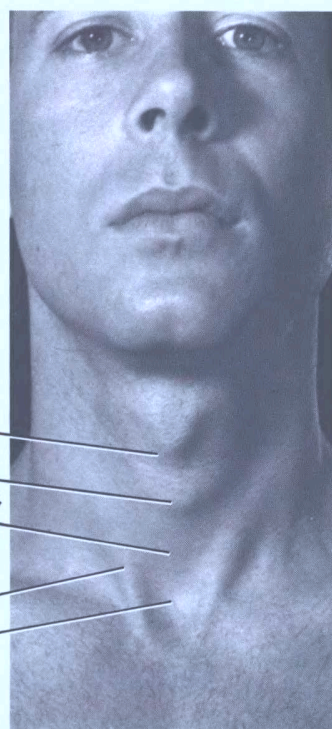
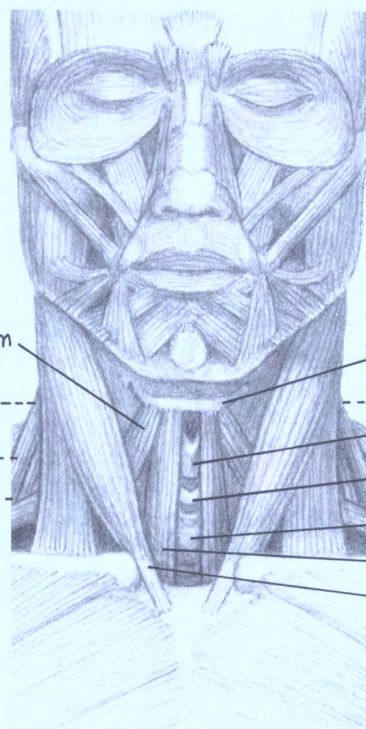
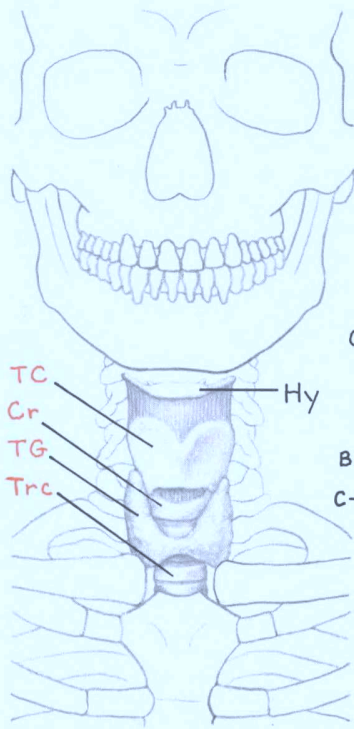
The inferior end of the **clavicular head** usually dips downward slightly before heading forward to the clavicle (creating a gentle concavity). The widened form of the clavicular head usually ends inferiorly at the top of the clavicle, leaving the form of the front of the clavicle visible. This head continues onward to the front surface of the clavicle, but only via its nonvisible flattened tendon. The upper half of the clavicular head normally becomes partially or completely covered by the sternal head as the two heads blend together.

The most posterior fibers of the clavicular head are usually inconspicuous, but when extremely tensed (head bent laterally against resistance), they become visible along their entire length, passing from the skull to the clavicle. They then appear as one or more independent narrow bundles descending from the aponeurosis at the very posterior end of the line of attachment on the skull to the lateral end of the line of attachment on the clavicle. The interval between the posterior edge of the sternocleidomastoid and the anterior edge of the trapezius then appears narrower.

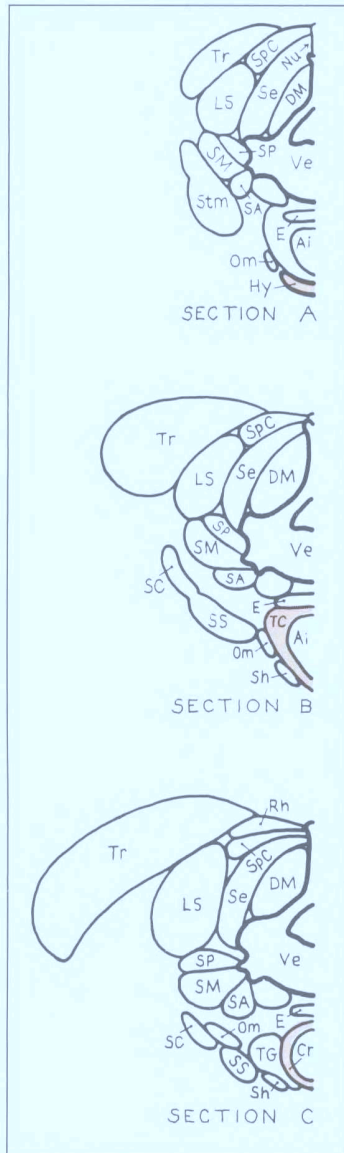
The sternocleidomastoids form the sides of the neck, converging as they advance anteriorly in their descent. When relaxed, the sternomastoids contribute to the cylindrical nature of the neck; when tensed, they become reliefs that rise up from the surface of the cylinder. The neck widens when it is extended, becoming widest two-thirds of the way down the sternocleidomastoids.



The Head and Neck Muscles • THROAT



Ai Air passage Cr Cricoid cartilage E Esophagus Hy Hyoid bone Om Omohyoid
 PN Pit of neck Sh Sternohyoid SS Sternomastoid—sternal head Stm Sternomastoid
 TC Thyroid cartilage TG Thyroid gland Trc Trachea Ve Vertebra



The *THROAT* is the windpipe, or breathing tube, and consists of the larynx and trachea. The thyroid gland contributes to its form.

The throat is basically a semirigid cylindrical structure, located on the front of the neck, which connects the mouth to the lungs. The upper front edge of the throat cylinder is formed by the U-shaped hyoid bone (the hyoid bone inconspicuously lies at the junction between the bottom plane of the jaw and the front of the throat cylinder). The throat cylinder is directed downward and backward into the chest cavity to the lungs, passing behind the manubrium of the sternum. The cylinder is relatively wide—almost half the width of the neck—and lies between the bellies of the sternomastoid muscles. Because the throat cylinder tapers inferiorly, and because its lower portion is partially covered on the sides by the sternomastoids, it appears on the surface to be an inverted cone. It is also covered on its front by the straplike infrahyoid muscles (sternohyoids, omohyoids, etc.), which contribute to its cylindrical form.

As a unit, the throat moves up when the head is extended or the tongue protruded, and down when the head is flexed. During swallowing, it is pulled up to, and then drops down from, the hyoid bone. The throat cylinder has two bumps on its anterior surface: the thyroid cartilage on its upper third and the combined cricoid cartilage and thyroid gland on its middle third (the form of the cricoid cartilage predominates in the male; in the female, the thyroid gland is often most prominent). The trachea accounts for the lower third of the cylinder, but is not seen directly as it is covered by the skin draped over the structures of the lower portion of the throat. What remains is a concave depression at the pit of the neck. In the male, the upper bump is larger than the lower one. In the adult female, both bumps are more or less equal in size; sometimes both are inconspicuous, forming a simple curve along the front profile of the neck. The bumps become more prominent when the head and neck are extended.

The **larynx**, or “voice box,” consists, in part,

of the thyroid cartilage, vocal cords, and cricoid cartilage.

The **thyroid cartilage** is the largest cartilage of the throat. Suspended by a membrane from the hyoid bone, it is shaped like the bow of a ship. Its two sides, or laminae, meet at a sharp angle to form its front edge (more acute and sharper in the male than in the female). In side view, the upper and lower portions of its front edge are cut back to produce a point on its anterior edge. The upper portion has an elongated V-shaped notch, which is easily palpated and often seen (especially in the extended head). The thyroid cartilage is larger and more prominent in the adult male than in the adult female, and is called the **Adam’s apple**.

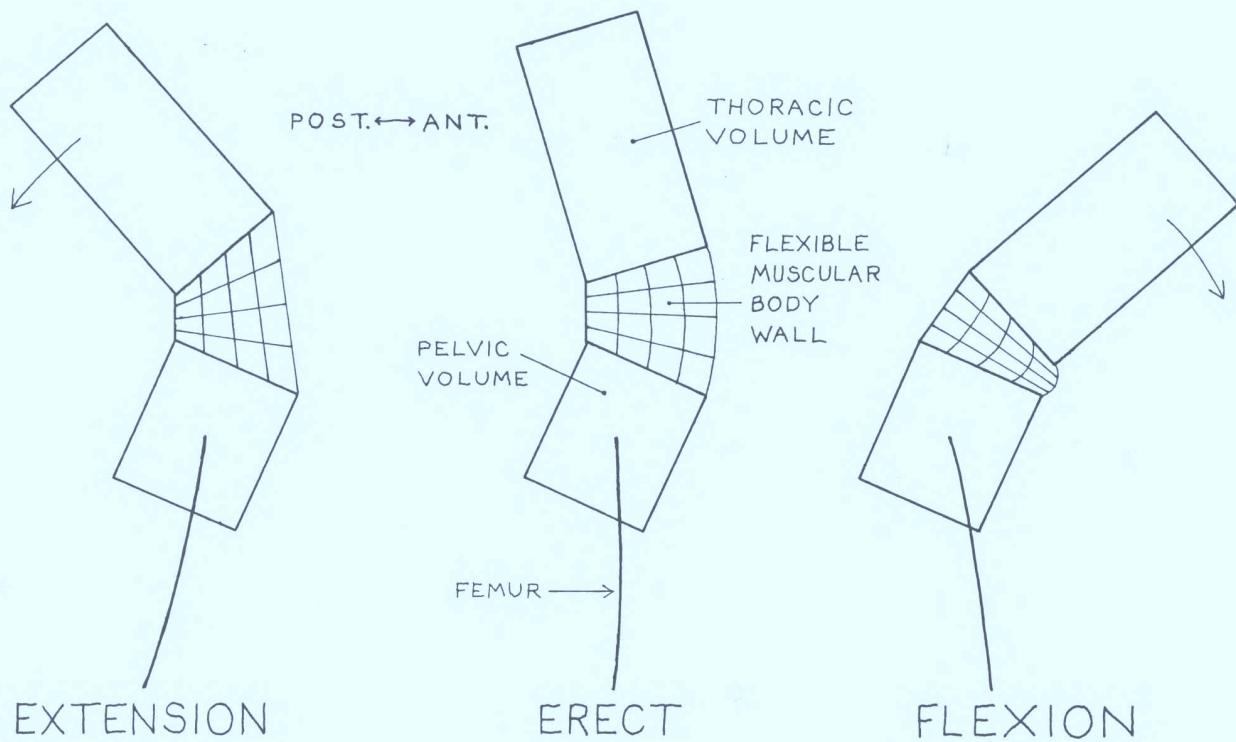
The **cricoid cartilage** is a cartilaginous ring located inferior to the considerably larger thyroid cartilage and superior to the narrower trachea. It has a wide U-shaped notch on the front of its upper edge, which registers as a subtle depression on the surface. The cricoid cartilage is subcutaneous and is visible in the male, where it creates the smaller, rounder, inferior bump on the front of the throat. In the female, its form is masked (although not covered) by the swelling of the larger thyroid gland.

The **thyroid gland** lies roughly at the level of the cricoid cartilage. It consists of a relatively large, oval lobe on each side of the throat (covered by the sternohyoids) connected in front by a narrow isthmus of gland across the upper portion of the trachea (over the second and third tracheal rings). The gland is visible in the adult female and in youth, where it creates the soft swelling of the inferior bump on the front of the neck, while concealing the cricoid cartilage. In men, the gland is usually inconspicuous.

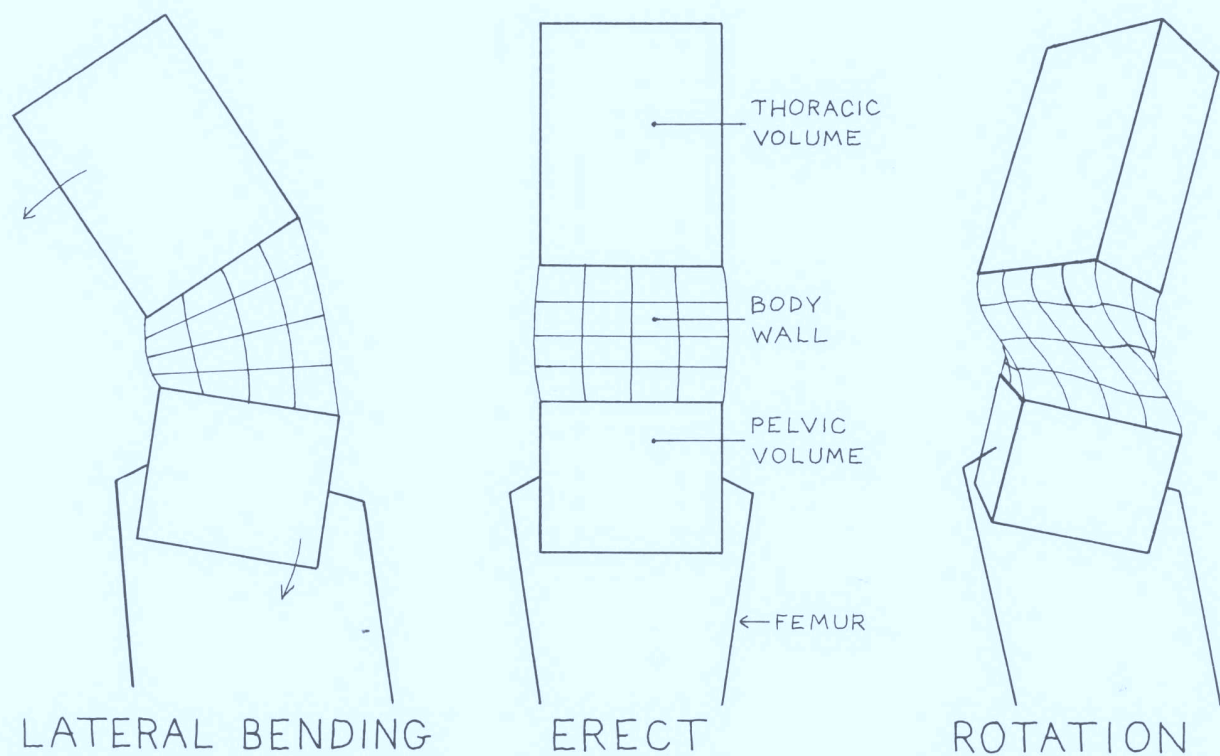
The **trachea**, beginning just below the cricoid cartilage, is the inferior component of the subcutaneous windpipe. It continues the form of the throat cylinder behind the sternum into the chest. Although its actual cylindrical form is concealed by the thyroid gland superiorly and the suprasternal fat inferiorly, it can easily be palpated. Its individual cartilaginous rings are not visible.

The Trunk Muscles

SIDE VIEW



FRONT VIEW



The Trunk Muscles

The region from the shoulders to the iliac lines is considered the trunk. The *TRUNK MUSCLES*, described on the following pages, for the most part lie on the trunk itself, although some cross the shoulder joint and the neck.

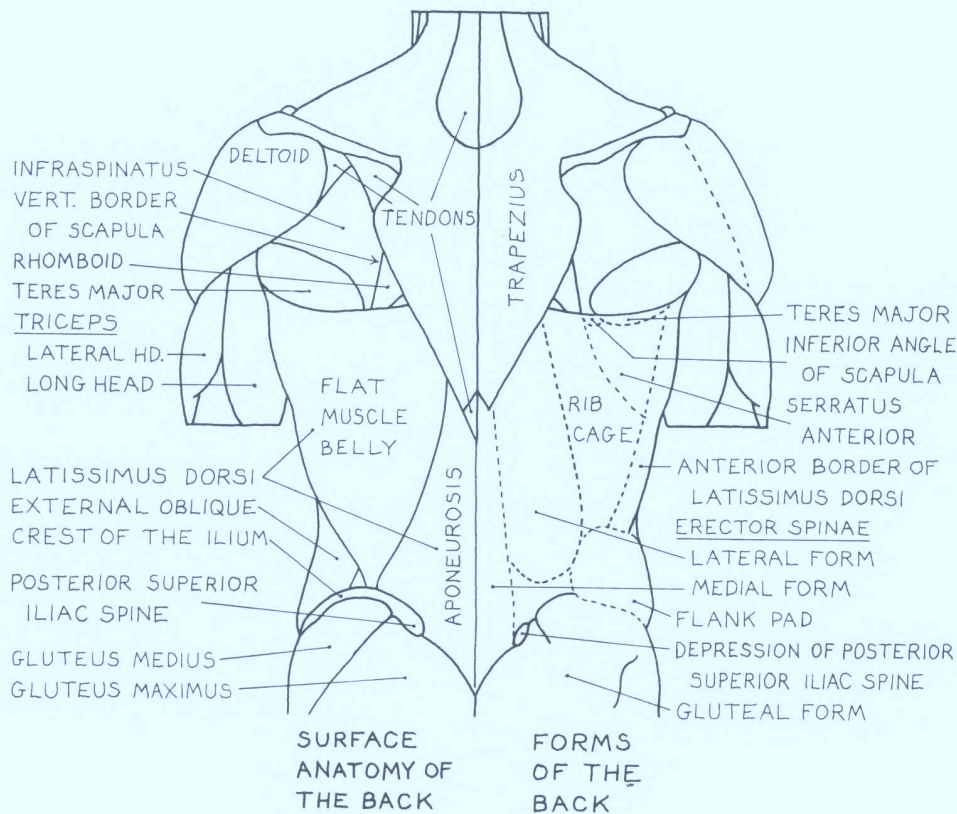
The shape of the trunk is largely determined by the rib cage, upon which the pyramidal shoulder apparatus of both sides—the bony shoulder girdles and their muscles—sit and glide. The trunk is flattened from front to back, noteworthy in the human figure because in quadruped mammals the torso is laterally compressed from side to side.

The rigid rib cage is separated from the pelvic region (the rigid upper margin of the pelvis) by the muscular body wall. These “rigid units” are independent of and often dynamically opposed

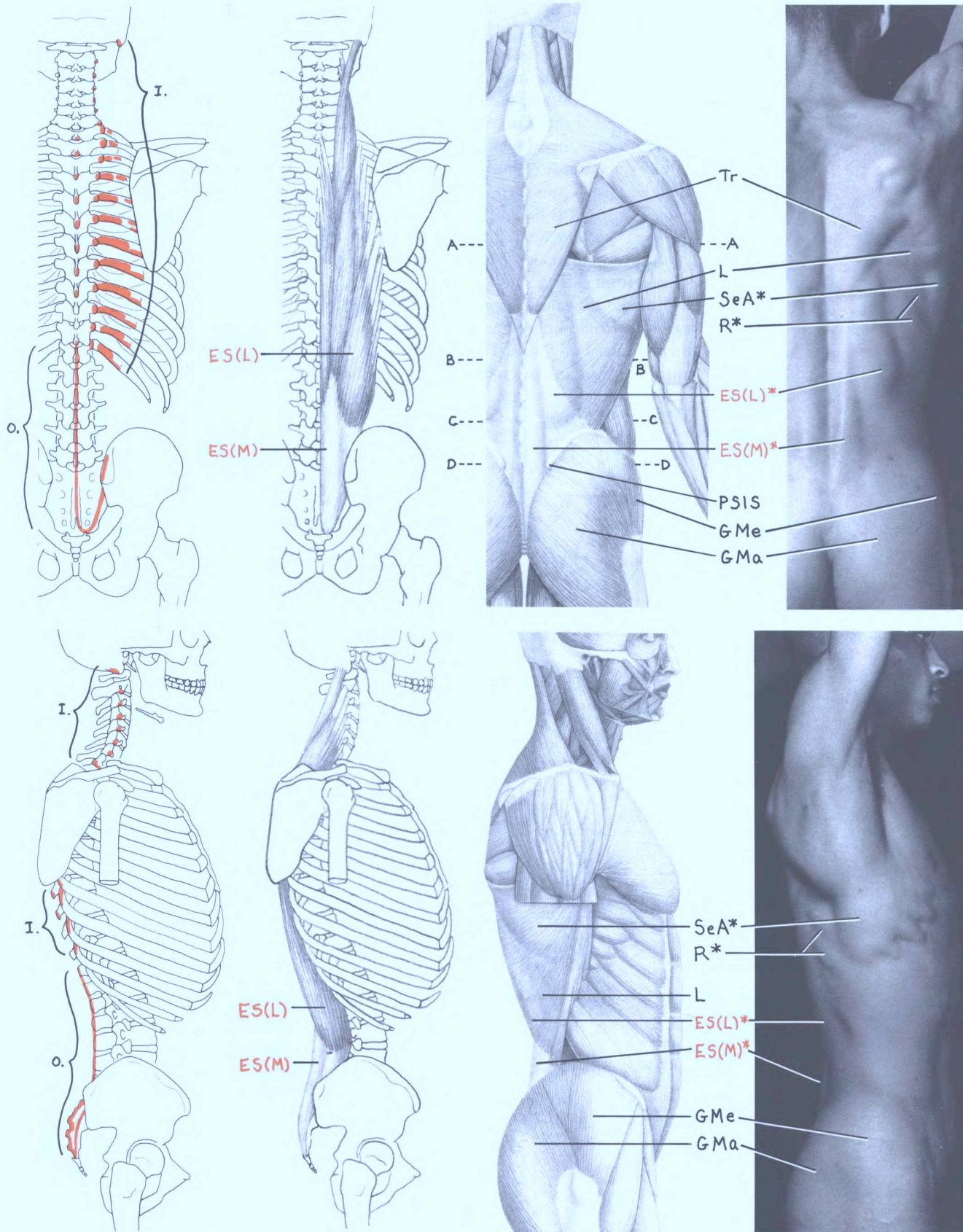
to each other. They are connected by the lumbar vertebrae in back, which allow, and also limit, the movements possible between them.

The irregularly shaped interval between the two bony regions (between the bottom of the rib cage and the top of the pelvis) is bridged by the thin, soft, **muscular body wall**, made up of the rectus abdominis and the external oblique (as well as other thin layers of deeper muscles). These muscles accommodate all the twisting and bending of the bony regions by stretching, contracting, folding, and bulging.

The trunk (including the shoulders) is easily visualized as a flattened box. The back of the trunk appears larger than the front, and can be visualized as an inferiorly pointed triangular wedge, especially in the male.



The Trunk Muscles • ERECTOR SPINAE



DM Deep muscle ES Erector spinae ES(L) Erector spinae—lateral form
 ES(M) Erector spinae—medial form FF Flank fat pad GMa Gluteus maximus GMe Gluteus medius
 I Ilium L Latissimus dorsi Mu Multifidus PSIS Posterior superior iliac spine
 QL Quadratus lumborum R Ribs Sac Sacrum SeA Serratus anterior Tr Trapezius Ve Vertebra
 * Under latissimus dorsi

Erector Spinae (Sacrospinalis)

ORIGIN A continuous line which begins on the inner surface of the posterior third of the iliac crest, passes down the lateral *crest* of the sacrum (not the lateral edge), curves around to and then up the median crest of the sacrum (on the midline), and continues straight up the tips of the spinous processes and supraspinal ligament of the lumbar and lower two thoracic vertebrae. (There are additional deep sites of origin further up the back.)

INSERTION By many muscular slips into numerous points on the backs of all twelve ribs, between the *angles of the ribs laterally* and the *tubercles of the ribs medially*; into the spinous and/or transverse processes of all the thoracic and cervical vertebrae; and into the mastoid process of the skull.

ACTION Extends the vertebral column and the head. Portions of the erector spinae assist in rotation and lateral flexion of the vertebral column.

STRUCTURE The erector spinae, or **sacrospinalis** consists of several combined muscles which form a thick, elongated muscle mass on the back to the side of the spinous processes of the vertebral column. It extends from the sacrum to the base of the skull. It is thickest in the lumbar and cervical regions, and thinner and wider in the thoracic region. In the thoracic region, it widens out to, but not past, the angles of the ribs. At about the level of the bottom of the scapula, its form becomes less distinct as it thins and passes upward under the rhomboids and the trapezius.

In the side view of the body, the back profile of the muscle creates a transition between the *down plane* of the back of the thorax and the *up plane* of the back of the sacrum. The back profile usually appears as a series of two convexities, as the erector spinae separates into medial and lateral forms (see below). The lumbar portion of the erector spinae forms a powerful and prominent muscular column on each side of the spine in the lower back, referred to as the **strong cords** or the **common mass**.

The erector spinae is simple and tendinous at its origin. As it ascends, it divides into several muscles which split into numerous bundles; new fibers arise as lower fibers insert. The separate muscles and bundles are occasionally seen on the surface—usually momentarily during motion.

When the figure is standing erect, and the erector spinae is relaxed, the muscle appears as a *single wide muscular form* on either side of the median spinal furrow (the depressed ridge

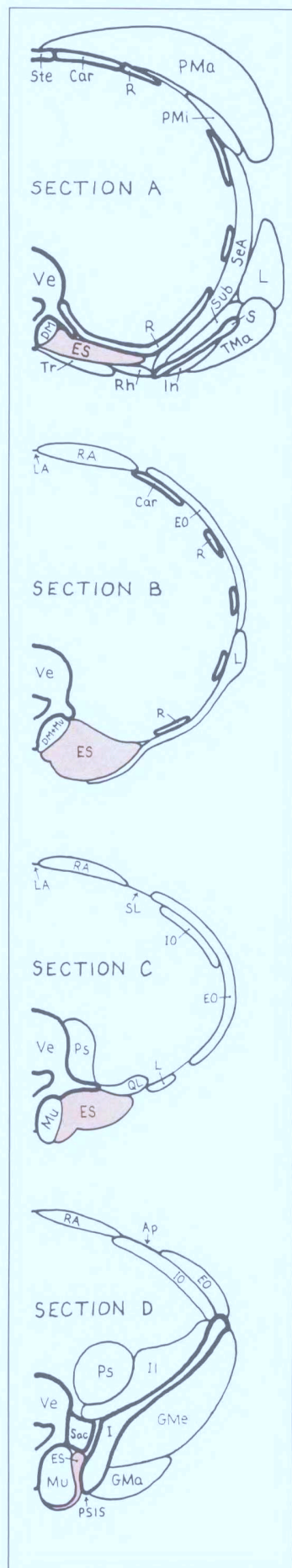
of the spinous processes). As the thorax flexes forward at the waist, the muscle immediately tenses and hardens, and the cylindrical form of *each side* divides into *two* forms—a narrow, lower, vertical medial form and a wider, higher, oblique lateral form.

The **medial form** is made of the multifidus muscle inferiorly (lying under the tendon of the erector spinae) and part of the belly of the erector spinae superiorly. This form begins mid-sacrum, slightly below the level of the posterior superior iliac spine, and ends superiorly just below the lower tip of the trapezius. It lies between the spinous processes of the lumbar vertebrae and the depression (or bump) of the posterior superior iliac spine. The inferior end of the medial form widens slightly on the posterior surface of the sacrum.

The **lateral form** begins inferiorly at the level of the top of the crest of the ilium and disappears superiorly at the level of the bottom of the scapula, where it thins out and passes under the trapezius (it is occasionally seen higher, bulging under the trapezius). This form is oblique, being directed upward and slightly medially. It is made up of fleshy muscle fibers of the erector spinae. The lateral form is usually wider inferiorly (the portion of the belly between the rib cage and the pelvis bulges laterally because of the fullness of the muscle). It narrows superiorly (its lateral edge shifts medially) as the ascending muscle bundles along its lateral side thin into nonvisible tendons. The tendons continue to insert out to the angles of the ribs, but the visible form does not extend that far laterally. The lower end of the lateral form is created where its fleshy fibers attach into its wide tendon of origin.

As the trunk reaches full flexion (flexing at the vertebral column, not at the hip joints), the erector spinae is pulled relatively thin and flat, and the spinous processes of the lumbar and sacral vertebrae, as well as the posterior superior iliac spines, begin to project. When the figure is erect, the vertical median furrow of the back (at the bottom of which lie the vertebral spinous processes) ends inferiorly halfway down the sacrum.

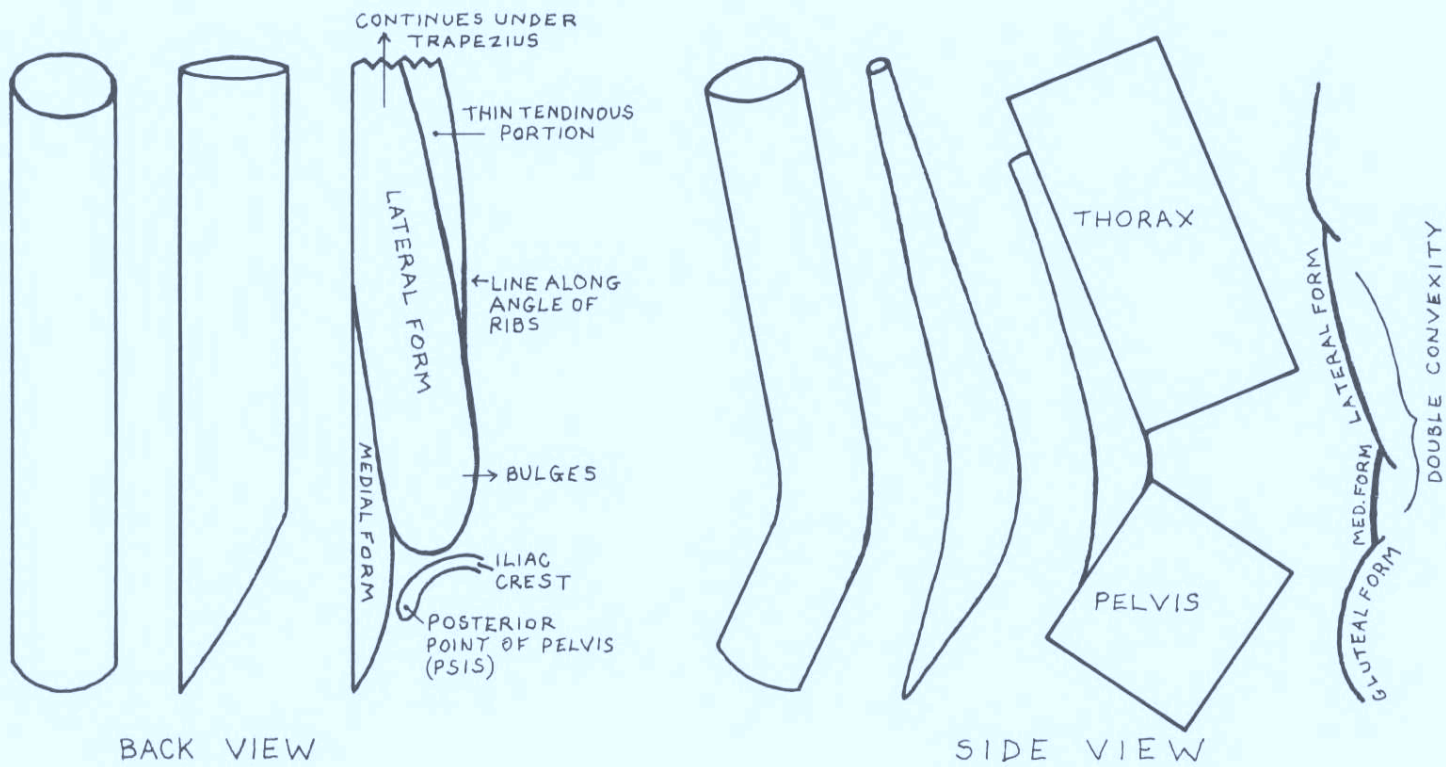
The latissimus dorsi may confuse the shape of the erector spinae in two ways. First, if the erector spinae is relaxed when the latissimus dorsi is tensed, the latissimus pulls on its wide, sheetlike tendon of origin (also called the thoracolumbar fascia), which lies on the surface of the erector spinae. This pulling causes ridges or furrows to develop across the long axis of the soft erector spinae. These ridges are in line with the direction of the muscle fibers of the latissimus, and are therefore almost horizontal superiorly and more oblique inferiorly. Second, when



The Trunk Muscles • ERECTOR SPINAE

the latissimus is tensed, the line of attachment of its muscle fibers into its wide tendon of origin occasionally becomes visible—its muscle fibers are in slight raised relief where they meet the tendon. This visible diagonal line, either curved or straight, sits *on top of the lateral*

form of the erector spinae. It is located lateral to the oblique line which separates the erector spinae into its medial and lateral forms. The latissimus line appears only when the latissimus dorsi is tensed, regardless of whether the erector spinae is relaxed or contracted.



The Trunk Muscles • MULTIFIDUS

Multifidus (Multifidi)

ORIGIN The medial half of the posterior surface of the sacrum, the inner aspect of the posterior superior iliac spine, the posterior sacroiliac ligaments, and various points on the back of the lateral processes of all the vertebrae except the first three cervical vertebrae.

INSERTION The spinous processes of all the vertebrae, except the atlas.

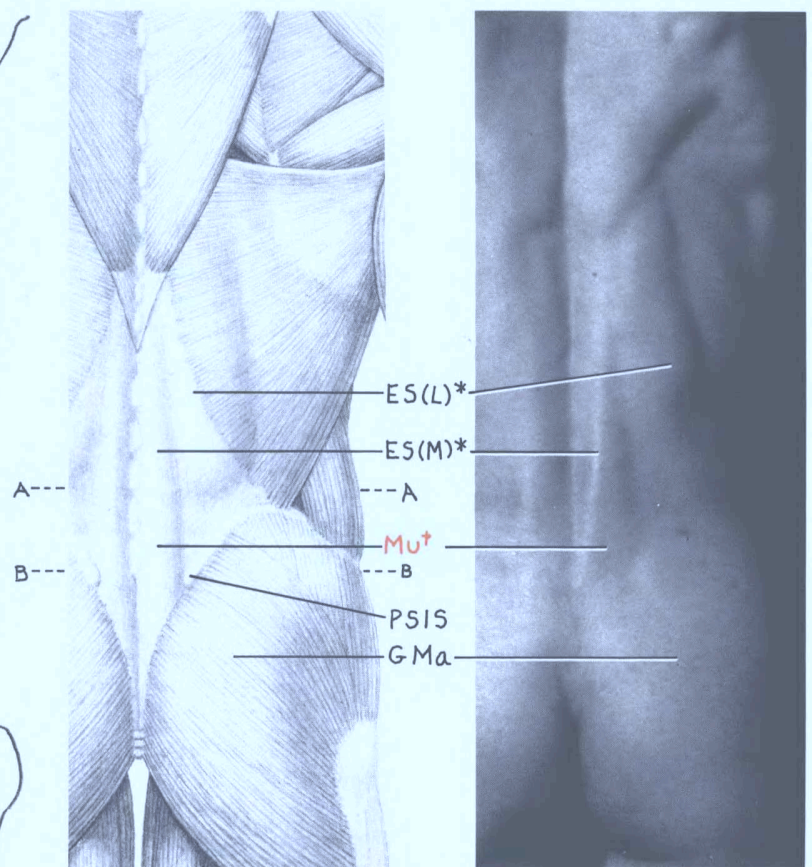
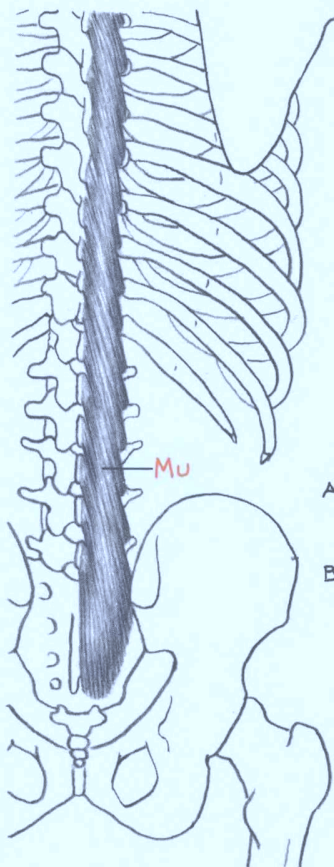
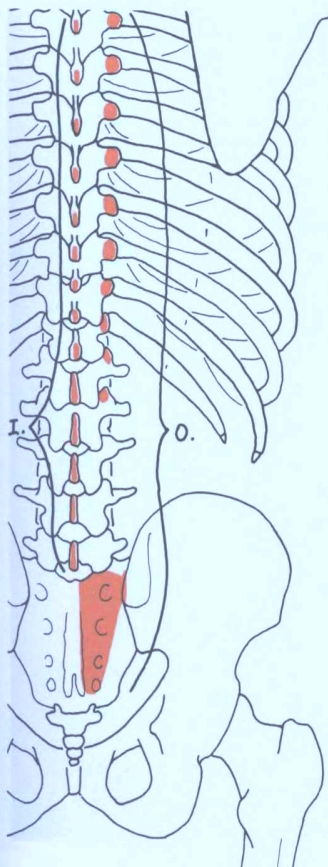
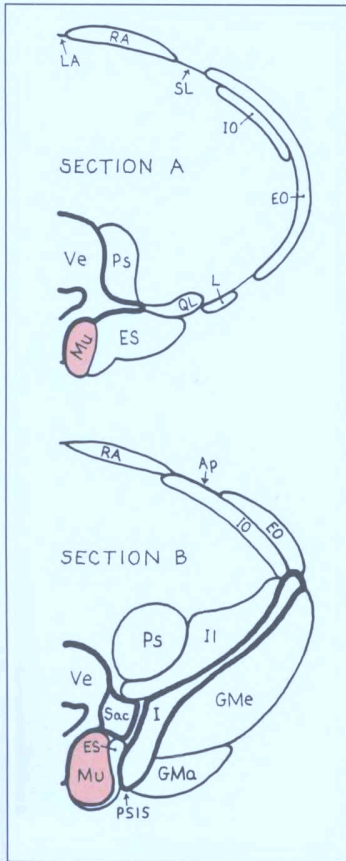
ACTION Extends, laterally flexes, and rotates the vertebral column.

STRUCTURE The multifidus (multifidi) lies deep to the erector spinae. It fills the bony groove on both sides of the spinous processes of the vertebrae along the *entire* vertebral column. It consists of numerous short bundles passing obliquely upward and medially. They variously

cross over two to five vertebrae at a time, depending on their length, to insert into a higher vertebra.

The upper portion of the muscle is deep to the other spinal muscles. It progressively becomes thicker and wider as it descends. Inferiorly, it is covered only by the tendon of the erector spinae in the lower lumbar and sacral region. The gluteus maximus originates in part from the surface of the lateral portion of this tendon. The multifidus therefore directly creates surface form in the lower lumbar and sacral areas.

When the back muscles are tensed, the multifidus creates the lower portion of the narrow vertical form that lies immediately on either side of the spinous processes of the sacrum and lumbar vertebrae.

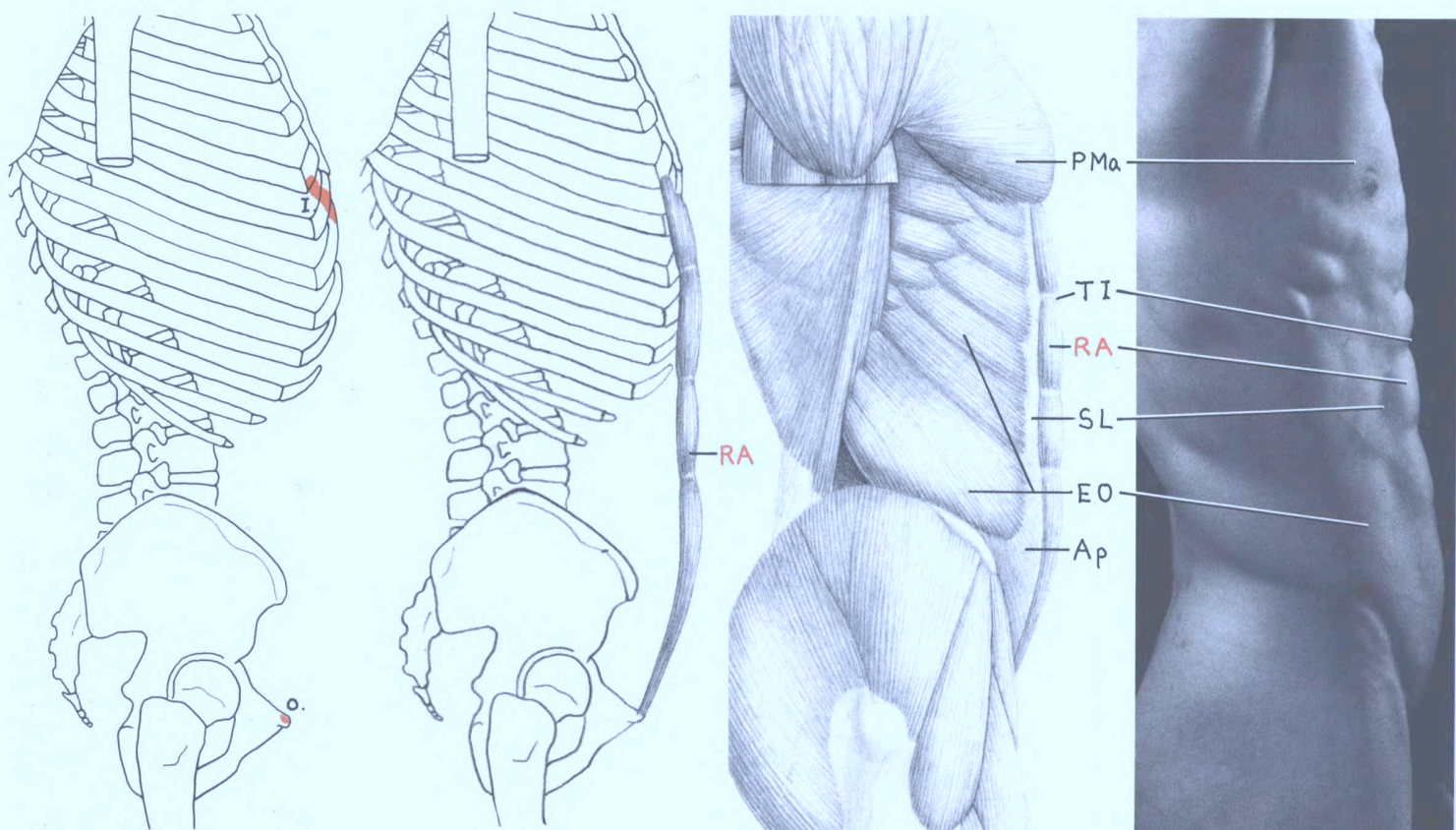
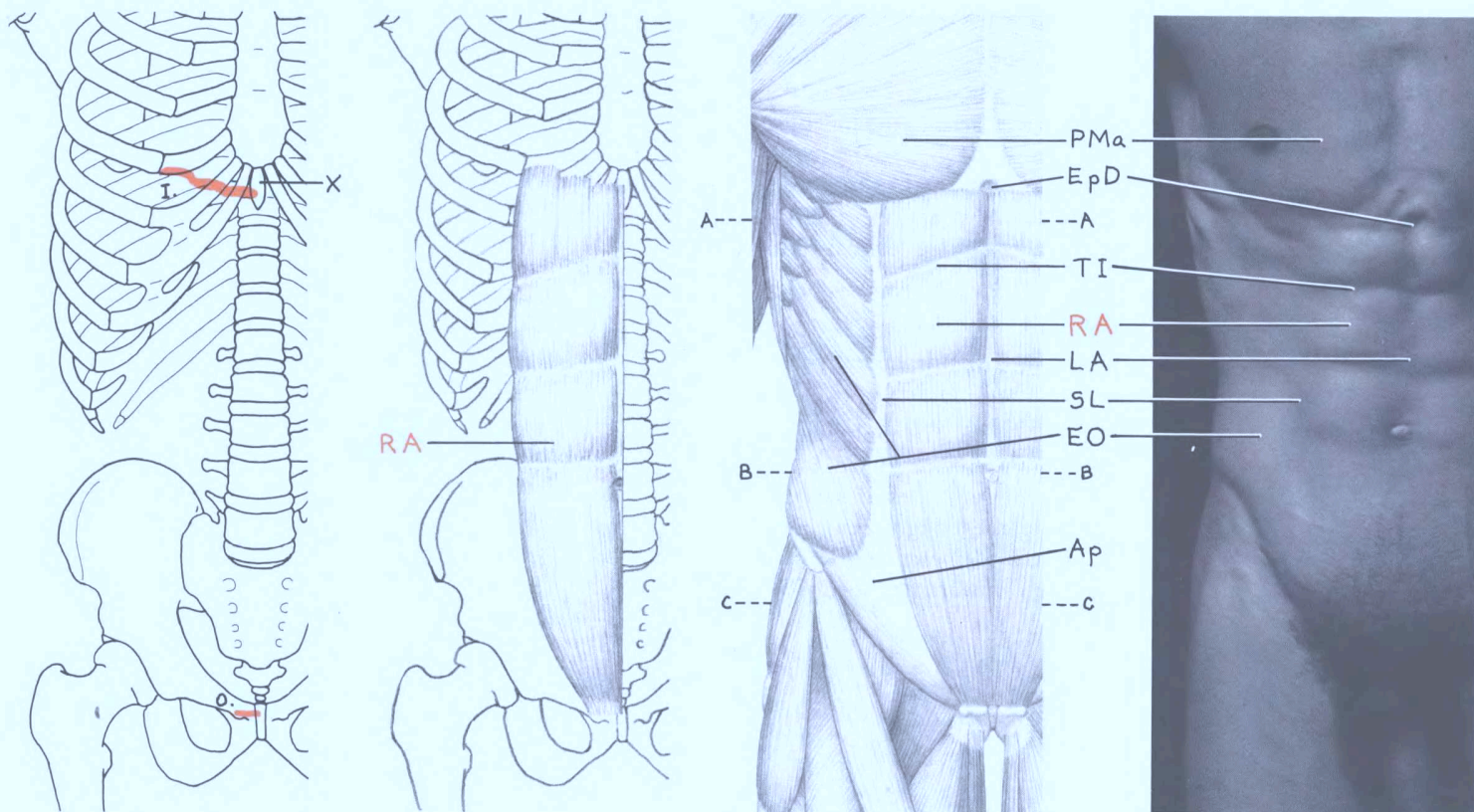


ES Erector spinae ES(L) Erector spinae—lateral form ES(M) Erector spinae—medial form

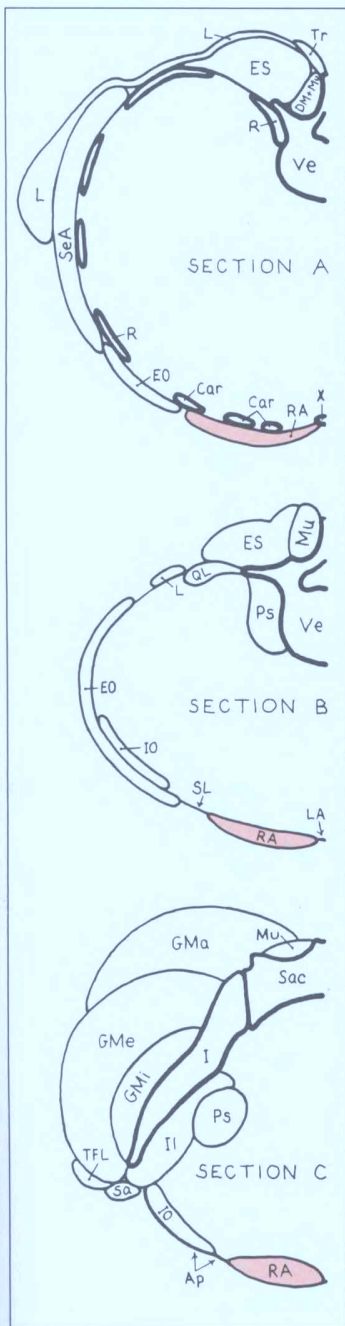
GMa Gluteus maximus Mu Multifidus PSIS Posterior superior iliac spine Sac Sacrum Ve Vertebra

* Under latissimus dorsi † Under erector spinae

The Trunk Muscles • RECTUS ABDOMINIS



Ap Aponeurosis Car Cartilage EO External oblique EpD Epigastric depression IO Internal oblique
 LA Linea alba PMa Pectoralis major RA Rectus abdominis SL Semilunar line
 TI Tendinous intersection X Xiphoid process



Rectus Abdominis

ORIGIN Pubic crest of the pubic bone (a short horizontal line at the top of the pubic symphysis) and from ligaments on the front of the pubic symphysis.

INSERTION Anterior surfaces of the costal cartilages of the fifth, sixth, and seventh ribs and the anterior surface of the xiphoid process.

ACTION Flexes the trunk at the lumbar vertebrae.

STRUCTURE The rectus abdominis is a long, flat, vertical muscle on the front of the abdomen. It is wide and thin above and tapers below. The muscles of each side of the body meet at the midline at a tendinous vertical line, the **linea alba** (white line), which extends from the xiphoid process to the pubis. The linea alba appears as a vertical furrow between the two bellies, gradually disappearing below the navel. The navel is variably situated halfway to two-thirds of the way down this line. During lateral trunk flexion, only the portion of the linea alba above the navel curves laterally (corresponding to the curving lumbar vertebrae in back).

The lateral edge of the rectus abdominis is separated from the fibers of the external oblique by a tendinous furrow called the **semilunar line**. It is located *medial* to a line dropped from the nipple (or straight down from mid-clavicle) which is directed downward toward the *middle* of the thigh (in the anatomical position). The semilunar line begins just below the lower border of pectoralis major (on the surface of the rib cage, where it is faint) and continues downward beyond the rib cage, where it is more pronounced. Inferiorly, at the level of the navel, the semilunar line begins to widen into a tendinous triangular expansion.

Usually, three fibrous bands, the **tendinous intersections**, are situated in the muscle and inscribe transverse furrows across the belly. They do not necessarily pass straight across both rectus abdominis muscles, but are sometimes located at different levels on each side, giving the abdomen an asymmetrical appearance. An individual intersection may be either straight or zigzag. Classically, the lowest tendinous intersection is horizontal and is located at, or slightly above, the level of the navel. The highest is diagonal and is directed *approximately* from the tip of the xiphoid process to the point where the semilunar line crosses the ninth costal cartilage. The middle tendinous intersection is located at or above the level of the waist, and its degree of obliquity is midway between the other two. Occasionally a fourth tendinous intersection is found below the navel, but is not always seen. The obliquity of the intersections is highly variable, and they may all be horizontal.

The three tendinous intersections divide the rectus abdominis into four fleshy, muscular **segments**. The superior segment is continued upward over the costal cartilage on the front of the rib cage and is the least conspicuous of the four. Its upper edge usually coincides with the lower border of the pectoralis major; therefore, this segment ends before reaching the bottom of the sternum, leaving the infrasternal notch (epigastric depression) exposed. It may end higher, continuing under the pectoralis, or lower, exposing costal cartilage. Sometimes this segment divides into three vertical bundles of unequal length, progressively becoming longer and inserting higher laterally. The overall plane of the upper segment is directed slightly upward. The medial bundle of this segment attaches into the seventh cartilage; the middle bundle, into the sixth; and the lateral bundle, into the fifth cartilage and its bony rib. The lowest segment—long and tapering inferiorly—bulges the most. This segment is part of the pelvic volume, and the segments of the two sides of the body are usually not separated by the linea alba. The corners of all the segments are slightly rounded.

The **rounded abdominal** or **Greek arch**, as configured in classical Greek sculpture, is complicated, and is composed of several structures—cartilage, muscle belly, and tendinous intersection. It begins laterally and inferiorly at the costal cartilages of the ribs (from the tenth rib) and continues up and over *through the uppermost tendinous intersection* of the rectus abdominis. The upper most fleshy segments of the rectus abdominis of both sides bulge above the tendinous intersection and fill the sharp, angular summit between the two sides of the upper ends of the costal cartilages, where they meet the lower end of the sternum at an angle of 90° (more acute in the female). The tip of the xiphoid process projects forward, pushing muscle and tendinous intersection anteriorly, which also helps to round off the abdominal arch. Since the rectus abdominis muscle belly crosses *over* the costal cartilage, in muscular individuals the entire form of the upper segment may predominate and be seen as a distinct fleshy bulge, whereas in thin individuals the form of the underlying costal cartilage may predominate.

The two “arches” to look for at the front of the rib cage are the **rounded** Greek arch, produced by the rectus abdominis muscle and its uppermost tendinous intersection, or the **sharp** skeletal arch, produced by the costal cartilages meeting the bottom of the sternum just above the pit of the stomach. The sharp skeletal arch often predominates in the female, while the rounded Greek arch usually predominates in the male.

Faint oblique ridges on the surface of the rec-

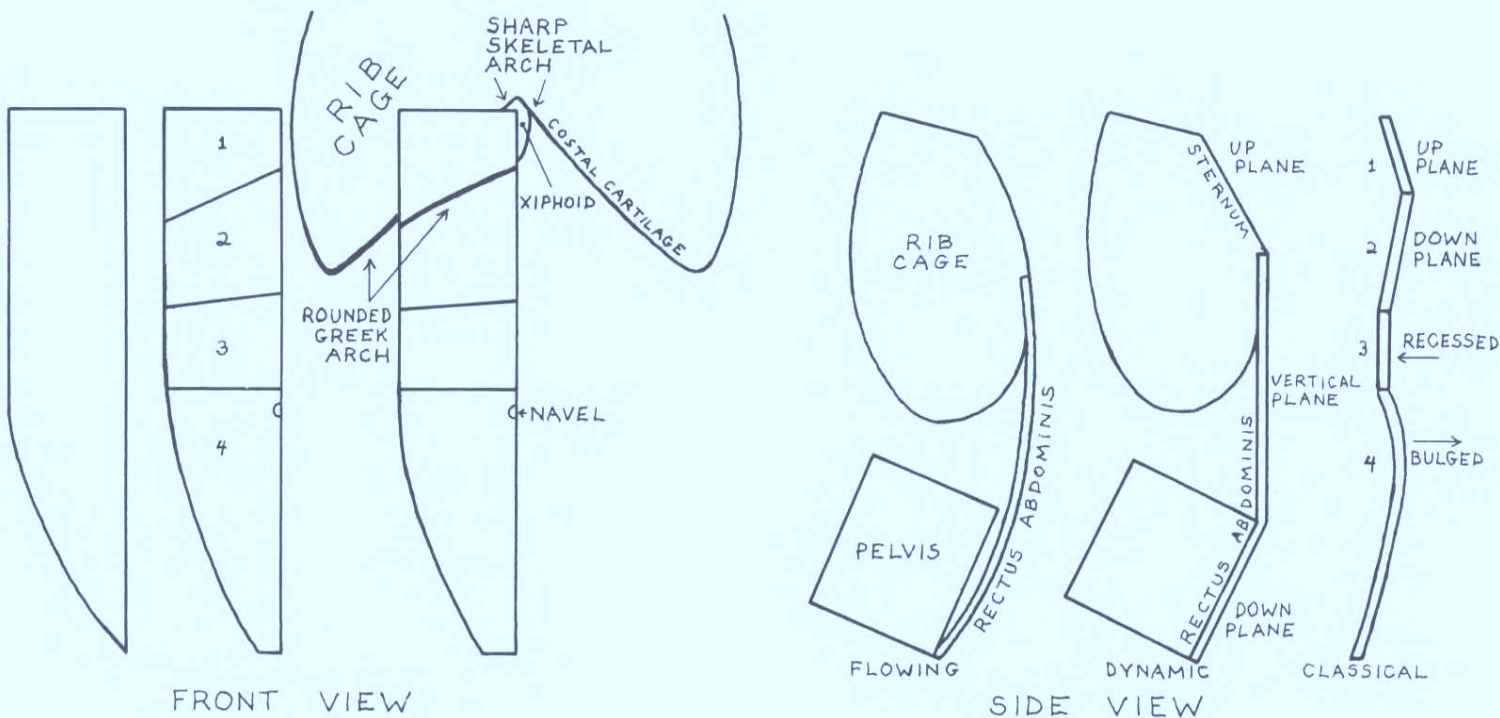
The Trunk Muscles • RECTUS ABDOMINIS

tus abdominis, especially at its upper end, are occasionally created when the pectoralis major and external oblique contract and pull on the thin abdominal aponeurosis that covers the rectus abdominis. These ridges are in line with the direction of the fibers of the pectoralis and external oblique; the fibers of the rectus abdominis are vertical.

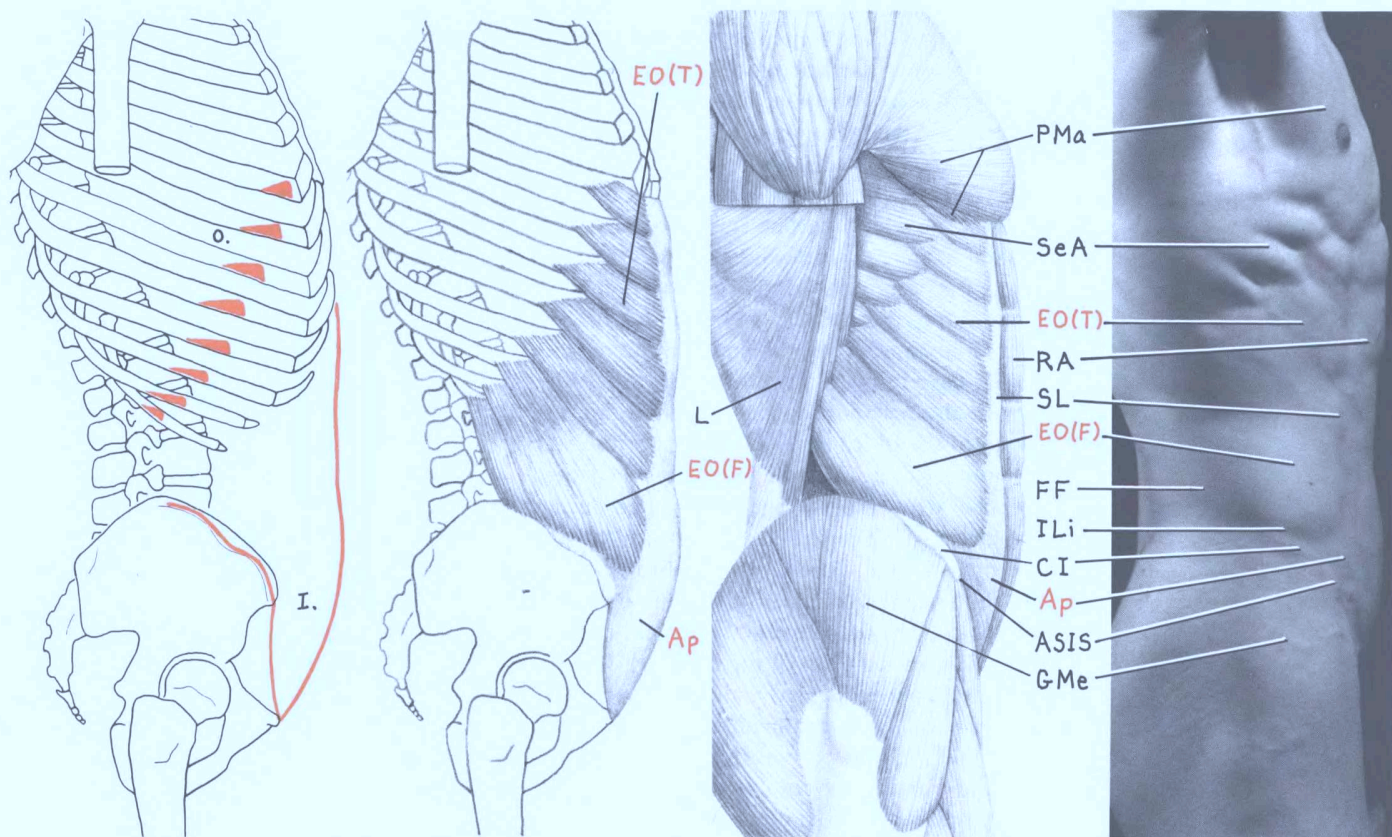
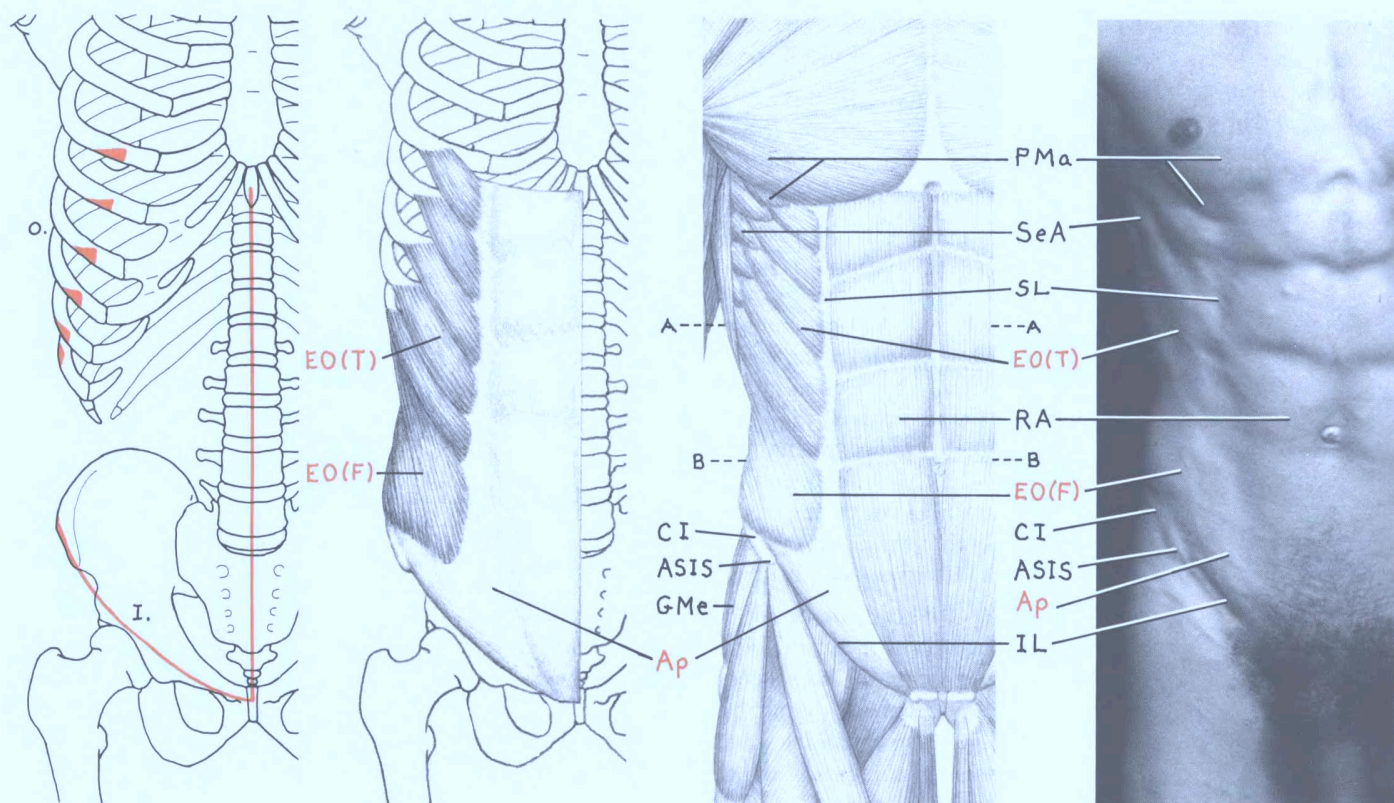
During forward trunk flexion, the muscle fibers shorten and the tendinous intersections

move closer together. Two horizontal skin folds, seen at or above the level of the navel, separate the thoracic and pelvic masses. Laterally, these skin folds end at or just beyond the semilunar line, which remains visible.

When inhaling, the diaphragm pushes the abdominal contents downward, causing the rectus abdominis to protrude. When the trunk is flexed forward, the belly (and the rectus abdominis) bulges below the level of the navel.

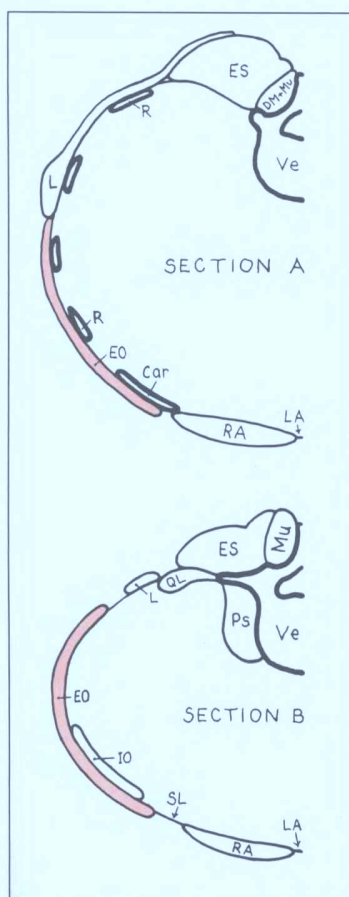


The Trunk Muscles • EXTERNAL OBLIQUE



Ap Aponeurosis ASIS Anterior superior iliac spine Car Cartilage CI Crest of ilium
 EO External oblique EO(F) External oblique—flank portion EO(T) External oblique—thoracic portion
 FF Flank fat pad GMe Gluteus medius IL Inguinal ligament ILi Iliac line IO Internal oblique
 L Latissimus dorsi PMA Pectoralis major R Rib RA Rectus abdominis SeA Serratus anterior
 SL Semilunar line

The Trunk Muscles • EXTERNAL OBLIQUE



pad posteriorly—has a high curved arc. The iliac line has a subtle, elongated S curve. It intersects with the iliac crest at a point one-third of the way back on the crest (at the widest point of the pelvis). The actual overlap of the posterior portion of the flank pad, past the iliac crest and onto the surface of the gluteus medius, consists of fat and skin. The overlap increases when the thorax is bent laterally toward that side (the iliac line descends), as the extra skin accumulates. When bent to the other side, the iliac line and the overlap of the flank pad eventually completely disappear as they are stretched, which can expose almost the entire iliac crest. When the trunk is flexed forward, the posterior part of the iliac line disappears.

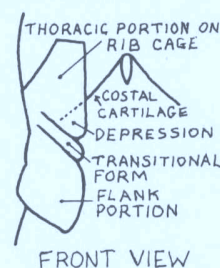
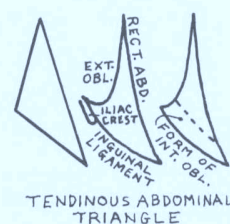
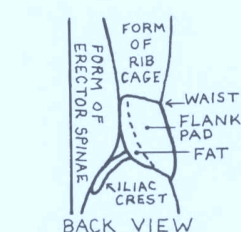
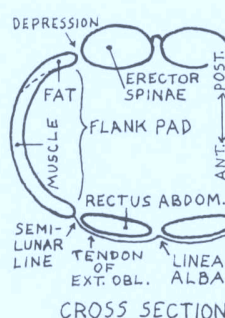
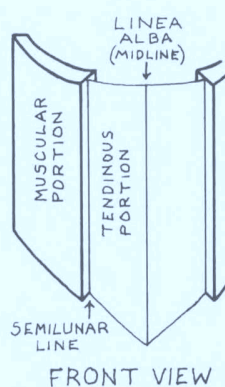
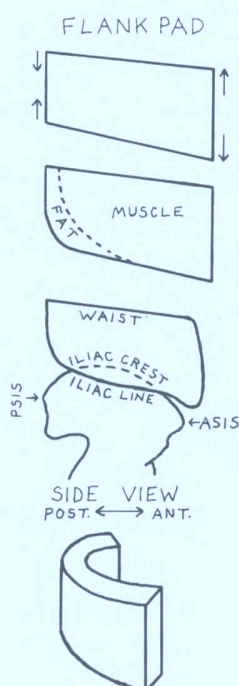
The **semilunar line** is the tendinous furrow located on the front of the abdomen between the rectus abdominis and external oblique. Inferiorly, at the level of the navel, it begins to expand into a triangular tendinous area whose surface bulges outward because of the abdominal contents deep to it. Part of the deep **internal oblique muscle** lies directly beneath this tendinous expansion, occasionally producing a narrow, oblique relief form beneath it, directed downward and medially (immediately above and parallel to the inguinal ligament).

The muscle fibers of the external oblique that

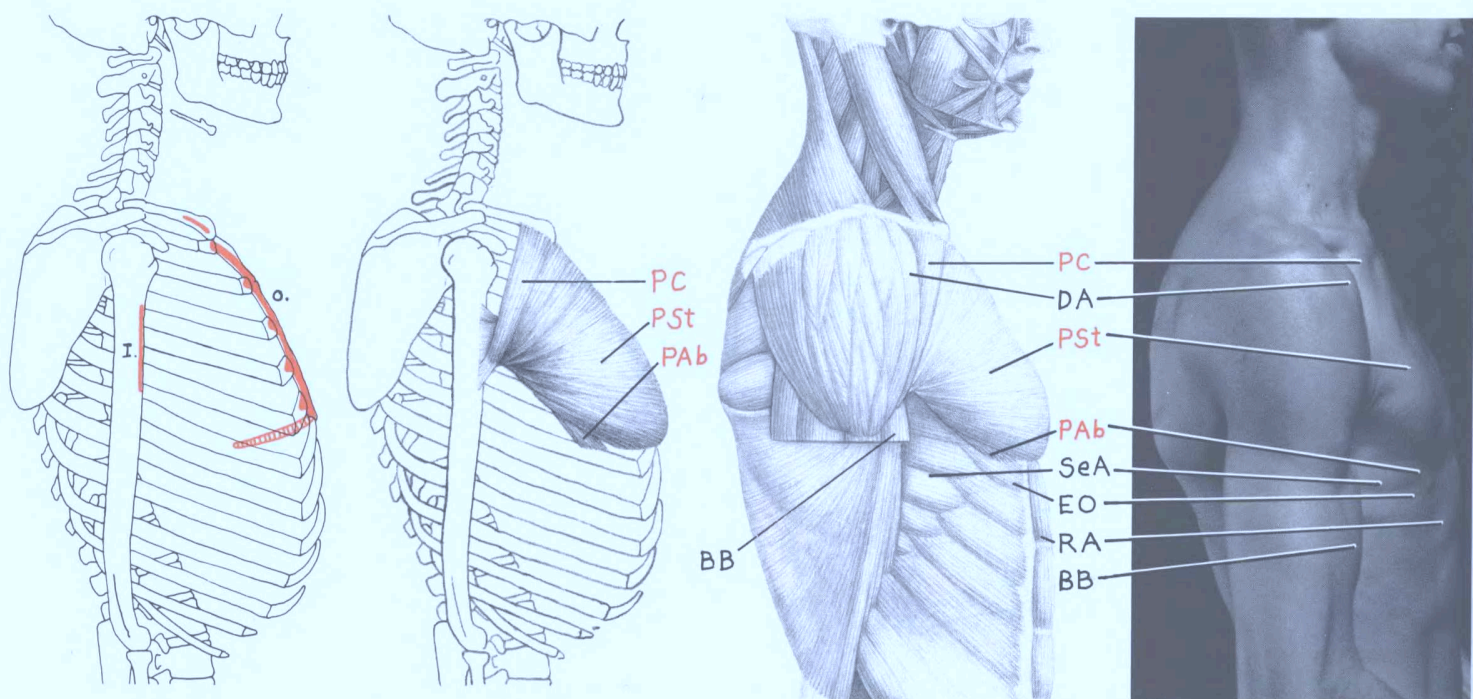
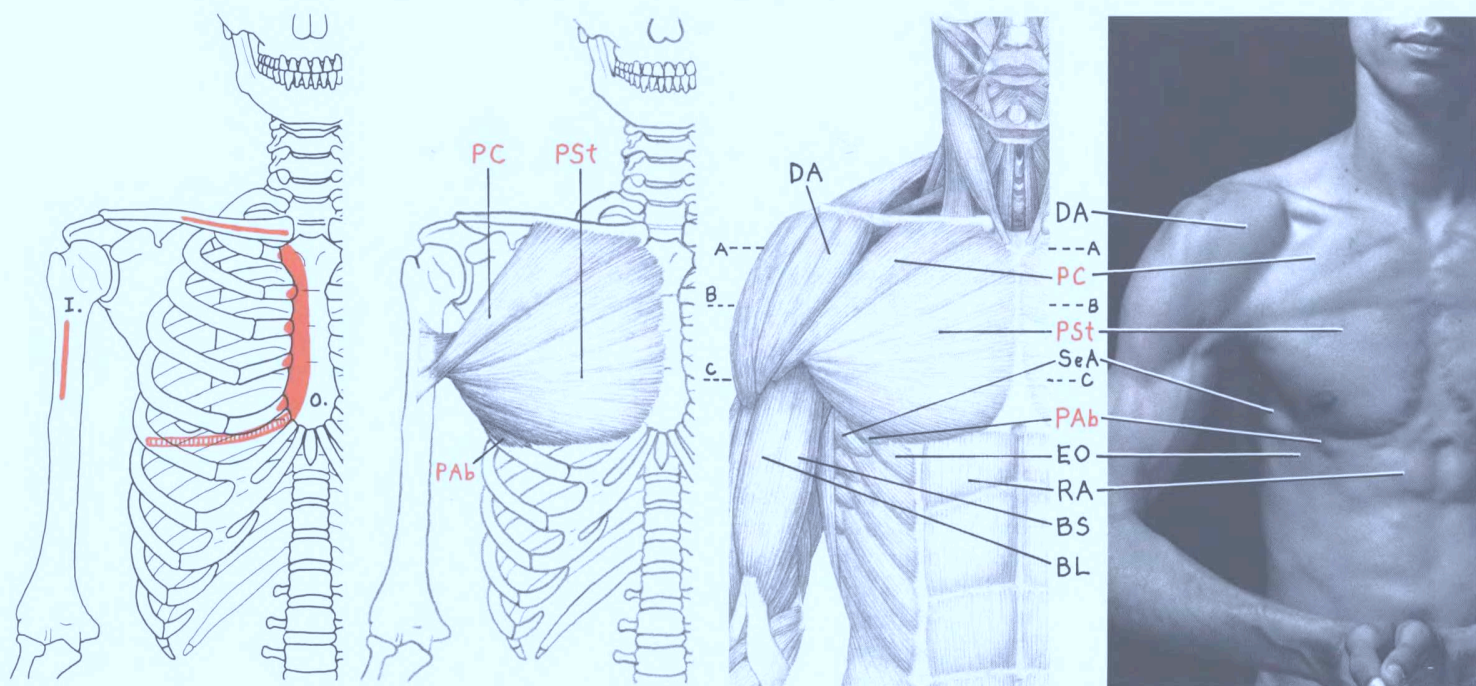
insert into its aponeurosis do so via separate bundles, which often creates a jagged, irregular line (the lateral edge of the rectus abdominis is smooth).

A triangular depression may occur in the portion of the external oblique belly immediately below the costal cartilage—just lateral to the semilunar line and just above the front portion of the flank pad. In this case, the costal cartilage becomes prominent.

The **inguinal ligament** (Poupart's ligament) is the thickened lower border of the aponeurosis of the external oblique (it is not a separate structure). It is attached laterally to the *inside* of the anterior superior iliac spine and medially to the pubic tubercle, near the midline. It forms either a curved or straight line, marking the separation between the abdomen and thigh. It straightens and deepens when the thigh is flexed. When seen in the female (where it is usually very faint), the inguinal ligaments of both sides form a wider V than in the male. This is because in the female the level of the anterior superior iliac spines is closer to the level of the pubis, and the two anterior superior iliac spines are relatively farther apart (the female pelvis is shorter and wider than the male pelvis).



The Trunk Muscles • PECTORALIS MAJOR



BB Biceps brachii BL Biceps brachii—long head BS Biceps brachii—short head Car Cartilage
D Deltoid DA Deltoid—anterior portion EO External oblique H Humerus Mn Manubrium
PAb Pectoralis—abdominal portion PC Pectoralis—clavicular portion PMa Pectoralis major
PMi Pectoralis minor PSt Pectoralis—sternocostal portion R Rib RA Rectus abdominis
SeA Serratus anterior Ste Sternum

The Trunk Muscles • PECTORALIS MAJOR

Pectoralis Major

ORIGIN The anterior surface of the medial half of the clavicle, the entire length of the anterior surface of the sternum toward its lateral edge (not from the xiphoid process), the cartilages of the first six or seven ribs, and the upper end of the aponeurosis of the external oblique muscle (abdominal aponeurosis) lying on the top of the rectus abdominis muscle.

INSERTION Lateral lip of the intertubercular sulcus (bicipital groove) on the front of the humerus.

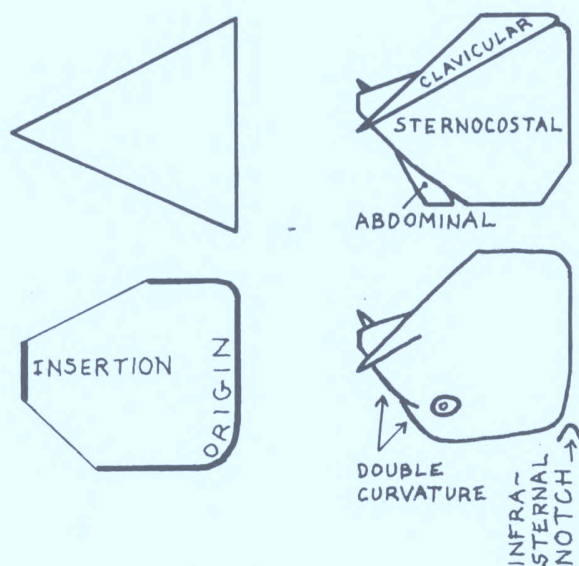
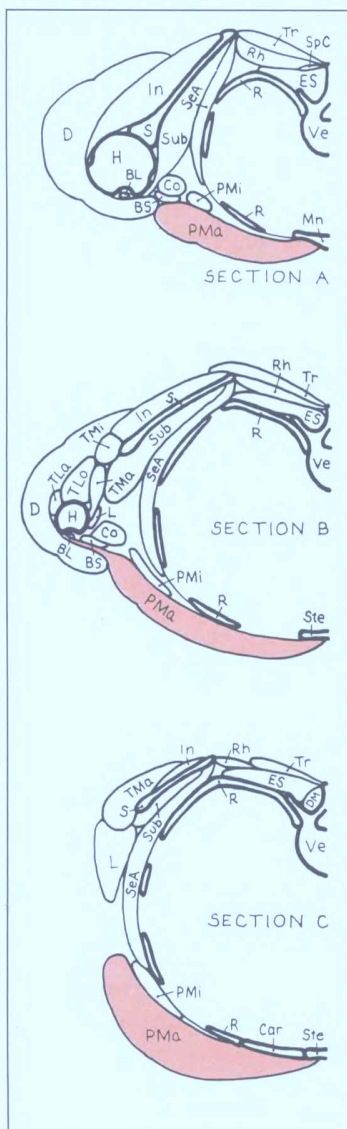
ACTION Adducts the arm, pulling it across the chest; medially rotates the arm. The clavicular portion will raise (flex) the arm, while the lower lateral sternocostal portion will then pull it down (extend it, but not hyperextend it, back past the rib cage).

STRUCTURE The pectoralis major is a large, thick, fan-shaped muscle lying on the front of the thorax. It crosses the front of the armpit, where it remains thick, and then attaches to its thin, square tendon of insertion, which enables it to pass under the deltoid to its insertion. No muscular fibers of the pectoralis pass under the deltoid—only its tendon does.

The pectoralis is divided into **clavicular** and **sternocostal** portions, based on the origin of these sections. The most lateral and inferior division of the sternocostal portion is called the **abdominal portion**. Classically, the pectoralis major is flat, planar, and squared-off, but it can also be rounded and bulging, depending on its

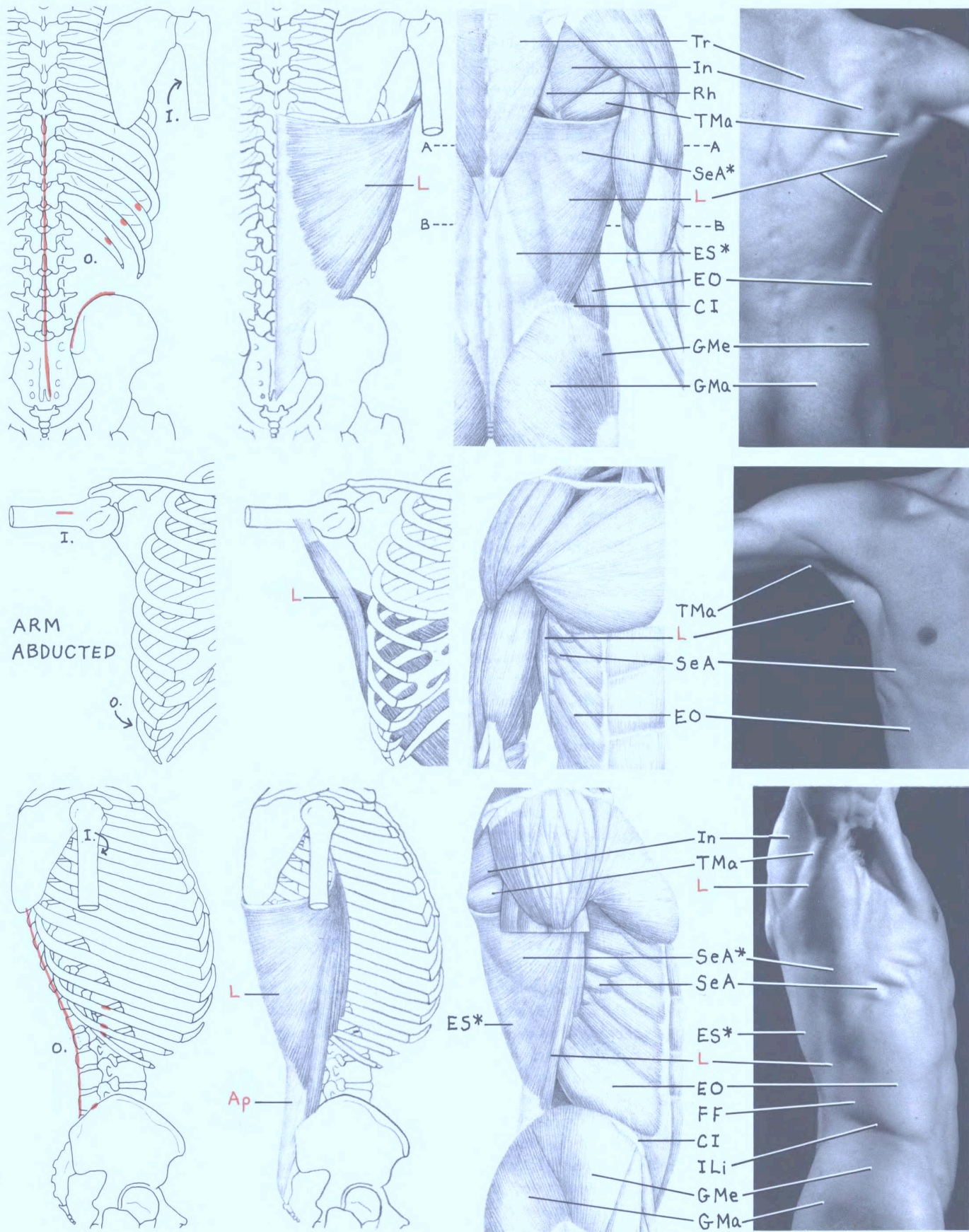
variable outline and the development of its muscular mass. The pectoralis major forms the thick muscular anterior wall of the armpit. The deep and unseen **pectoralis minor** lies behind it, adding thickness to the medial end of the wall of the armpit. A small part of the pectoralis minor may actually come to the surface between the pectoralis major and the uppermost visible digitation of the serratus anterior, but it is not defined or seen as a distinct form.

As they come off their origin, the muscle fibers of the pectoralis major divide into numerous bundles. The bundles taper and converge laterally, progressively overlying one another, a superior bundle crossing in front of the bundle immediately inferior to it. These bundles become quite conspicuous when the muscle is contracted. The uppermost clavicular fibers are directed downward and laterally toward the bottom of the line of insertion; the lowest and most lateral abdominal fibers from the side of the chest are directed upward and laterally toward the top of the line of insertion; and the remaining large group of bundles between them are, as a group, directed across toward the middle of that line. This arrangement creates a thick, muscular, **crisscross twisting** of the fibers in front of the armpit, with the clavicular portion on top (in front) and the abdominal portion deep in back. All these fibers attach into a square common tendon which then passes through the narrow space under the deltoid and over the biceps to reach its insertion on the humerus. Several vertical skin wrinkles appear in life on top of the crisscrossing fibers when



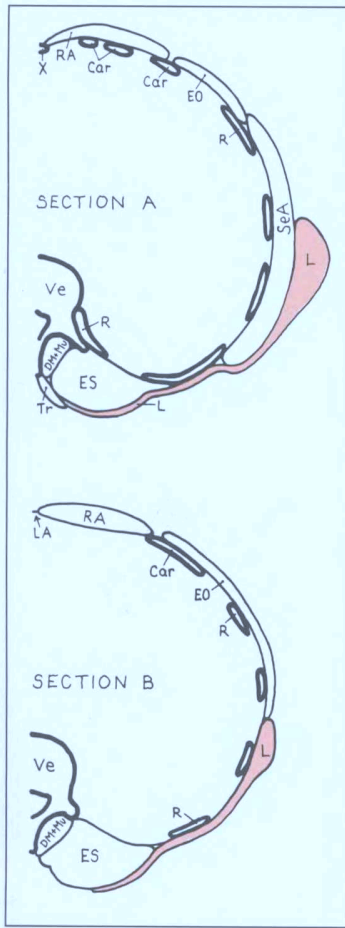
FRONT VIEW
LAT. ← MED.

The Trunk Muscles • LATISSIMUS DORSI



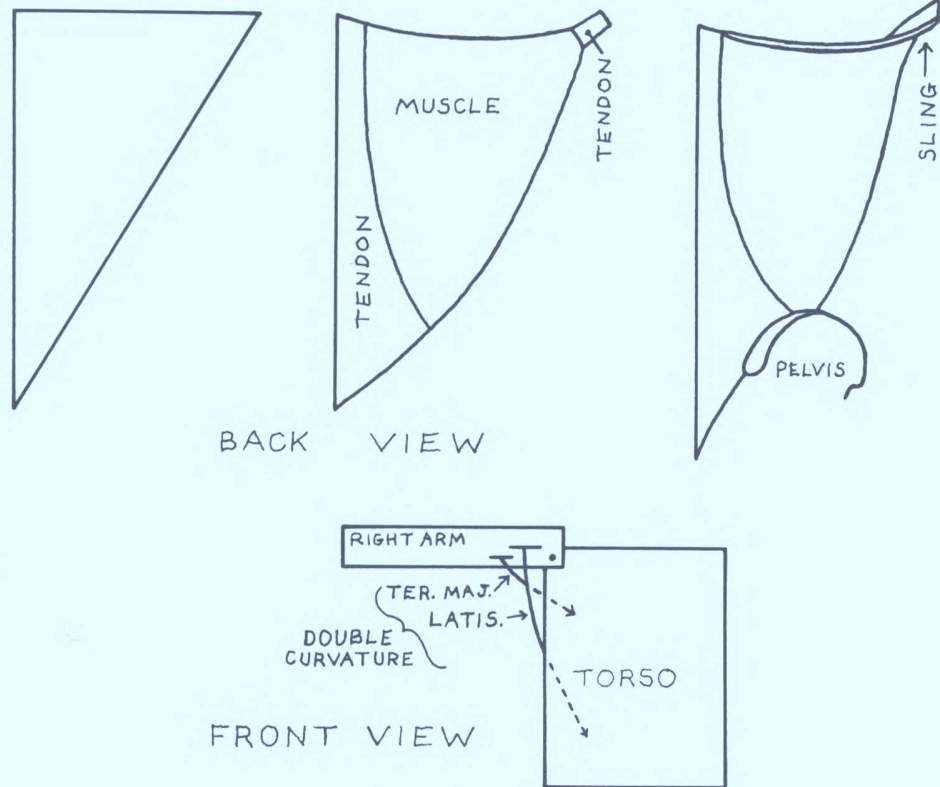
Ap Aponeurosis CI Crest of ilium EO External oblique ES Erector spinae FF Flank fat pad
 GMa Gluteus maximus GMe Gluteus medius ILi Iliac line In Infrapinatus L Latissimus dorsi
 R Rib Rh Rhomboids SeA Serratus anterior TMa Teres major Tr Trapezius
 * Under latissimus dorsi

The Trunk Muscles • LATISSIMUS DORSI

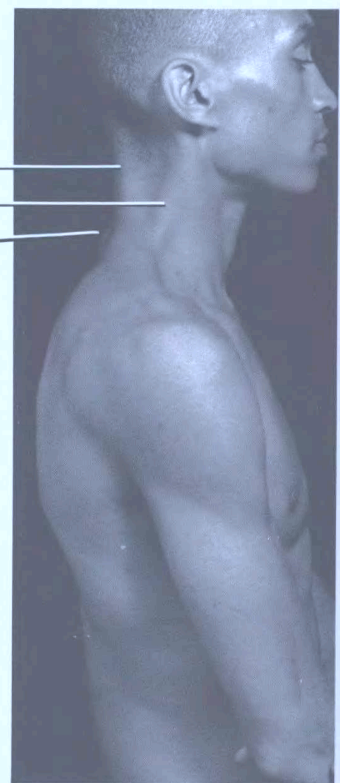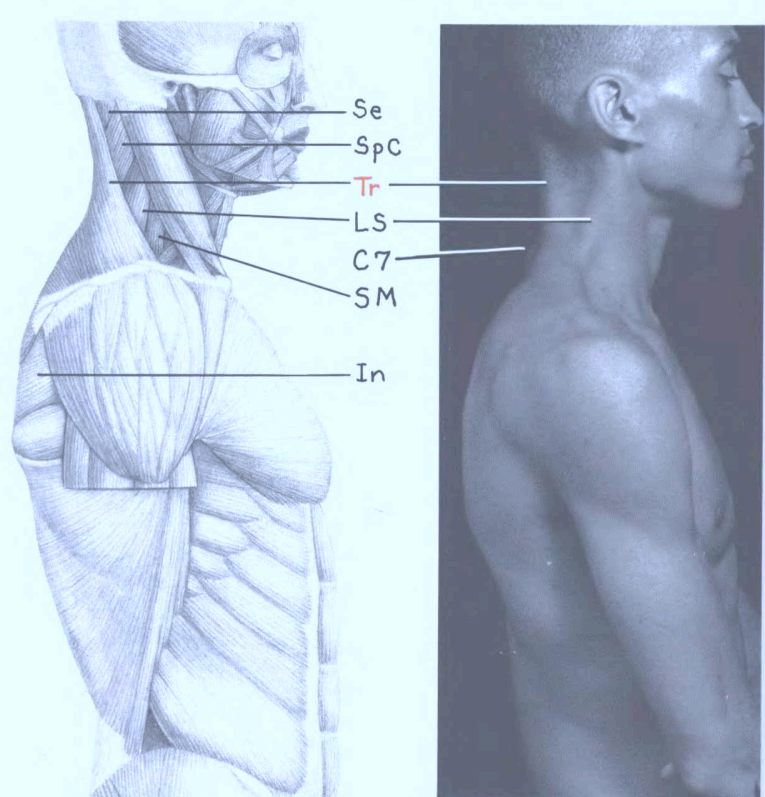
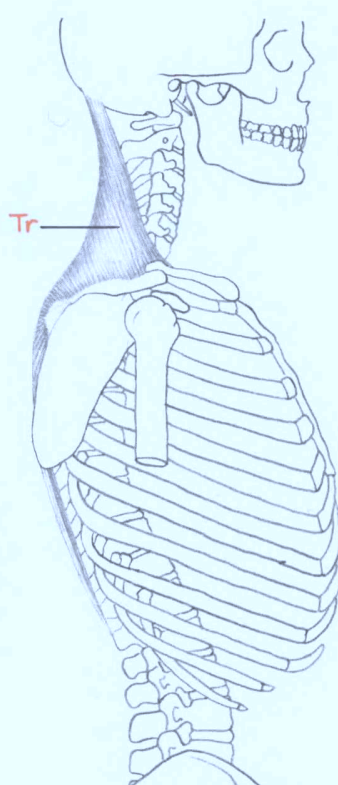
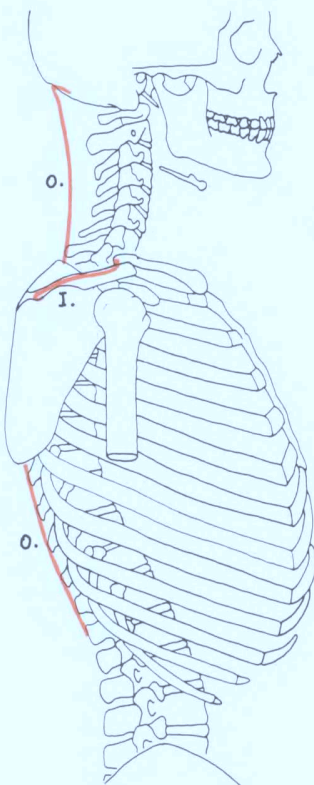
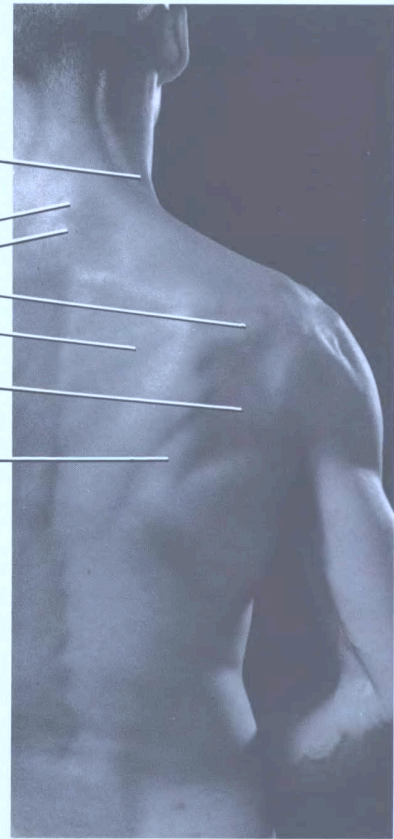
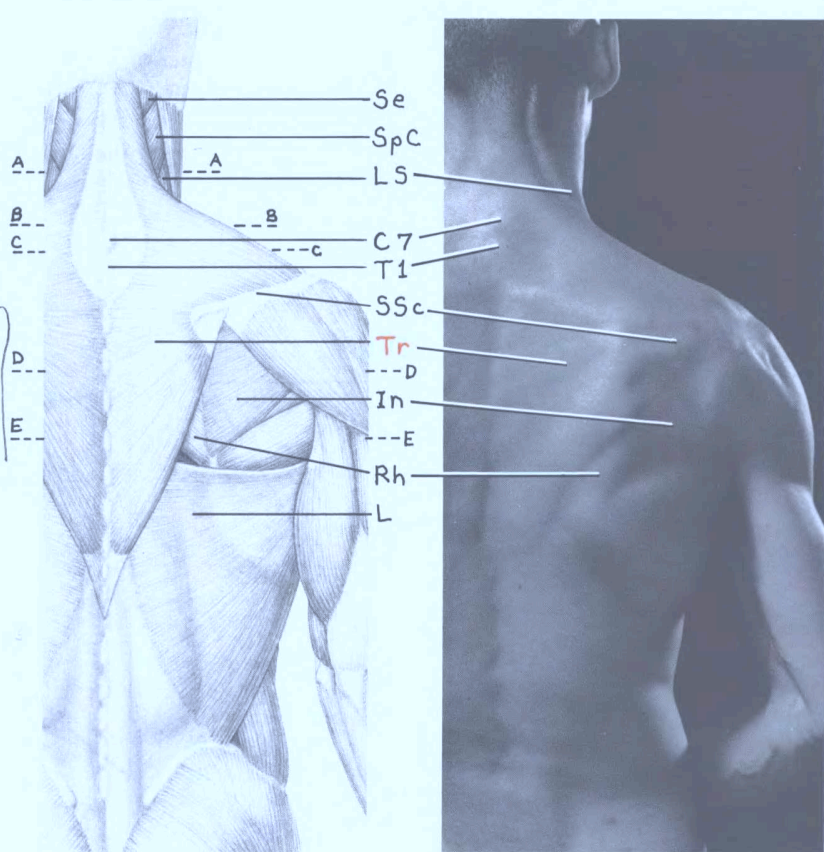
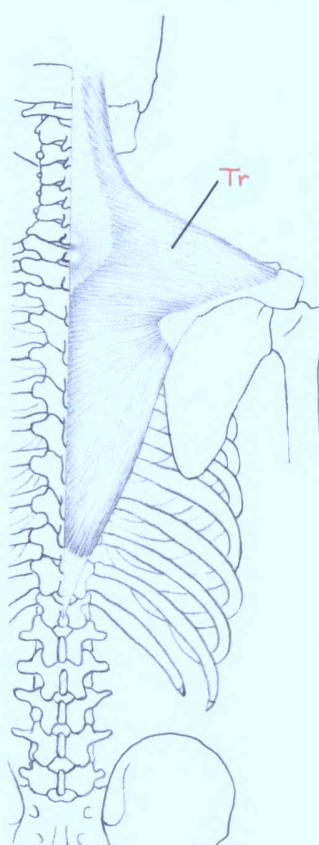
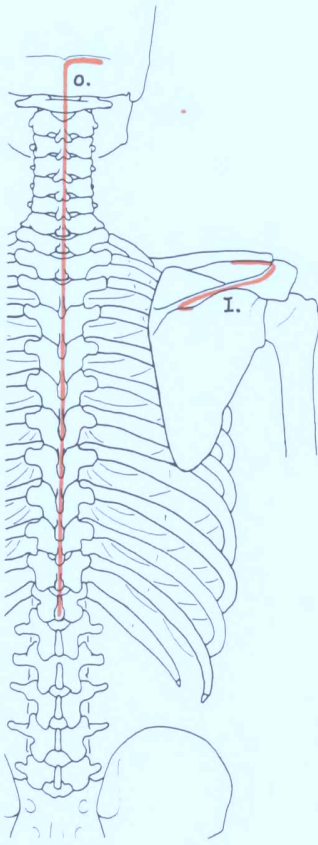


teres major, rib cage (and individual ribs), and especially the serratus anterior. These forms are more clearly seen when the trunk is flexed forward, the arm raised, and the shoulder slid forward, stretching and thinning the latissimus. The direct evidence of the latissimus on the surface, in order of prominence, is its lateral bor-

der, superior border, and the line of attachment of its muscular fibers into its tendon. The muscle sheet of the latissimus thickens as it approaches the armpit, filling the space surrounding the forms of the teres major and serratus anterior.



The Trunk Muscles • TRAPEZIUS



C7 Seventh cervical vertebra ES Erector spinae In Infraspinatus L Latissimus dorsi
 LS Levator scapulae Nu Nuchal ligament Rh Rhomboids S Scapula Se Semispinalis capitis
 SM Scalenus medius SpC Splenius capitis SSc Spine of scapula T1 First thoracic vertebra
 Tr Trapezius Ve Vertebra

Trapezius

ORIGIN A line that passes across the medial third of the superior nuchal line, at the base of the skull, over to the external occipital protuberance. It then descends along the posterior free edge of the nuchal ligament, the vertebral spinous processes down to the twelfth thoracic vertebra, and the intervening supraspinal ligaments. The line of origin is an upside-down L.

INSERTION A continuous line that passes across the posterior border of the lateral third of the clavicle, onto the medial border of the acromion, and along the *upper* edge of the spine of the scapula (excluding the expanded triangular area at the spine's medial end). The line of insertion then doubles back around for a short distance along the *lower* edge of the spine of the scapula, ending at the tubercle of the spine. Seen from above, the line of insertion is a V, pointed laterally, on the top of the bony shoulder girdle.

ACTION Rotates the scapula by lifting its lateral end and pulling its medial end downward. Working separately, the upper portion lifts the scapula, the middle portion pulls it medially, and the lower portion pulls it downward.

STRUCTURE The trapezius is an extensive, wide, triangular muscle located on the back of the chest, the top of the shoulder, and the back of the neck.

The upper fibers of the trapezius pass downward and outward; the middle fibers pass horizontally outward; and the lower fibers pass upward and outward, heading toward the tubercle on the spine of the scapula via a small aponeurosis. The muscle varies in thickness in its different areas. The part on the back of the neck is very thin; along with the deep semispinalis capitis muscle it creates a muscular column on either side of the midline. The nuchal ligament lies on the midline of the back of the neck, at the bottom of the vertical groove between these columns when the neck is upright. It becomes a raised ridge when the head and neck are flexed forward. In side view, the back profile of the neck can be concave, straight, or convex.

In nonmuscular individuals, or when the scapula has been slid laterally and rotated so the upper portion of the trapezius becomes elongated and thin, the vertebral border of the scapula located above the base of the spine may become evident on the surface, beneath the muscle. When the arm is abducted, the oval form of the supraspinatus can be seen bulging deep to the trapezius just above the medial portion of the spine of the scapula.

The lowest fibers of the trapezius may separate visually, creating an independent elliptical or elongated form, directed upward and out-

ward toward the scapular tubercle. This portion can be visualized as a separate flat muscle belly with flattened tendons at both ends.

The lower lateral edge of the trapezius can be seen passing obliquely upward and outward on the middle of the back; it is clearly seen when the arm is held horizontally out to the side and pushed down against resistance.

The entire trapezius can be reduced to three major planes: the back plane of the neck, the top plane of the shoulder, and the vertical plane of the back.

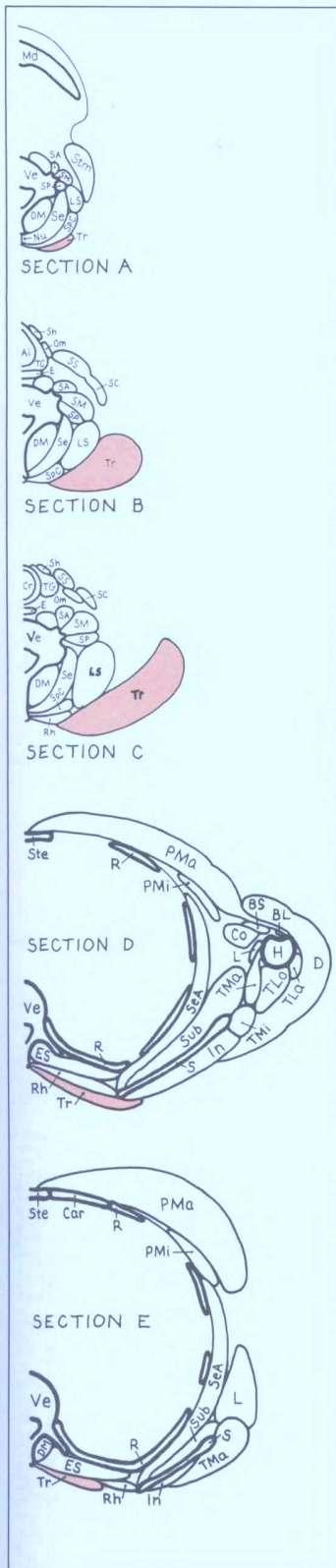
The majority of the trapezius creates the **vertical plane of the back**, also called the **rhomboid plane** (based on the orientation of the underlying rhomboid muscle). This vertical plane is directed medially and anteriorly from the vertebral border of the scapula to the spinous processes of the vertebrae on the midline of the body. The rhomboid planes of both muscles (both sides of the body), along with both **scapular planes** (the planes created by the infraspinatus and spine of the scapula), create a wide W configuration when *viewed from the top*. When the shoulder blades are pulled together in back, the rhomboid planes disappear and the trapezius muscles of both sides bulge and touch each other, producing a tight vertical cleft between them.

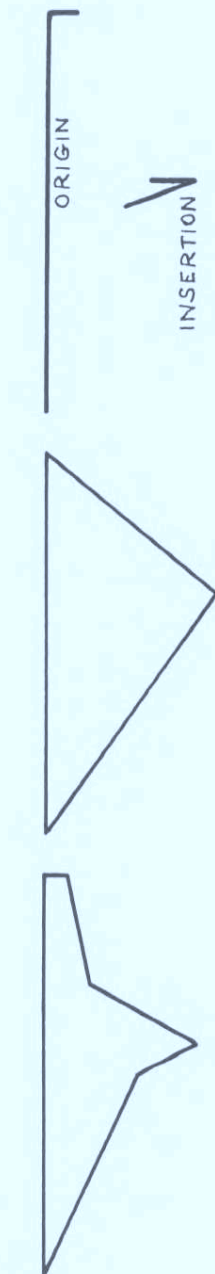
The **top plane of the shoulder**, for the most part, is directed upward and backward. The posterior edge of this plane is formed by the spine of the scapula. Anteriorly, the shoulder plane curves over the top of the shoulder.

The **back plane of the neck**, created by the cervical portions of the trapezius of both sides of the body, can be visualized in two ways—on the one hand it is often flattened and planar, while at other times it is rounded (side to side) and participates in producing the cylindrical volume of the neck.

There are **three triangular aponeurotic or tendinous areas** in the trapezius, as follows:

1. A relatively **large triangular area surrounding the seventh cervical vertebra**. These tendinous areas of the muscles of both sides of the body create a diamond, oval, or teardrop-shaped depression, prolonged upward, on the back of the neck. It usually reaches up to the base of the skull and ends inferiorly at the level of the spinous process of the third thoracic vertebra. The prominent spinous processes of the seventh cervical and first thoracic vertebrae project at the center of this tendinous, depressed area.
2. A **smaller triangular area at the upper lateral end of the fibers of the lower half of the trapezius**. This tendinous area lies partially on the expanded triangular base of the me-

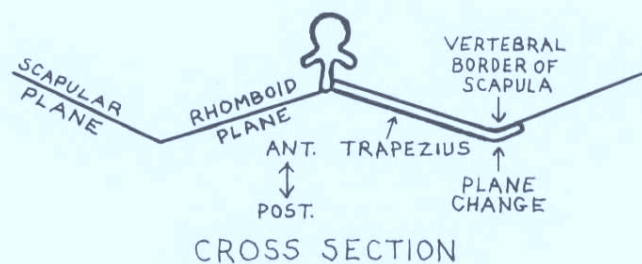
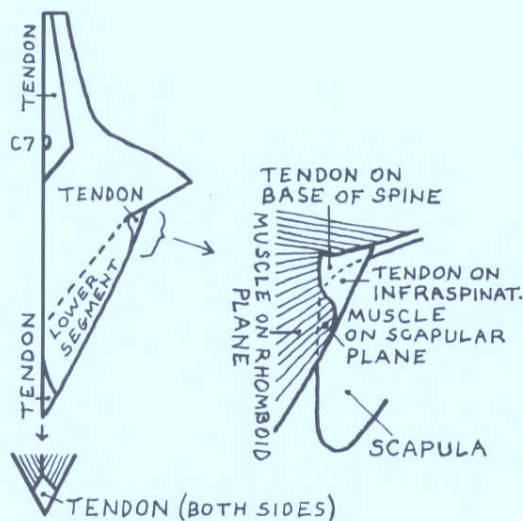




dial end of the spine of the scapula (which shows through as a bony plane) and partially on the surface of the infraspinatus muscle. The infraspinatus portion of the tendon may appear as a depression, caused by the fullness of the surrounding muscular and bony forms. The lower edge of this tendinous triangle can sometimes be seen constricting the muscular form of the infraspinatus. The lateral ends of the lower muscle fibers of the trapezius attach into the infraspinatus portion of the tendon in an elongated S-curve line which lies *lateral* to the underlying vertebral border of the scapula. This produces a plane change of the trapezius belly as its fibers pass over this scapular border; most of the belly lies medial to the vertebral border on the rhomboid plane, while only a very small portion of the belly lies lateral to it on the scapular plane. When the arm is abducted away from the side of

the body, automatically rotating the scapula, the scapula and overlying infraspinatus slide out laterally from under the small scapular portion of the belly of the trapezius.

3. The **smallest triangular area at the inferior tip of the muscle**. It is this small triangular aponeurosis, not the actual muscle fibers, that reaches the very bottom of the line of origin of the trapezius (at the spinous process of the twelfth thoracic vertebra). Because this tendinous area is not visible as it lies on the erector spinae, the inferior end of the *form* of the muscular belly of the trapezius ends superior to the final attachment. The triangular tendinous areas of both sides of the body create a diamond shape, with the inferior ends of both sides of the *muscular form* of the trapezius ending in relief as an inverted V, or at least appearing blunt, rather than as a single sharp point.



The Trunk Muscles • RHOMBOIDS

Rhomboids (Major and Minor Together)

ORIGIN From the inferior portion of the nuchal ligament down to the fifth thoracic vertebra, along the spinous processes and interconnecting supraspinal ligament of the vertebrae (on the midline of the upper back).

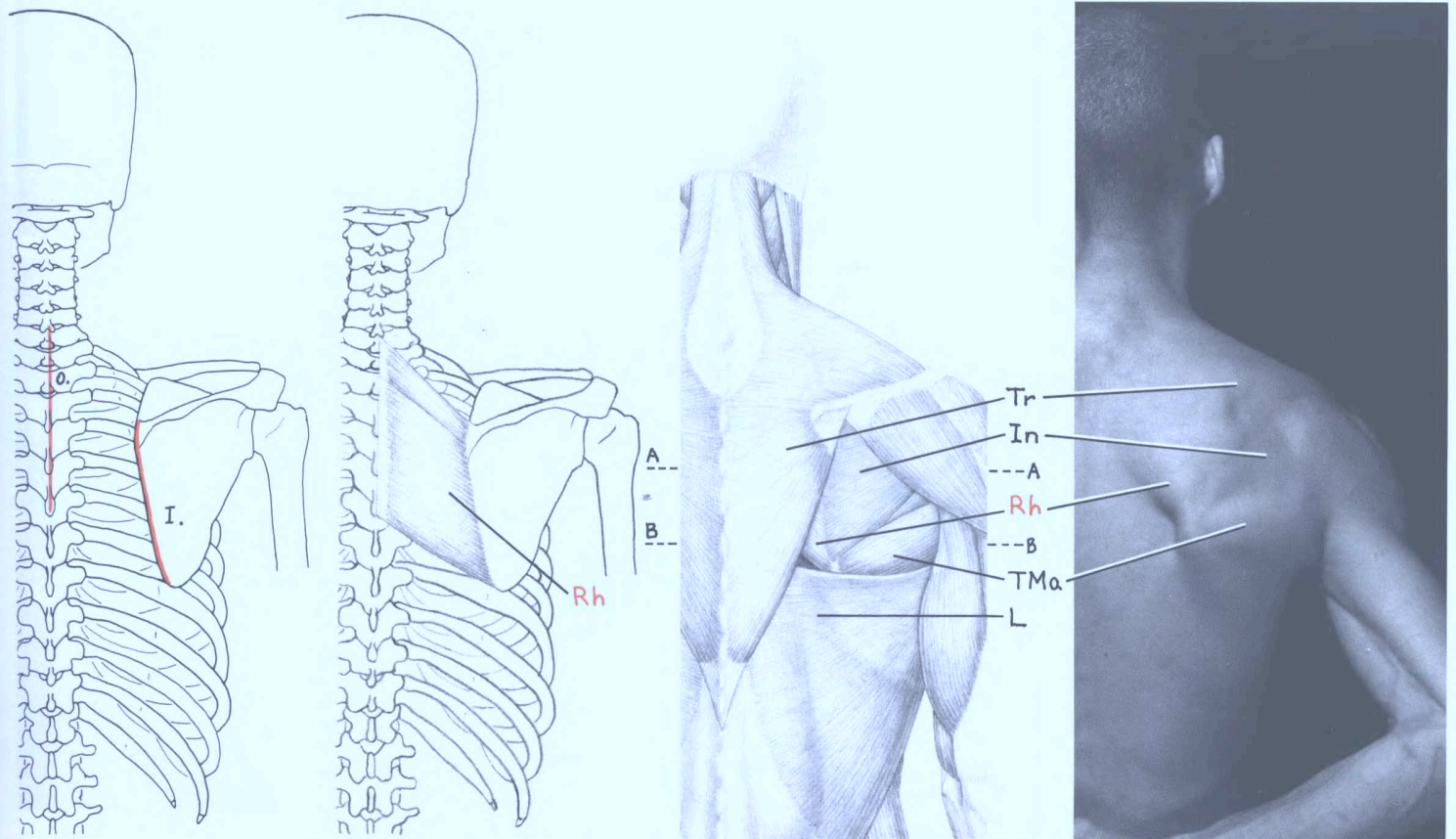
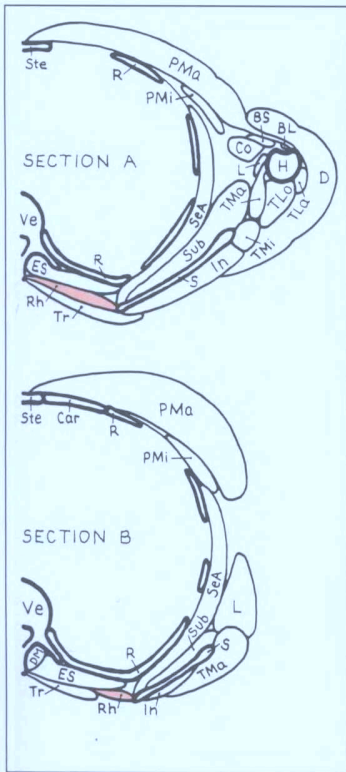
INSERTION The very edge of the medial (vertebral) border of the scapula, extending from the top of the triangular expansion of the base of the spine down to the inferior angle.

ACTION Together the rhomboids adduct and raise the scapula. They assist in rotating the scapula (during rotation, the bottom of the scapula moves medially and the acromion moves inferiorly).

STRUCTURE The rhomboid major and rhomboid minor muscles are barely separable and are here considered as a single, flat, quadrila-

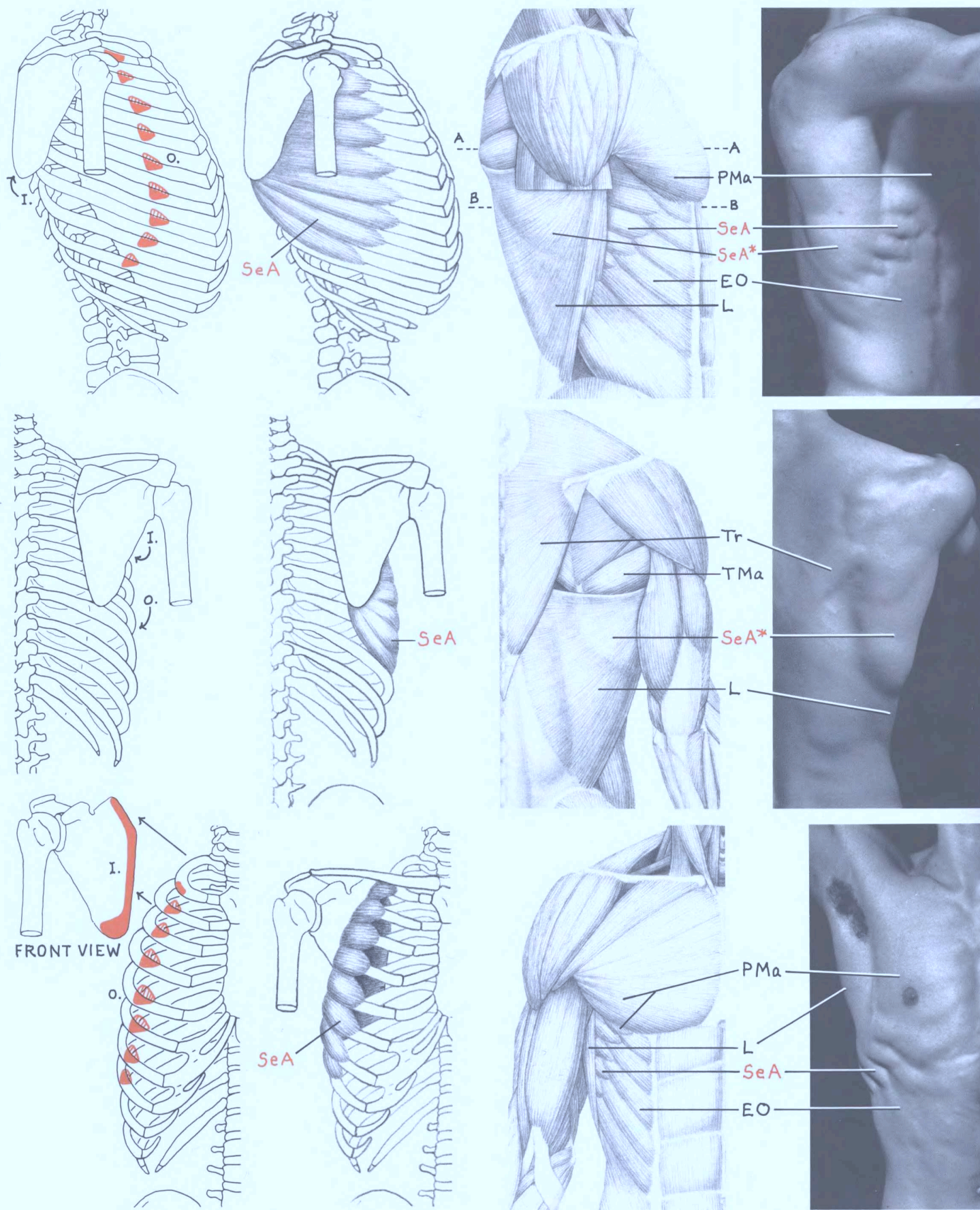
teral muscle on the upper back. When contracting and shortening (pulling the scapula towards the midline), the rhomboids may produce an oval bulge which can be seen under the trapezius. This form lies closer to the scapula than to the midline of the back.

The lateral portion of the oblique inferior border of the muscle is superficial, but is not always easily seen. It lies in the triangular space bordered by the medial border of the scapula, the lateral edge of the trapezius, and the top edge of the latissimus dorsi. The rest of the inferior edge can sometimes be seen *under* the trapezius, heading diagonally upward and medially to its attachment on the vertebral column. Any line or form directed *upward and medially* from the inferior angle of the scapula to the midline is part of the rhomboids, not the trapezius.



ES Erector spinae In Infraspinatus L Latissimus dorsi Rh Rhomboids S Scapula TMa Teres major
Tr Trapezius Ve Vertebra

The Trunk Muscles • SERRATUS ANTERIOR



EO External oblique L Latissimus dorsi PMA Pectoralis major PMi Pectoralis minor R Rib
 S Scapula SeA Serratus anterior Sub Subscapularis TMA Teres major Tr Trapezius
 * Under latissimus dorsi

The Trunk Muscles • SERRATUS ANTERIOR

Serratus Anterior (Serratus Magnus)

ORIGIN A line of small triangular areas on the outer surfaces and superior borders of the first eight or nine ribs and the aponeuroses covering the intervening intercostal muscles.

INSERTION Narrow strip on the costal (deep) surface of the scapula at its vertebral border, which expands in area at the inferior angle of the scapula.

ACTION Slides the scapula around forward, as in punching, and by its inferior fibers rotates its inferior angle laterally, which elevates the lateral end of the shoulder, and therefore the arm.

STRUCTURE When considered in its entirety, the serratus anterior is a large quadrilateral muscle which embraces the curved form of the rib cage. It is divided into fingerlike digitations (bundles), each originating from an area on the side and upper border of a rib and the intercostal space above. The muscle can be subdivided into upper and lower portions. The **upper portion** partially lies inconspicuously against the upper side of the rib cage in the armpit and partially sits sandwiched between the scapula and rib cage.

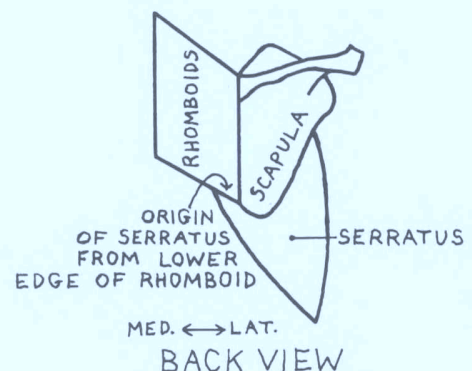
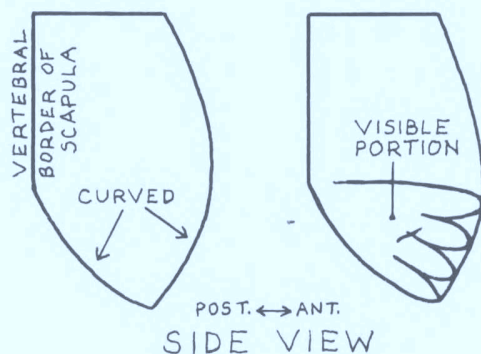
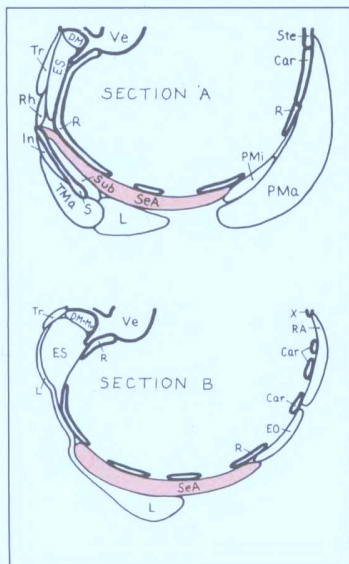
The **lower portion** consists of five or six pointed digitations which create a thick, fan-shaped mass radiating forward from the inferior angle of the scapula. Only the lowest three or four of these digitations can be seen—their anterior half is superficial on the side of the chest (where they interdigitate with the bundles of the

external oblique), but as they head toward the inferior angle of the scapula, they pass deep to the latissimus dorsi; however, the form of the lower portion remains visible under the thin latissimus. The uppermost visible digitation begins at or just above the level of the inferior border of the pectoralis major. The digitations can begin quite far forward on the side of the rib cage, almost reaching the front of the chest.

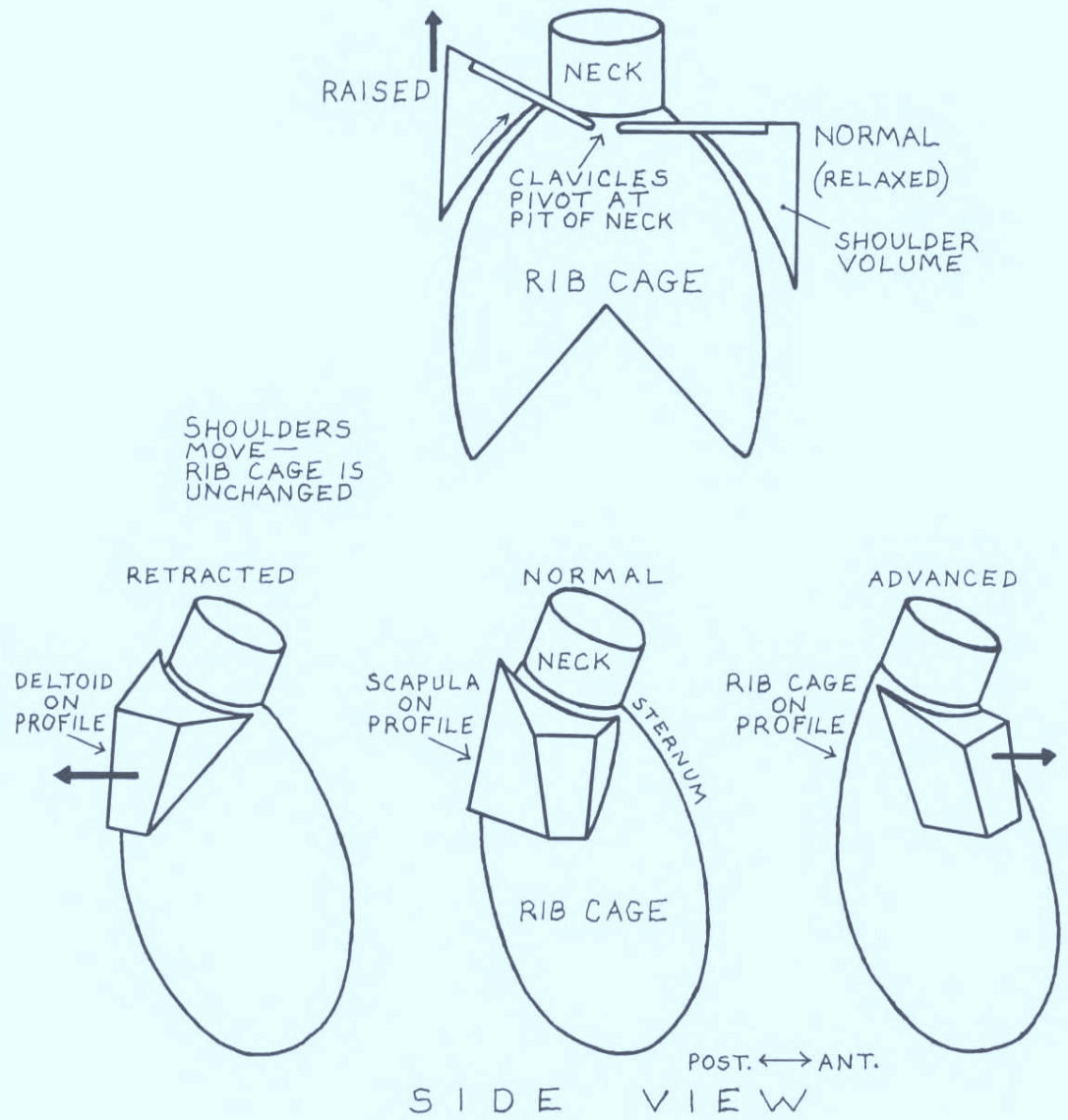
The line of origin of the tips of the exposed digitations on the side of the rib cage forms a toothed (serrate), anteriorly curved line, which appears to be directed from the nipple to the posterior superior iliac spine when looking at the figure in side view. Therefore, the length of the exposed part of each of the digitations, from its tip to the lateral border of the latissimus dorsi, diminishes inferiorly. Sometimes the tip of the lowest digitation may be completely hidden from view under the front edge of the latissimus, especially if the latissimus is drawn forward in the advanced shoulder.

The digitations of the serratus anterior are bulged and more horizontal than the flatter and more oblique digitations of the external oblique. The ribs, often seen under the external oblique, are not seen under the serratus.

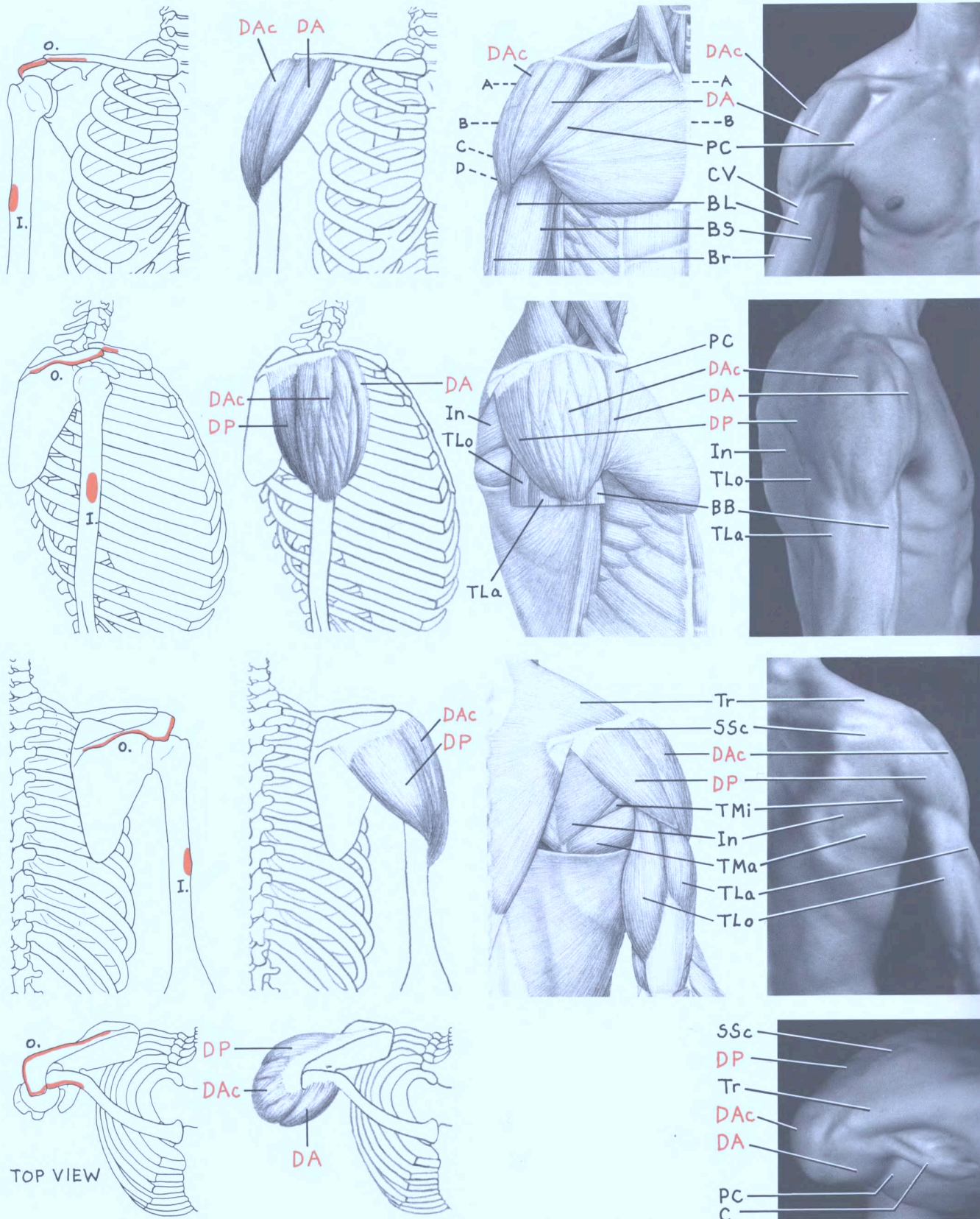
The inferior border of the serratus anterior will sometimes continue inserting past the inferior angle of the scapula into the lower edge of the rhomboid major muscle for a short distance; consequently, the form of the serratus under the latissimus will extend further medially.



The Shoulder Muscles



The Shoulder Muscles • DELTOID



BB Biceps brachii BL Biceps brachii—long head Br Brachialis BS Biceps brachii—short head
 C Clavicle CV Cephalic vein D Deltoid DA Deltoid—anterior portion
 DAC Deltoid—acromial portion DP Deltoid—posterior portion H Humerus In Infraspinatus
 PC Pectoralis—clavicular portion PMa Pectoralis major SSc Spine of scapula
 TLa Triceps—lateral head TLo Triceps—long head TMa Teres major TMi Teres minor
 Tr Trapezius

The Shoulder Muscles • DELTOID

Deltoid

ORIGIN A continuous line passing along the anterior surface of the lateral third of the clavicle, the external border and adjacent top surface of the acromion of the scapula, and the lower edge of the spine of the scapula (extending medially up to, but not including, its medial triangular expansion). The deltoid roughly originates just below the insertion of the trapezius (the scapular spine remains subcutaneous).

INSERTION The deltoid tuberosity halfway down the outside of the shaft of the humerus.

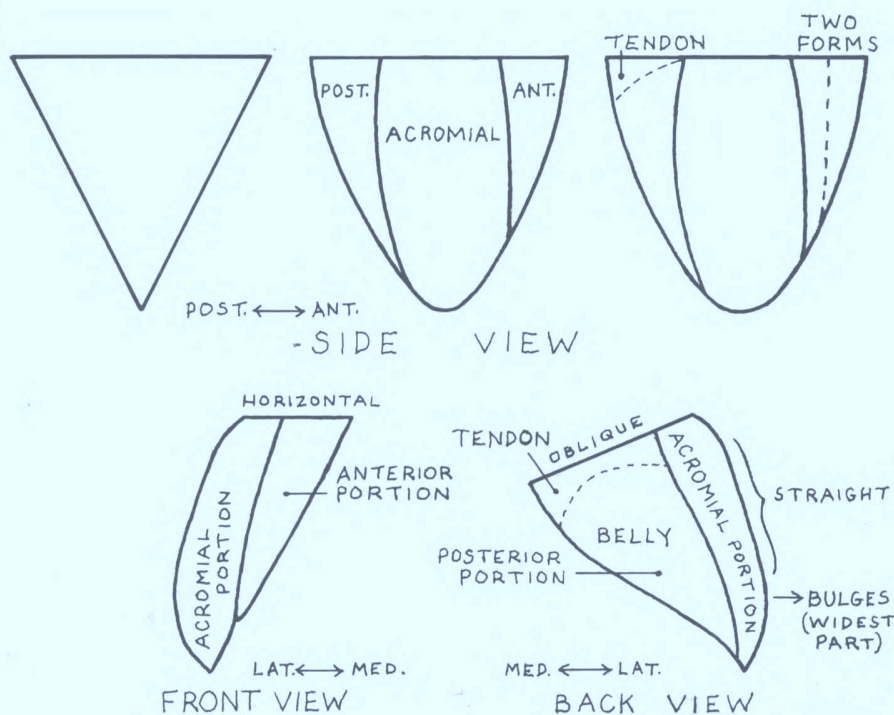
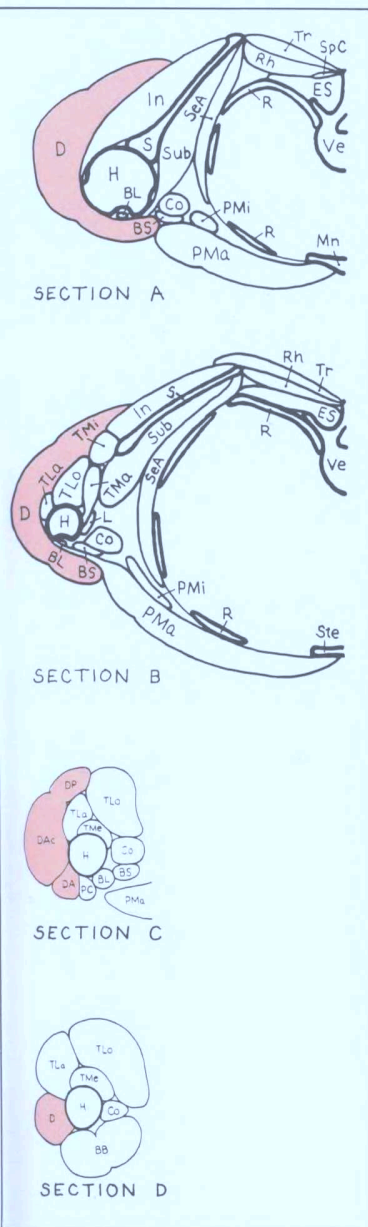
ACTION The anterior portion flexes the arm (raises it in front of the body) and pulls the horizontal arm toward the front of the body; the middle acromial portion powerfully abducts the arm; and the posterior portion extends the arm backward and pulls the horizontal arm backward. The anterior and posterior portions are antagonists when they flex and extend the arm at the shoulder joint.

STRUCTURE The deltoid is a thick triangular muscle, pointed inferiorly, which cups the shoulder joint. The muscle is divided into three portions: an anterior (clavicular) portion, an acromial (middle) portion, and a posterior portion. In front, the deltoid and pectoralis major are separated for a short portion of their lengths, just below the clavicle, by a triangular depression called the **infraclavicular fossa**.

The **anterior portion** of the deltoid, originating from the clavicle, is shorter than the other two portions. It shows up as a teardrop or oval relief on the surface, and sometimes splits down the middle into two forms. The lateral form descends slightly further. The belly of the anterior portion ends in its own wide tendon a short distance above the final insertion on the humerus. This belly, and the belly of the clavicular portion of the pectoralis major, end at about the same level (the anterior portion of the deltoid actually descends slightly further). The fibers, and therefore the forms, of these two muscles lie side by side—the deltoid does not cover the muscular fibers of the clavicular pectoralis; however, the *tendon* of the clavicular pectoralis (without fibers) *does* pass under the anterior deltoid. The tendon of insertion of the anterior portion of the deltoid then descends on the front (not outer) surface of the acromial fibers of the deltoid and inserts toward the front surface of the humerus, adjacent to the origin of the brachialis. It is actually the other two portions of the deltoid that insert onto the outside of the humerus.

The anterior portion of the deltoid projects anteriorly owing to the forward projection of the underlying spherical proximal extremity of the humerus, especially when the arm is hyperextended back past the trunk.

The **posterior portion** of the deltoid is located on the back of the shoulder. It thins into an



The Shoulder Muscles • SUPRASPINATUS

Supraspinatus

ORIGIN Medial two-thirds of the posterior surface of the scapula superior to the spine (*supraspinatus fossa*).

INSERTION Superior facet of the greater tubercle on the top of the lateral part of the proximal extremity of the humerus.

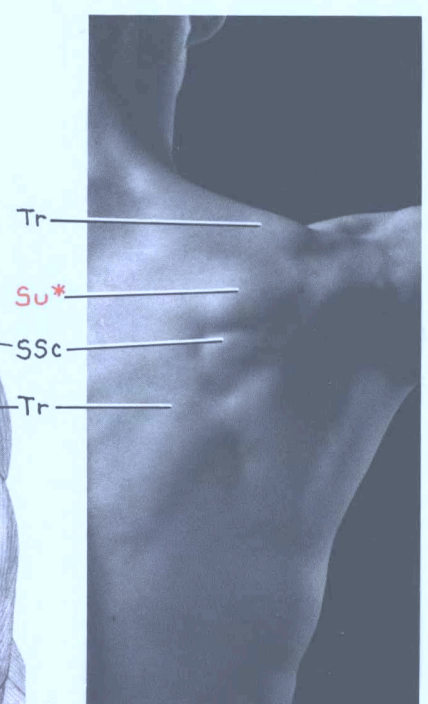
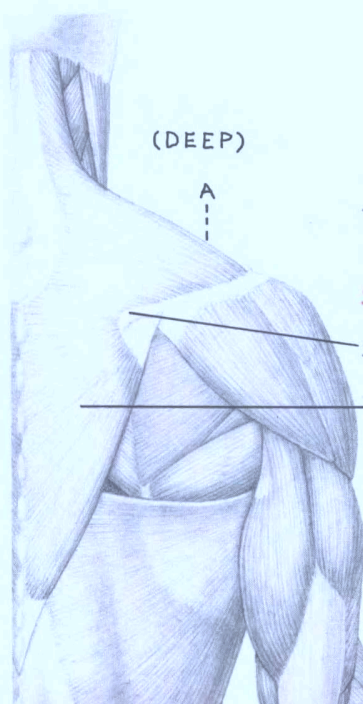
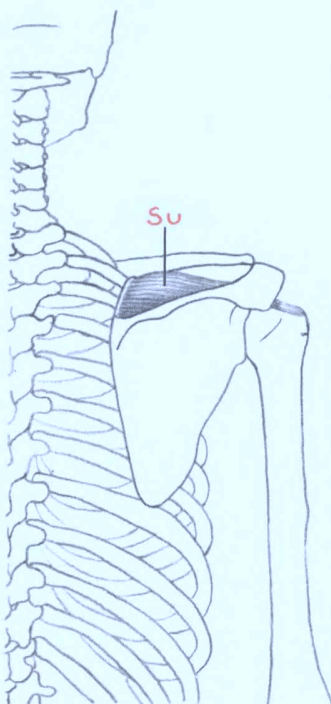
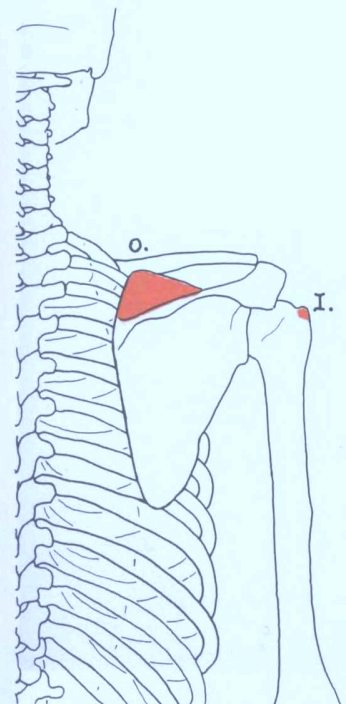
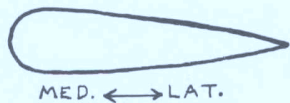
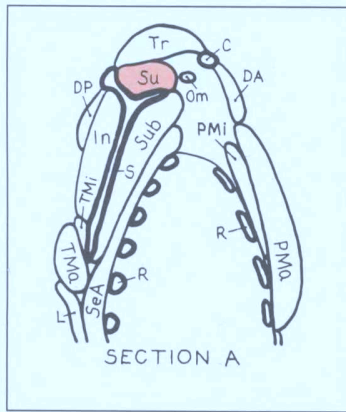
ACTION Abducts the arm; stabilizes the shoulder joint from above by pulling the head of the humerus into its socket.

STRUCTURE The supraspinatus passes laterally over the top of the shoulder joint (under the acromion) to its insertion on the outside of the top of the proximal extremity of the humerus. Although it lies deep to the trapezius under a substantial thickness of muscle, when the arm

is abducted, its form is occasionally revealed as a bulging egg-shaped or teardrop form (pointed end directly laterally) above the medial half of the spine of the scapula. In this position, the supraspinatus is at its shortest and thickest.

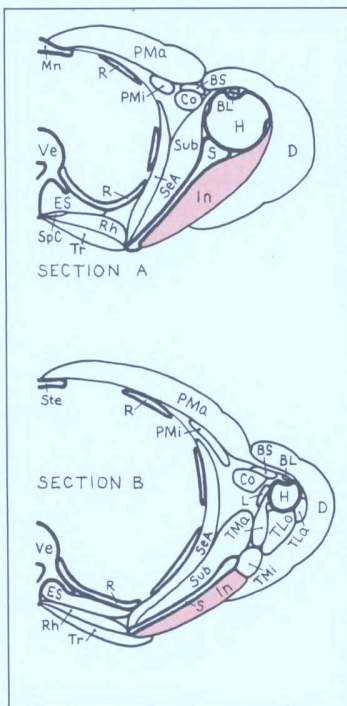
If the scapula is prevented from rotating (either by external resistance or internal muscle fixation) as the arm is abducted to the horizontal away from the side of the body, any bulge developing above the scapular spine must be the supraspinatus, since in this case there is no shortening of the trapezius.

When the arm is down by the side of the body, there is no indication of the supraspinatus on the surface. A slight hollow may actually develop above the scapular spine, as the supraspinatus is now stretched thin.



Om Omohyoid S Scapula SSc Spine of scapula Su Supraspinatus Tr Trapezius * Under trapezius

The Shoulder Muscles • INFRASPINATUS



Infraspinatus

ORIGIN Most of the posterior surface of the scapula below the spine (*infraspinatus fossa*).

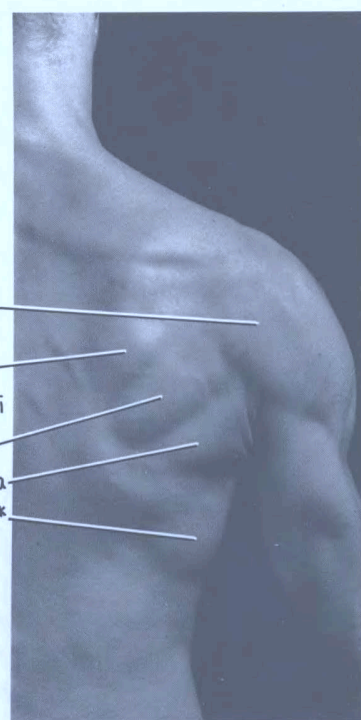
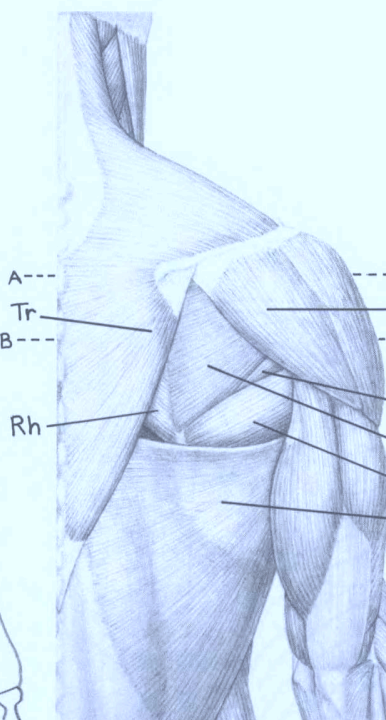
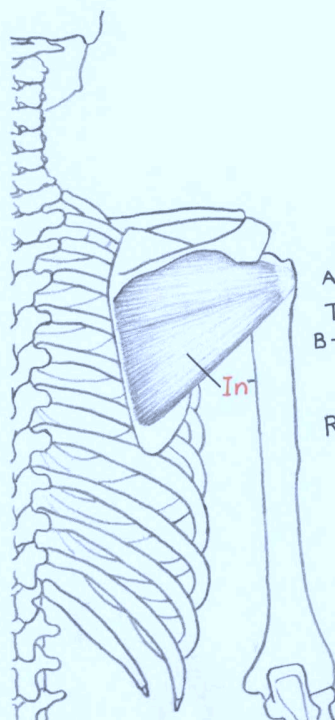
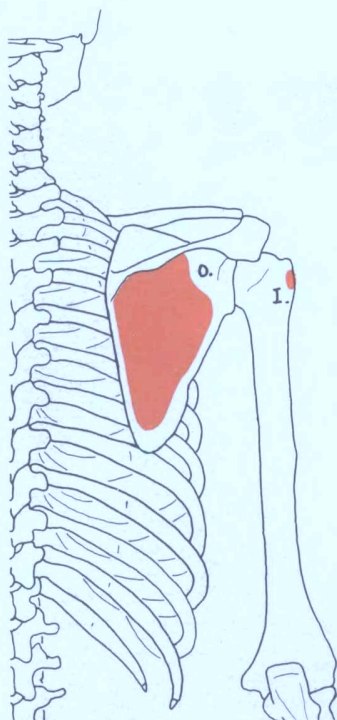
INSERTION Middle facet of the greater tubercle of the humerus.

ACTION Laterally rotates the arm; helps stabilize the shoulder joint from behind by holding the head of the humerus in its socket.

STRUCTURE The infraspinatus is a flat triangular muscle that sits on the back of the shoulder blade below the spine. Although typically exhibiting a slightly planar surface surrounded by bulging muscles, the infraspinatus itself can bulge considerably when the humerus is laterally rotated to its maximum (this action

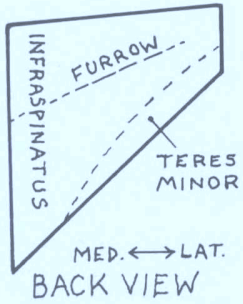
shortens and thickens the muscle). Because its lateral portion is covered by the deltoid, the superficial area of the infraspinatus may appear as a wide vertical form when the arm is down. When the arm is raised, the posterior portion of the deltoid slides upward, exposing more surface area of the infraspinatus.

The muscle fibers, directed outward and upward, seem to be folded on themselves, which occasionally divides the infraspinatus into two forms—a superior and an inferior—separated by a shallow furrow that is directed outward and upward toward the head of the humerus. This furrow may or may not reach all the way over to the medial border of the scapula.



D Deltoid DP Deltoid—posterior portion H Humerus In Infraspinatus Rh Rhomboids S Scapula
SeA Serratus anterior SSc Spine of scapula TLo Triceps—long head TMa Teres major

The Shoulder Muscles • TERES MINOR



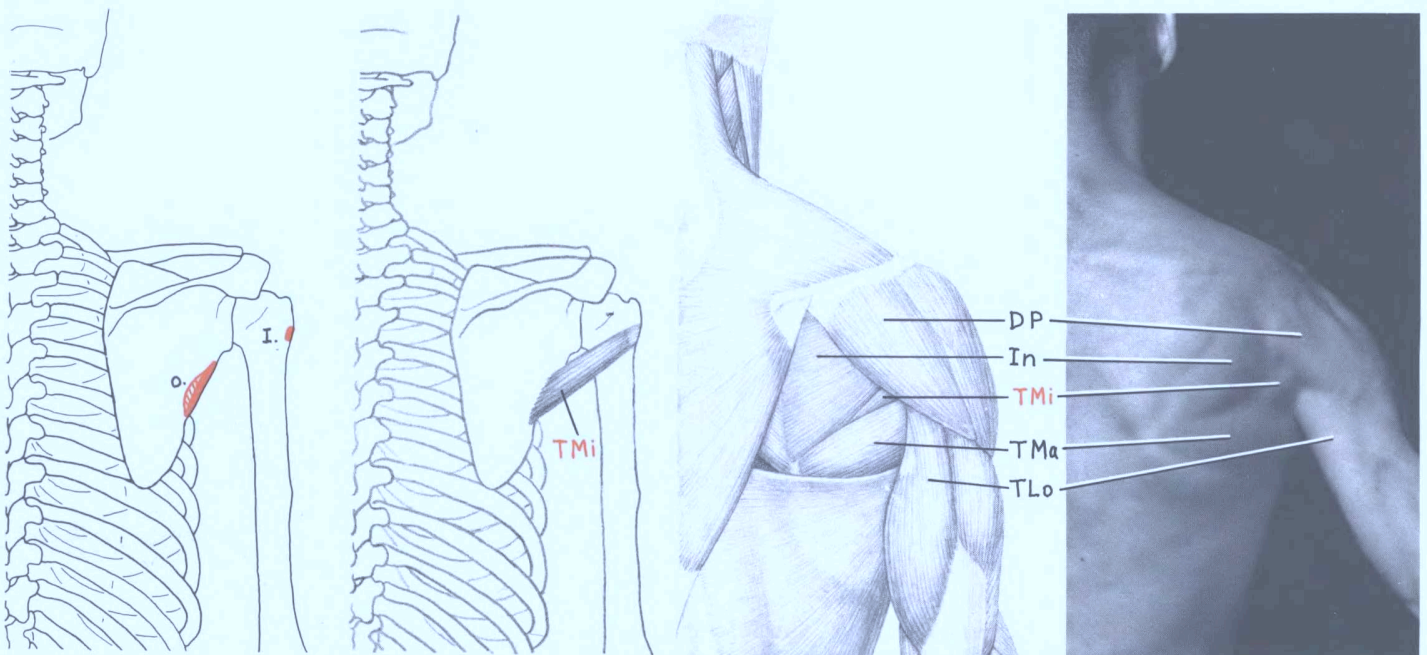
Teres Minor

ORIGIN Raised ridge of bone on the posterior surface of the upper two-thirds of the lateral (axillary) border of the scapula, and partly from the fascia covering the posterior surface of the infraspinatus and the deep surface of the medial end of the teres major.

INSERTION The lowest of the three facets of the greater tubercle of the humerus and a short distance immediately below it on the shaft.

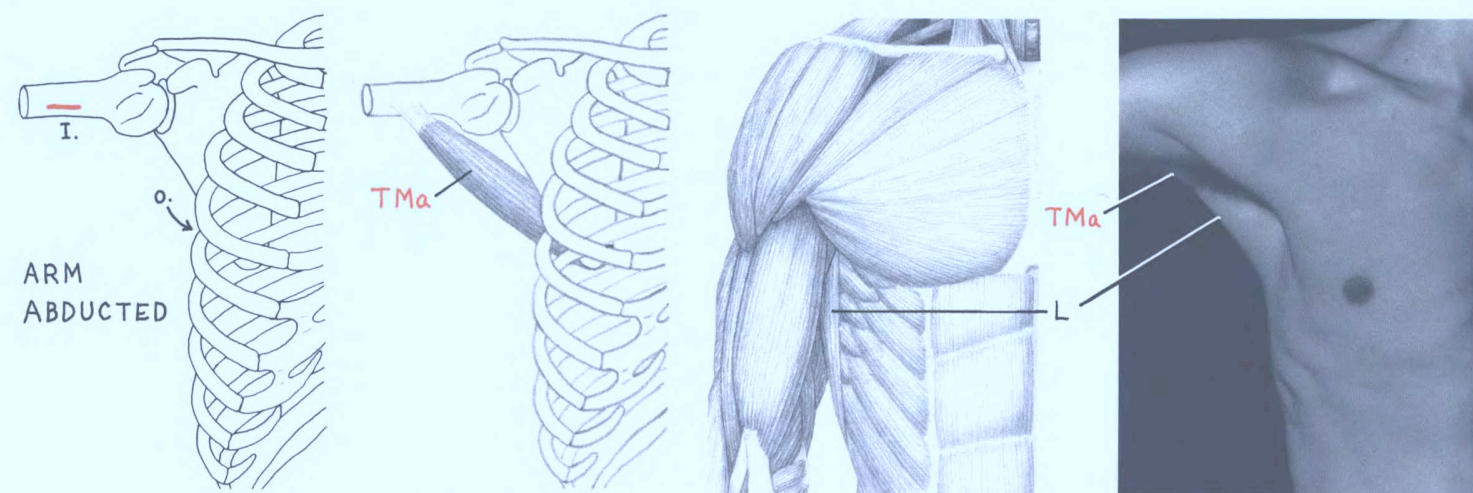
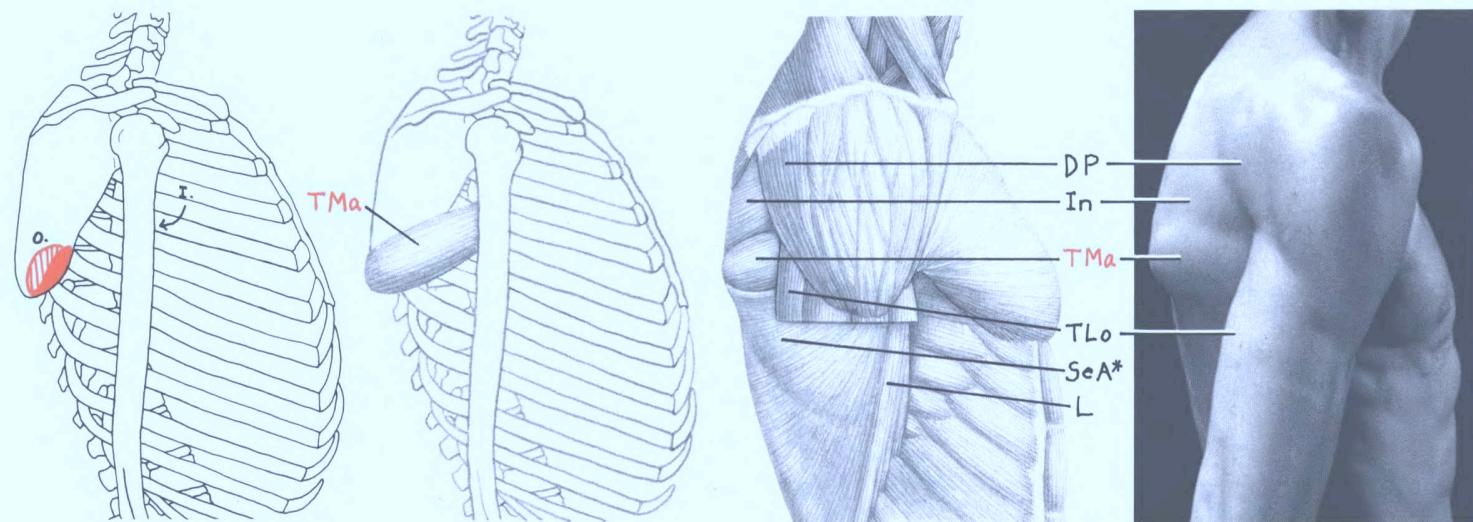
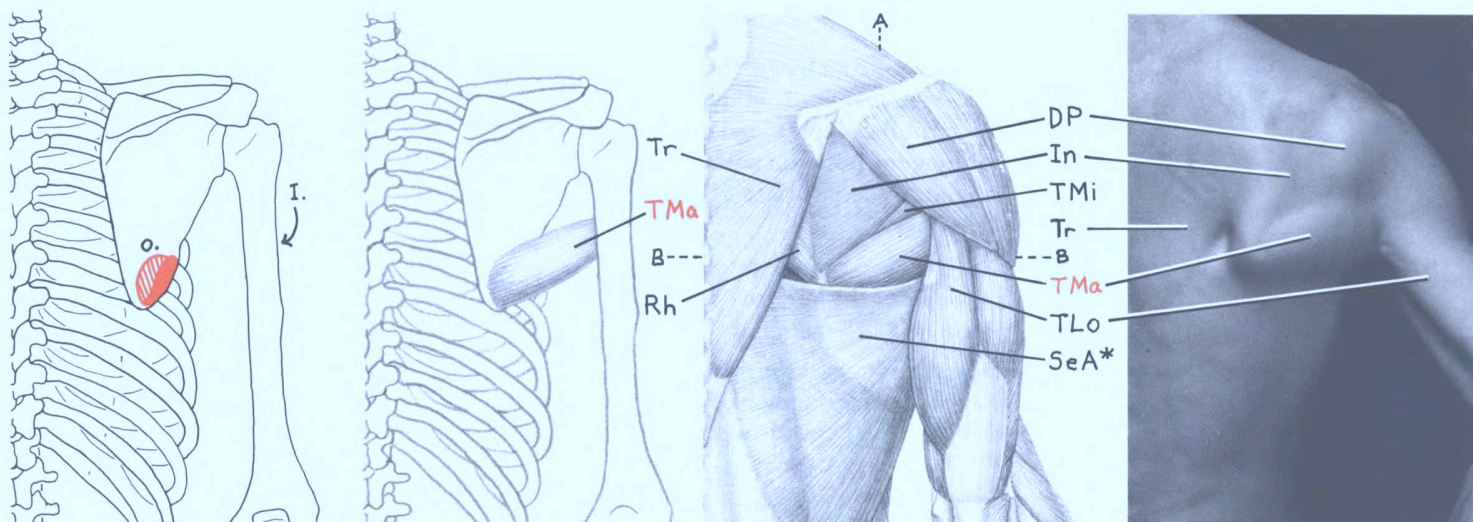
ACTION Laterally rotates the arm and weakly adducts it; helps stabilize the shoulder joint by holding the head of the humerus in its socket.

STRUCTURE Rarely seen on the surface, the teres minor is a small, elongated, cylindrical muscle that usually blends with the plane created by the infraspinatus muscle. Both muscles are covered by a layer of dense fascia which consolidates their forms. The teres minor runs obliquely upward and outward from its origin and inserts via a thick, flat tendon onto the back of the superior part of the humerus. It is occasionally seen when the arm is held horizontally, laterally rotated, and then pushed downward and backward against resistance.



TMi Teres minor Tr Trapezius * Under latissimus dorsi

The Shoulder Muscles • TERES MAJOR



DP Deltoid—posterior portion In Infraspinatus L Latissimus dorsi Rh Rhomboids S Scapula
 SeA Serratus anterior Sub Subscapularis TLo Triceps—long head TMa Teres major
 TMi Teres minor Tr Trapezius * Under latissimus dorsi

The Shoulder Muscles • TERES MAJOR

Teres Major

ORIGIN Raised oval area on the posterior surface of the inferior angle of the scapula (excluding a narrow vertical area immediately adjacent to the medial border), continuing one-third of the way up its lateral border, and partly from the adjacent fascia covering the outer surface of the infraspinatus and teres minor muscles.

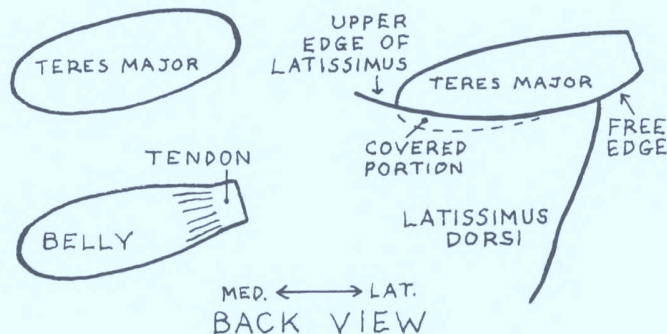
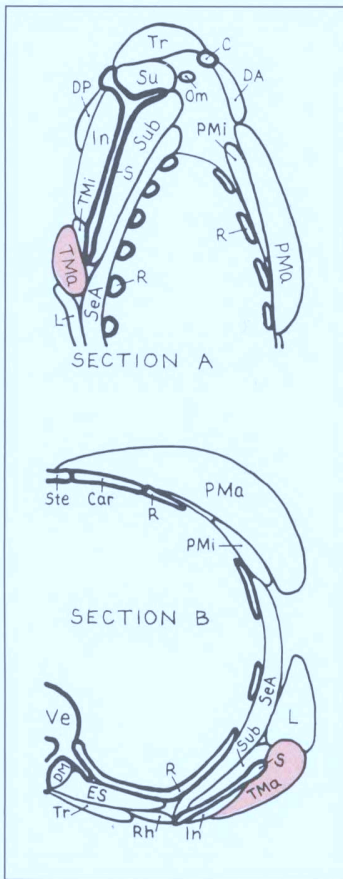
INSERTION A short vertical line on the medial lip of the bicipital groove (intertubercular sulcus) on the inside front corner of the humerus, one-fourth of the way down the humerus (medial to and slightly lower than the insertion of the latissimus dorsi).

ACTION Adducts and medially rotates the arm; extends the flexed arm. Note: the teres major and minor both adduct the arm, but are antagonists for rotation of the humerus—the major rotates it medially; the minor, laterally.

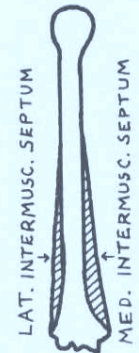
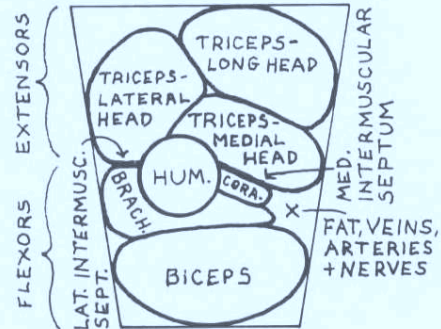
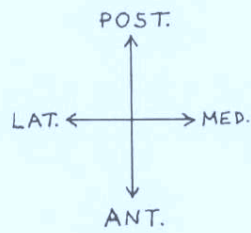
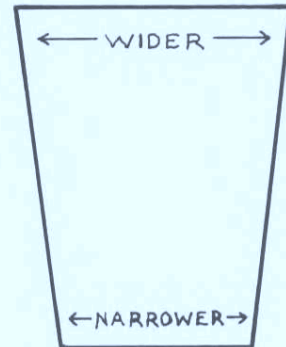
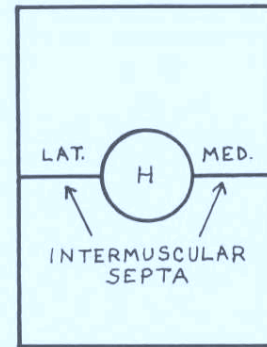
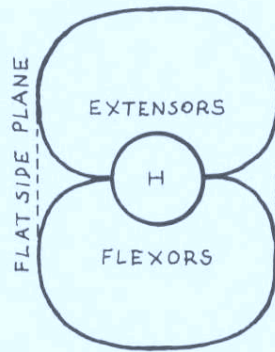
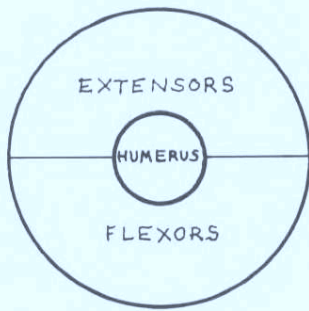
STRUCTURE The teres major is a cylindrical, but somewhat flattened, thick, bulging muscle. Laterally, it flattens into a broad tendon as it inserts. The medial end of the belly does not quite reach the medial border of the scapula. The teres major creates part of the posterior wall of the armpit, crossing from the bottom of

the back of the shoulder (bottom of the scapula) to the *inside front corner* of the arm. Diving into the armpit, its axis is directed outward, upward, and forward. When the arm lies against the body and the teres major is tensed, the belly is shortened, becoming oval and bulged (the infraspinatus and teres minor are flattened and planar). In this position, the teres major may not appear to be directed toward the inner front corner of the humerus, but it ultimately is. In the raised arm position, the stretched teres major becomes noticeably longer and thinner, and the upper edge of the latissimus dorsi can often be seen as a raised relief lying across its belly. The latissimus covers the lower medial portion of the teres major.

Because the teres major inserts lower (distal) onto the humerus than does the latissimus, the cylindrical form of the teres major can be seen as it leaves the sling of latissimus, giving the posterior wall of the armpit a double convex curve—the teres major is seen closer to the arm (lateral and higher) and latissimus closer to the body (medial and lower). This is best seen when the arm is held horizontal out to the side of the body (see Latissimus Dorsi).



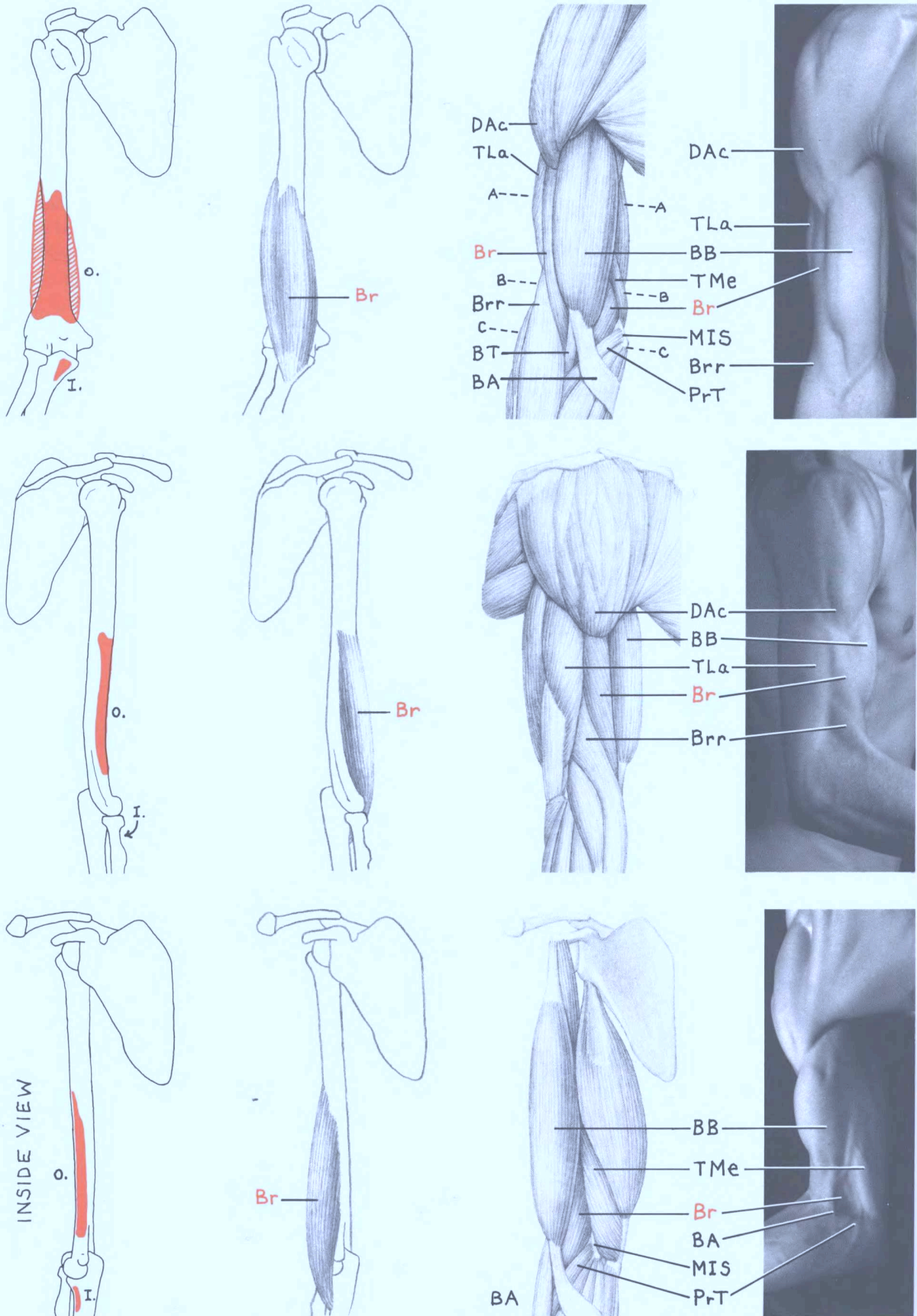
The Upper Arm Muscles



CROSS SECTIONS (MID ARM)

RIGHT HUMERUS
FRONT VIEW

The Upper Arm Muscles • BRACHIALIS



BA Bicipital aponeurosis BB Biceps brachii Br Brachialis Brr Brachioradialis BT Biceps tendon
Co Coracobrachialis Cp Capitulum DAc Deltoid—acromial portion H Humerus
MIS Medial intermuscular septum PrT Pronator teres TLa Triceps—lateral head
TMe Triceps—medial head Tro Trochlea

The Upper Arm Muscles • BRACHIALIS

Brachialis

ORIGIN Lower half of the anterior surface of the shaft of the humerus (the upper end of the origin continues around to the lateral side of the bone, embracing the insertion of deltoid), and from both the lateral and medial intermuscular septa.

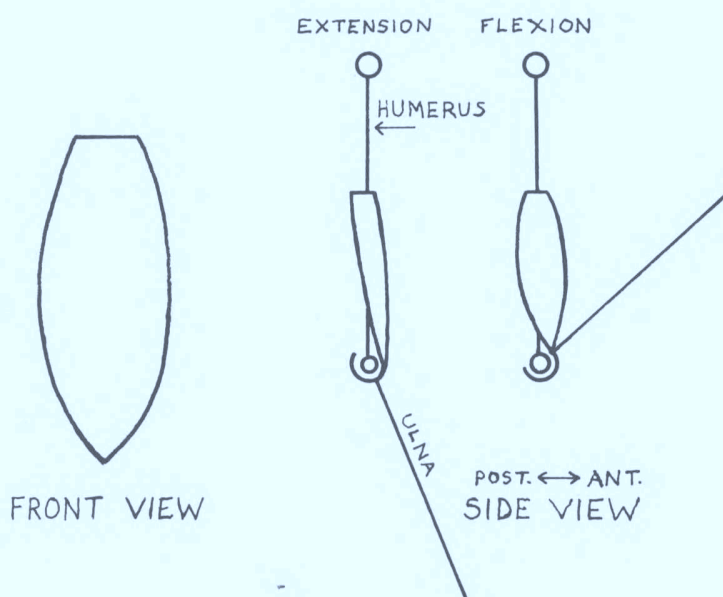
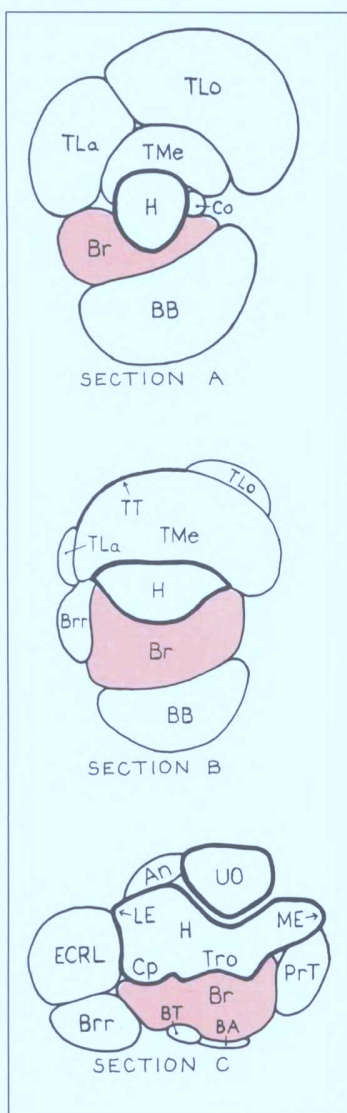
INSERTION Anterior surface of the coronoid process of the ulna.

ACTION Flexes the forearm.

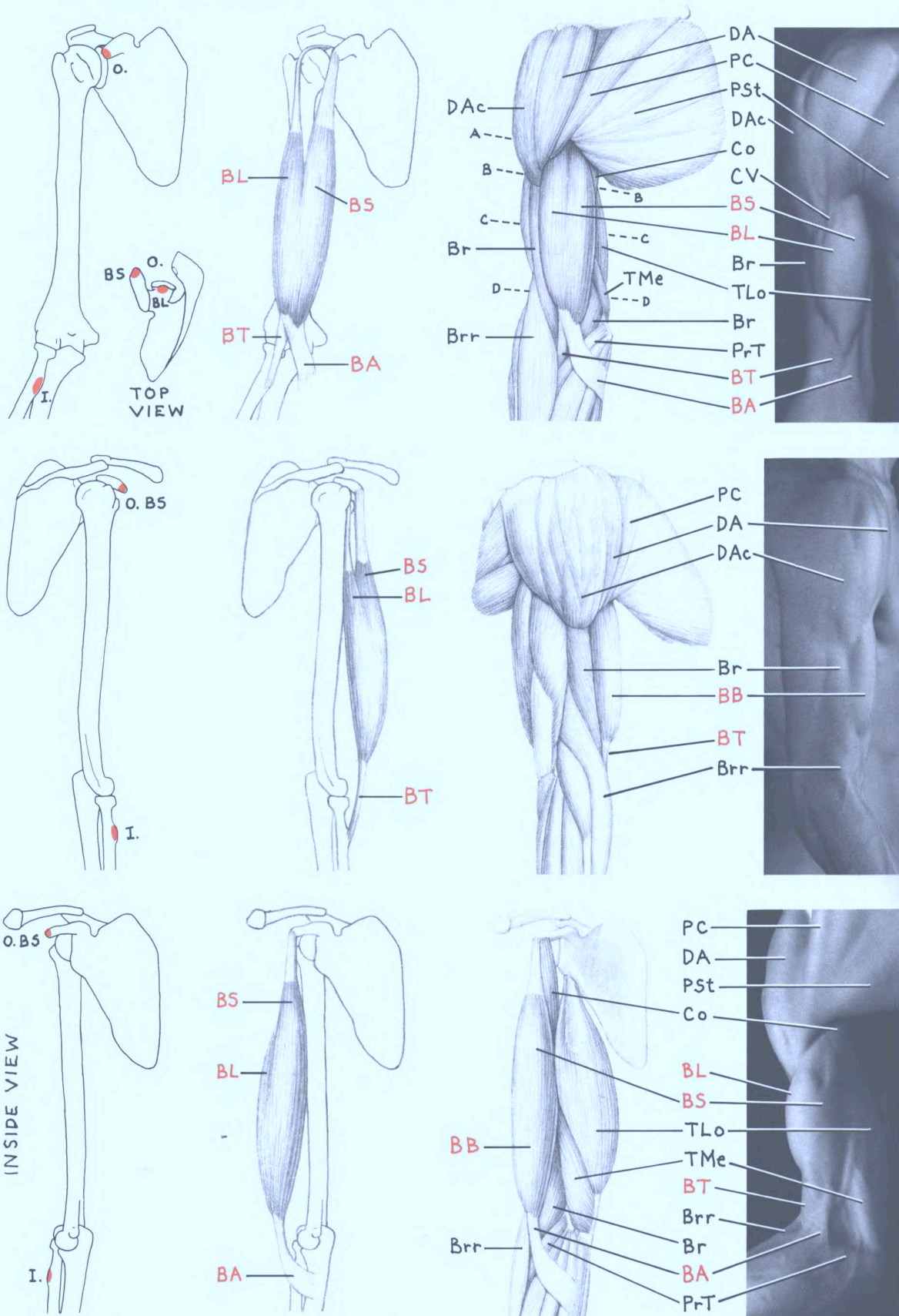
STRUCTURE Lying under the biceps and in front of the elbow joint, this relatively wide, fleshy muscle is seen only on the outside of the upper arm. The narrow visible portion passes obliquely downward and forward, first between the biceps and triceps and then between the biceps and brachioradialis. Its obliquity increases as the elbow is flexed; it also becomes shorter and rounder during elbow flexion, appearing as an oval relief on the outside of the arm at full flexion. The brachialis lies on and adds muscular fullness to the front of the lower half of the

humerus. Its front surface is somewhat flattened to receive the flattened posterior surface of the biceps. The fibers at the upper outer end of the brachialis blend directly with some of the inserting fibers of the deltoid. A depression may appear at this fusion.

On the inside of the arm, the brachialis is concealed by nerves, arteries, veins, and especially fat. When the elbow is partially flexed and the muscles tensed, this area appears as a flat plane, bordered in front by the biceps and the raised medial edge of the bicipital aponeurosis and behind by the medial head of the triceps. The brachialis may occasionally be seen in this area as a recessed bulge, but it is always covered by blood vessels and fat that protects these vessels. When the elbow is fully extended, this portion of the brachialis is pushed forward at the elbow joint by the underlying trochlea of the humerus. It is still not seen independently; however, this area becomes fuller as it is pushed forward.



The Upper Arm Muscles • BICEPS BRACHII



BA Bicipital aponeurosis BB Biceps brachii BL Biceps brachii—long head Br Brachialis
 Brr Brachioradialis BS Biceps brachii—short head BT Biceps tendon Co Coracobrachialis
 CV Cephalic vein D Deltoid DA Deltoid—anterior portion DAc Deltoid—acromial portion
 H Humerus PC Pectoralis—clavicular portion PMA Pectoralis major PrT Pronator teres
 PSt Pectoralis—sternocostal portion TLo Triceps—long head TMe Triceps—medial head

Biceps Brachii

ORIGIN *Long head:* Supraglenoid tubercle on the top of the glenoid fossa (socket) of the scapula. *Short head:* Tip of the coracoid process of the scapula (in common with the coracobrachialis).

INSERTION Tuberosity of the radius. The biceps has no attachment to the humerus—it has two origins from the scapula and one insertion into the radius.

ACTION Flexes and/or supinates the forearm. Supination is most powerful when the forearm has been flexed to 90°. It also assists in flexing the arm in front of the body at the shoulder joint. The long head holds the head of the humerus in its socket, which also keeps the head away from the acromion when the arm is abducted.

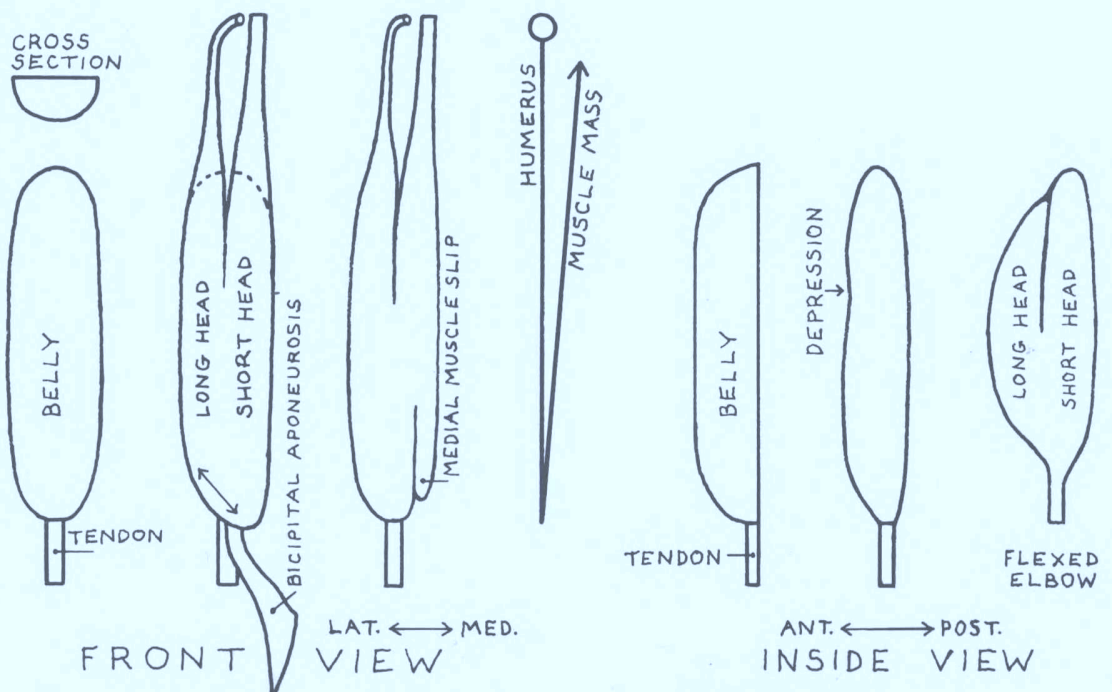
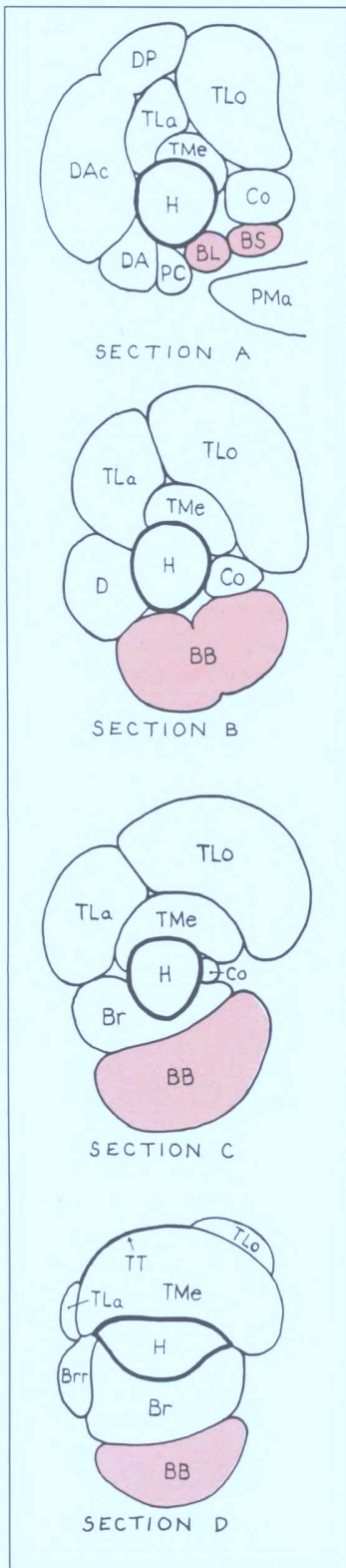
STRUCTURE The fusiform fleshy belly of the biceps is divided into a long and a short head. In its entirety, it extends from the shoulder to the elbow. Emerging from the under the pectoralis major, the belly expands into its familiar bulging shape and ends abruptly into a very strong, narrow tendon. This tendon inserts deep in the elbow between the extensor and flexor masses of the forearm.

The front profile of the biceps (seen in side view) is straight for a considerable length when the elbow is extended, but becomes quite rounded and bulging when the elbow is fully

flexed. The deep posterior surface of the belly of the biceps is flattened where it lies on the brachialis. The separation between the heads, which at times may extend all the way down the belly, is usually not very pronounced. The different characteristics of the two bellies can be seen at the upper end of the belly when the elbow is fully flexed—the long head is fuller, more rounded, and directed toward the head of the humerus, whereas the short head is more elongate and directed toward the armpit.

At the inferior end of the muscle, the fibers at the medial side of the belly descend lower than those of the lateral side. The medial portion of the belly may further divide longitudinally, forming a narrow, elongated muscle slip on its extreme medial edge. This is not the separation between the medial and lateral heads.

The **bicipital aponeurosis** (lacertus fibrosus) is a broad, sheetlike, aponeurotic expansion which originates off the anterior surface of the muscle fibers on the medial side of the lower end of the biceps and off the front surface of the upper portion of its tendon (it lies medial to the tendon of insertion of the biceps). It fans out downward and medially, wrapping around and constricting the bulging form of the forearm flexor mass a couple of inches below their origin at the medial epicondyle of the humerus. The constricting action of the aponeurosis creates either a wide or narrow furrow, or a flattening, on the forearm flexor mass, so that the flexor mass bulges above and below the apo-



The Upper Arm Muscles • CORACOBRACHIALIS

Coracobrachialis

ORIGIN Tip of the coracoid process of the scapula (in common with the short head of the biceps).

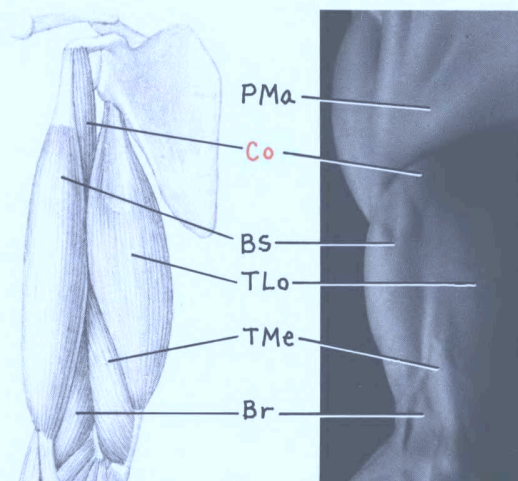
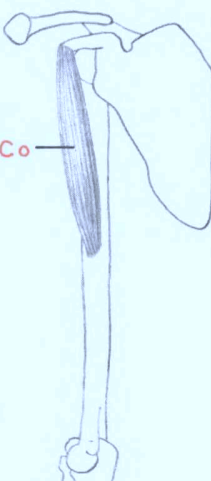
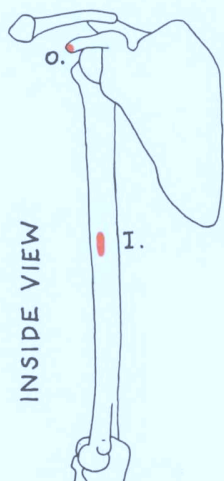
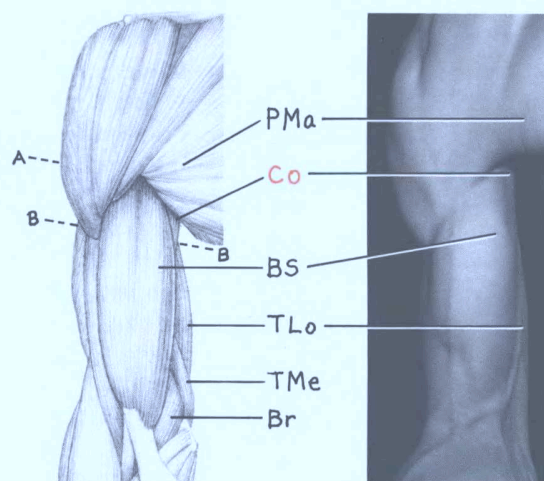
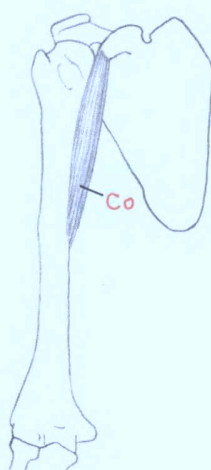
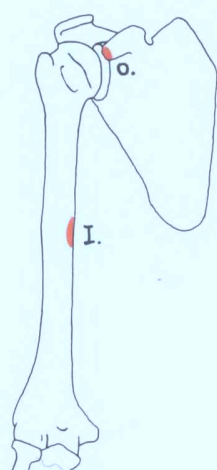
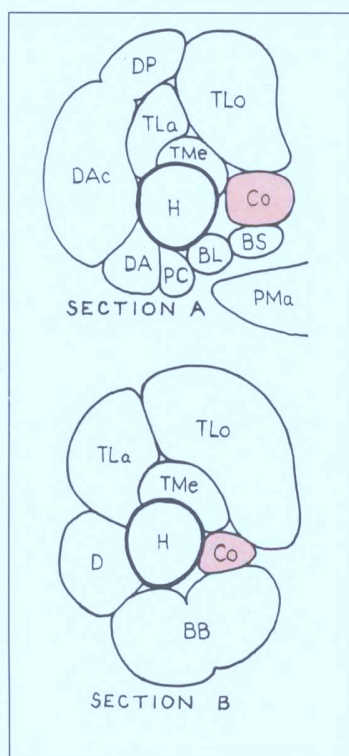
INSERTION Short vertical line halfway down the humerus on its medial surface.

ACTION Flexes and adducts the arm at the shoulder joint.

STRUCTURE The coracobrachialis is a thick cylindrical muscle that is partially seen on the inside of the upper end of the raised arm, near

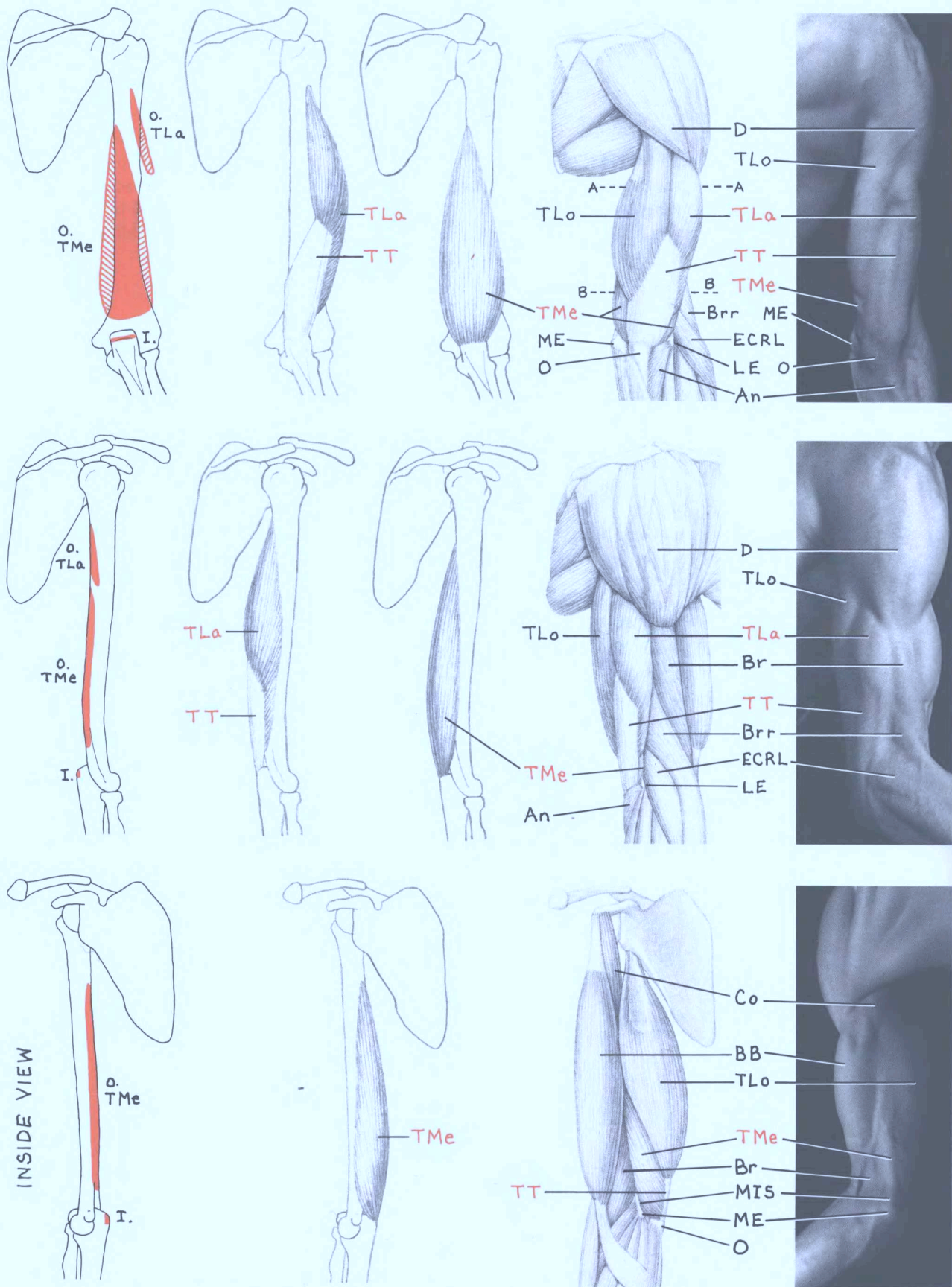
the armpit. It runs alongside, but separate from, the short head of the biceps. The belly of the coracobrachialis is seen on the surface for only a short distance before it dives deeply between the biceps and the medial head of the triceps. The short head of the biceps covers most of the anterior surface of the coracobrachialis.

The coracobrachialis and biceps are separated from the triceps by a groove within which lie the nerves and blood vessels (surrounded by fat) of the arm.

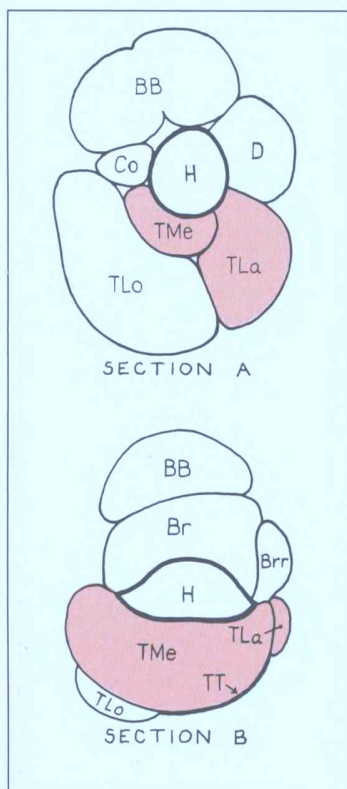


BB Biceps brachii Br Brachialis BS Biceps brachii—short head Co Coracobrachialis H Humerus
PMa Pectoralis major TLo Triceps—long head TMe Triceps—medial head

The Upper Arm Muscles • TRICEPS BRACHII—LATERAL AND MEDIAL HEADS



An Anconeus BB Biceps brachii Br Brachialis Brr Brachioradialis Co Coracobrachialis
D Deltoid ECRL Extensor carpi radialis longus H Humerus LE Lateral epicondyle
ME Medial epicondyle MIS Medial intermuscular septum O Olecranon TLa Triceps—lateral head
TLo Triceps—long head TMe Triceps—medial head TT Triceps tendon



Triceps Brachii—Lateral and Medial Heads

ORIGIN *Lateral head:* A vertical line on the outer back corner of the shaft of the humerus, beginning just below the head of the humerus and ending almost halfway down the bone, and the adjacent lateral intermuscular septum. *Medial head:* A large, elongated, triangular area occupying the lower portion of the back surface of the humerus, which extends upward on the medial side of the back surface of the shaft, and from the posterior surfaces of part of the lateral intermuscular septum and all of the medial intermuscular septum.

INSERTION *Lateral head:* Upper two-thirds of the lateral edge and deep aspect of the upper portion of the triceps tendon. *Medial head:* Lower third of both the medial and lateral edges and the lower portion of the deep aspect of the triceps tendon. The triceps tendon inserts into the horizontal posterior edge of the top of the olecranon process of the ulna.

ACTION Powerfully extend the forearm at the elbow joint.

STRUCTURE The majority of the superficial portion of the **lateral head** appears as an elliptical or teardrop-shaped form located on the middle third of the outer back corner of the upper arm (more on the side than on the back). The remaining fibers of the lateral head continue down the lateral edge of the triceps tendon, from the bottom of the teardrop, as a descending “tail.” These fibers insert into the edge of the tendon in an irregular fashion. When the triceps extends the elbow joint, the elongated muscular ridge of the tail appears as a narrow inverted cone. The lateral head can easily be seen from the front view.

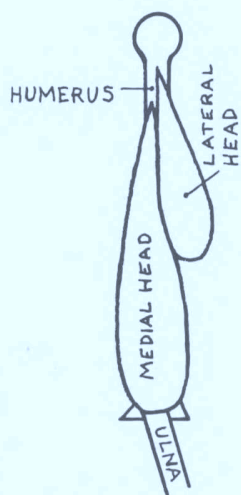
The **medial head** by itself is a flattened teardrop shape, pointed superiorly, that curves around the back of the lower half of the humerus (side to side, see cross section). Because it is mostly covered by the long head and the triceps

tendon, it is seen on the surface as a long, narrow, cylindrical form on the *lower half* of the inner back corner of the upper arm. It can sometimes be seen from the front view. Superiorly, this form dives deeply between the long head of the triceps and the biceps to reach the upper extent of its attachment on the humerus; it never appears on the surface on the *upper half* of the inside of the upper arm.

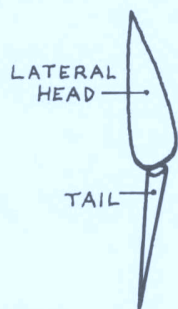
A large part of the medial head lies under the triceps tendon. Although a narrow portion comes to the surface past the lateral edge of the tendon, the medial head is usually not distinct there, but may add to the form of the lower end of the tail of the lateral head. Most of the fibers of the medial head attach to the deep aspect of the tendon, but some of them actually insert into the olecranon directly.

On either side of the humerus, the medial head takes origin from the posterior surfaces of the **intermuscular septa**. The subcutaneous edges of the medial and lateral intermuscular septa can occasionally be seen on the surface—medially as a short, thin, cordlike elevation ascending from the medial epicondyle of the humerus (easily felt when the elbow is fully extended) and laterally as a short ridge rising from the lateral epicondyle of the humerus (when the elbow joint is flexed 90° and extended against resistance). The edge of the lateral intermuscular septum lies *anterior* to the lateral edge of the triceps tendon (just above the elbow), and the two may or may not be separated by the muscular fibers of the tail of the lateral head. Inferiorly, the intermuscular septum attaches to the lateral epicondyle, whereas the triceps tendon attaches to the olecranon or onto the surface of the anconeus.

Because the lateral and medial heads originate in part from the lateral and medial intermuscular septa, the width of the belly of the triceps is greater than the width of its origin from the humerus.

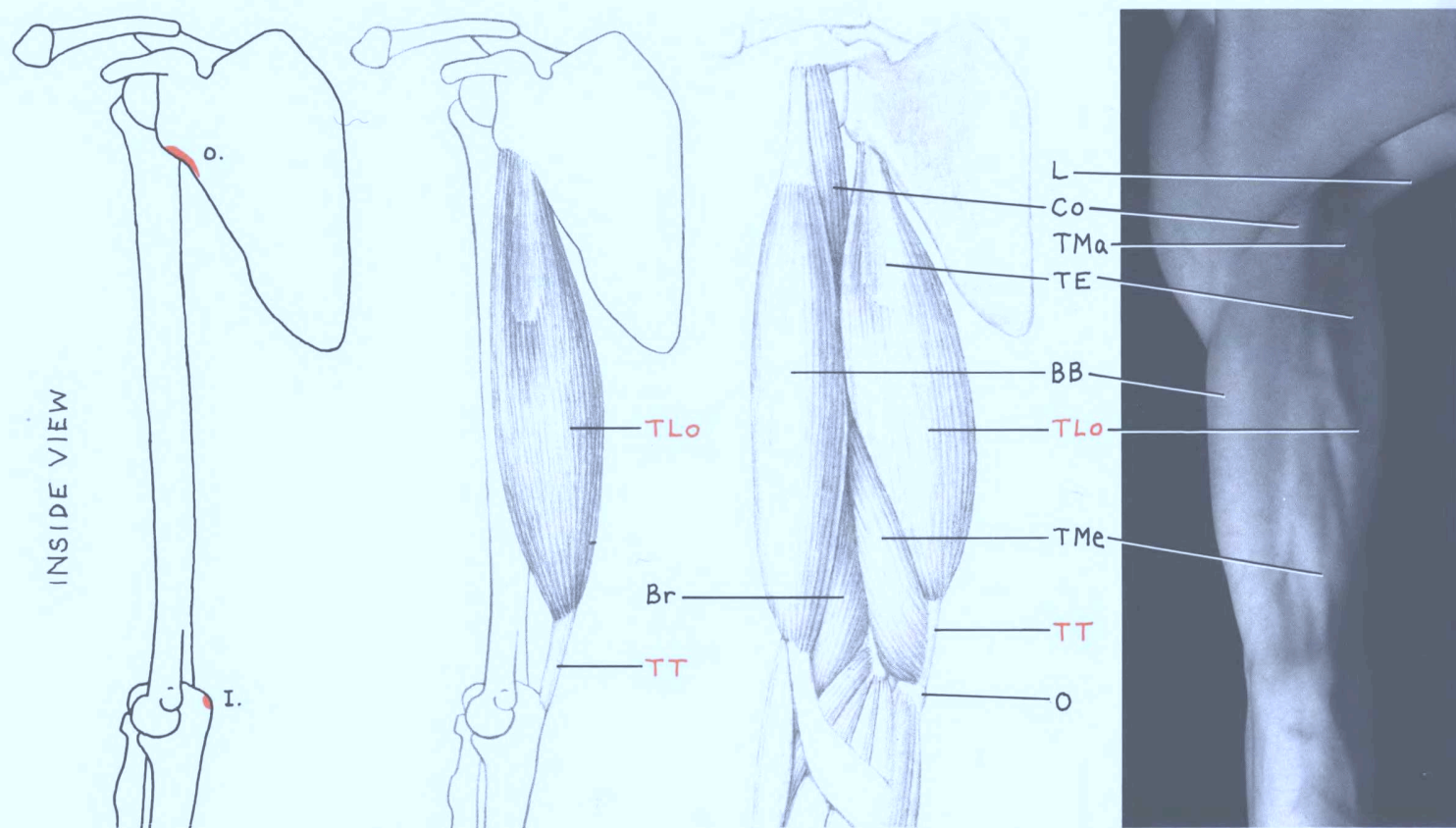
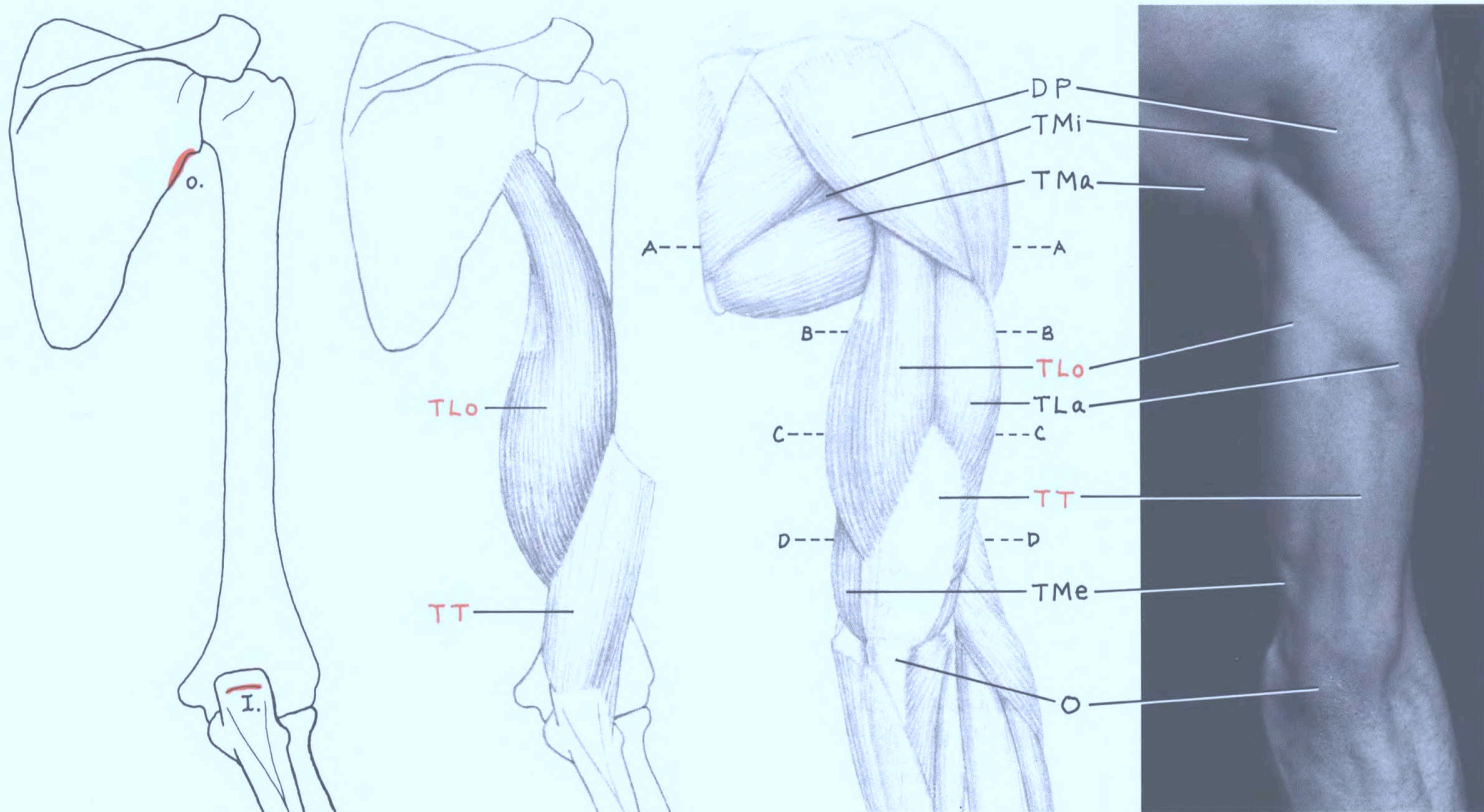


MED. ← → LAT.



BACK VIEW

The Upper Arm Muscles • TRICEPS BRACHII—LONG HEAD



BB Biceps brachii Br Brachialis Co Coracobrachialis D Deltoid DP Deltoid—posterior portion
H Humerus L Latissimus dorsi O Olecranon TE Tendinous expansion TLa Triceps—lateral head
TLo Triceps—long head TMa Teres major TMe Triceps—medial head TMi Teres minor
TT Triceps tendon

The Upper Arm Muscles • TRICEPS BRACHII—LONG HEAD

Triceps Brachii—Long Head

ORIGIN Infraglenoid tubercle at the bottom of the socket of the scapula and a short distance below it along the lateral (axillary) border of the scapula. It does not originate from the humerus.

INSERTION Upper two-thirds of the medial edge of the tendon of insertion of the triceps, which in turn inserts into the horizontal posterior edge of the top of the olecranon process of the ulna.

ACTION Extends the forearm at the elbow joint; extends the arm from a previously flexed position at the shoulder joint.

STRUCTURE Largest of the three heads of the triceps, this flattened, teardrop-shaped head is located on the inner back corner of the upper arm. It descends three-fourths of the way down the arm. The inferior end of the head is pointed.

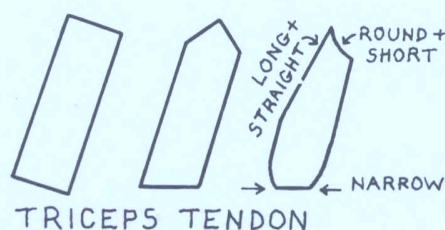
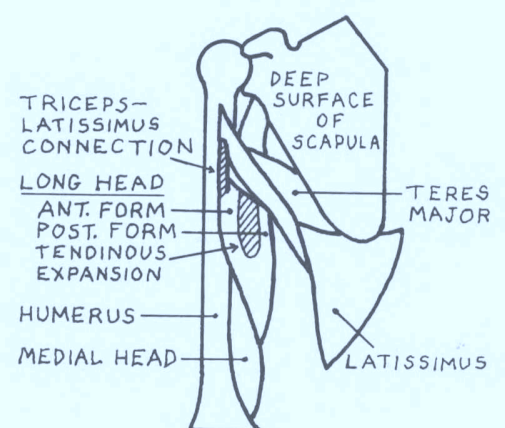
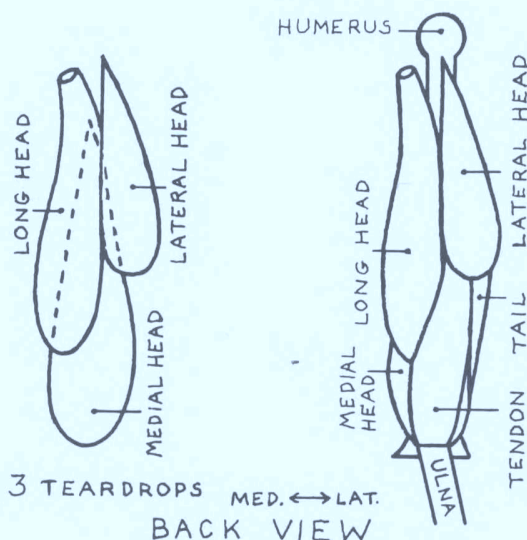
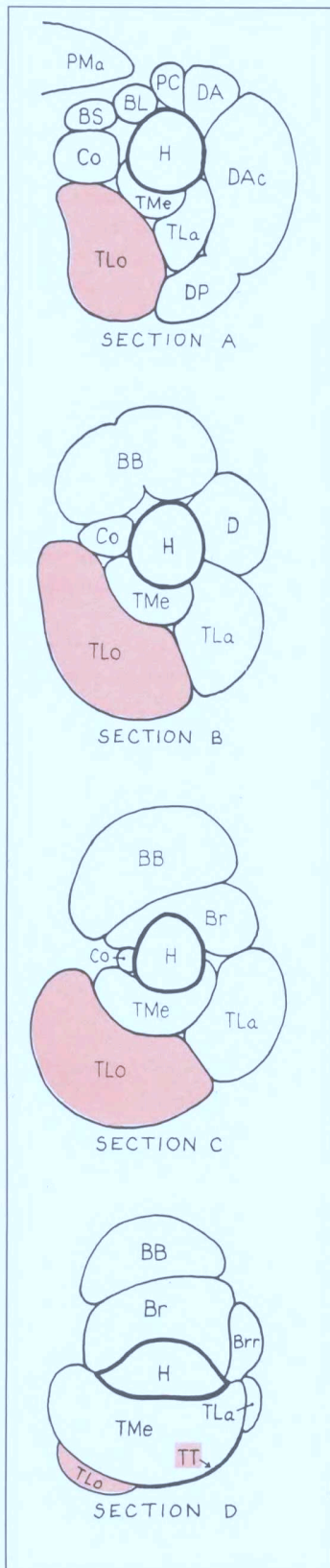
At the upper portion of the *inside* of the arm, the volume of the long head projects quite far forward, reaching almost three-fourths of the way toward the front of the arm. The upper end of the long head (maintaining a wide, fleshy thickness) dives *between the teres major and teres minor muscles* toward its attachment on the scapula. With the arm down by the side, the

upper portion of the long head, just before it disappears between the teres muscles, is crossed by an almost vertical skin fold (running perpendicular to the long head muscle fibers).

As the long head emerges from between the teres muscles, it is flattened from above to below. It then twists medially, flattens considerably side to side, and expands front to back. Thin, tendinous material coming off the origin of the long head at the scapula descends and expands onto the surface of the upper part of this flattened head (on the medial aspect of the arm). This nonelastic material compresses the fleshy head when it is tensed, creating a wide vertical furrow that separates the upper end of the long head into anterior and posterior forms. The elongated anterior form, *part of the long head*, is commonly mistaken for the medial head of the triceps.

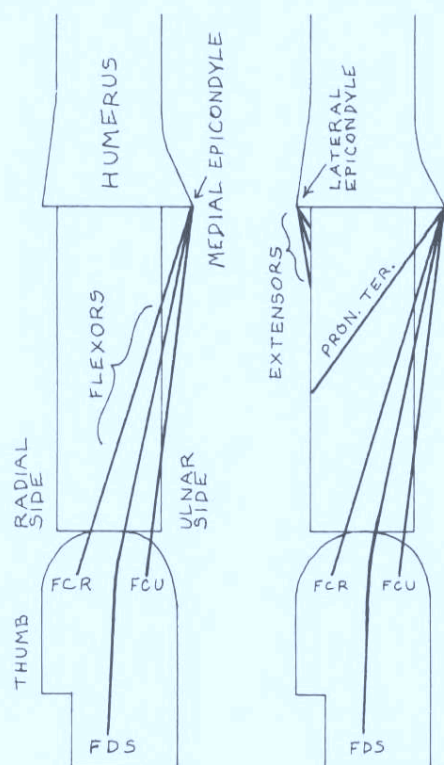
In the inside view of the upper arm, the entire triceps muscle is seen to have a double curve along its front edge—the long head curves anteriorly on the upper half of the arm, the medial head curves anteriorly on the lower half.

In the armpit, there is usually a tendinous and/or muscular connection, the **triceps-latissimus connection**, between the *anterior edge* of the long head of the triceps and the tendon of the latissimus dorsi near its insertion. This connection represents the dorsoepitrochlearis bra-



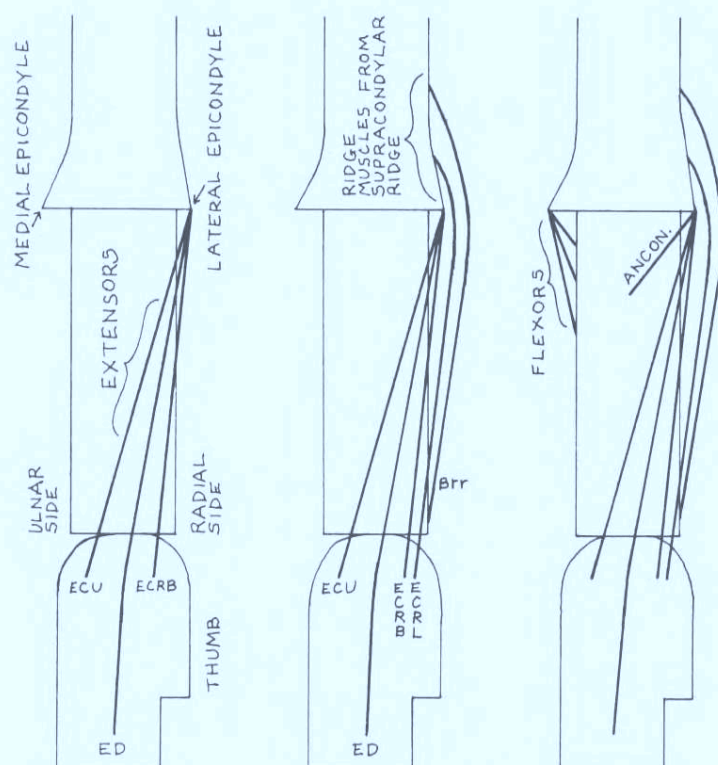
The Forearm Muscles

SUPINATED RIGHT FOREARM



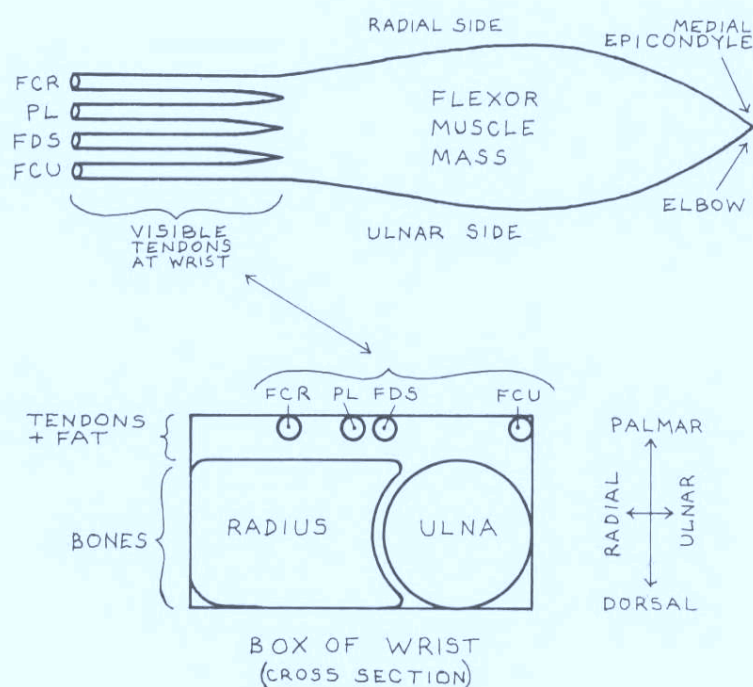
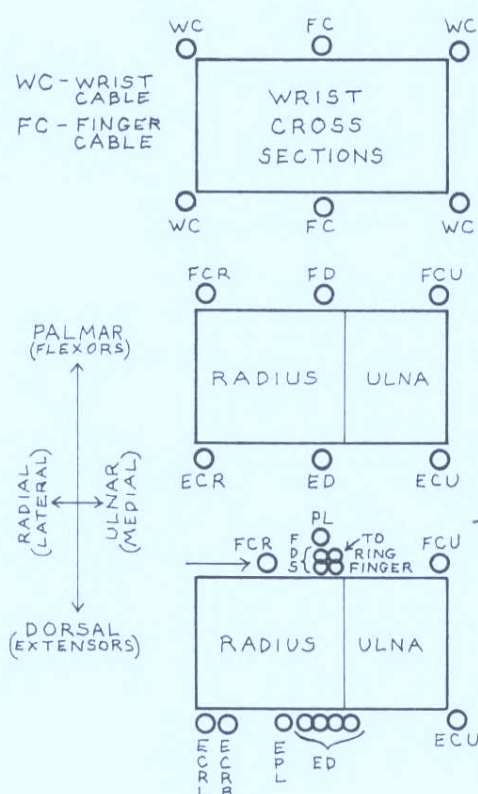
ANTERIOR (PALMAR) VIEW

LAT. ← MED.



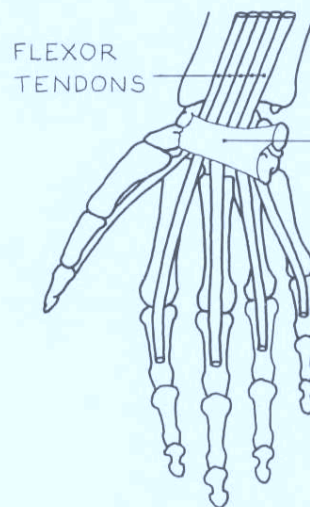
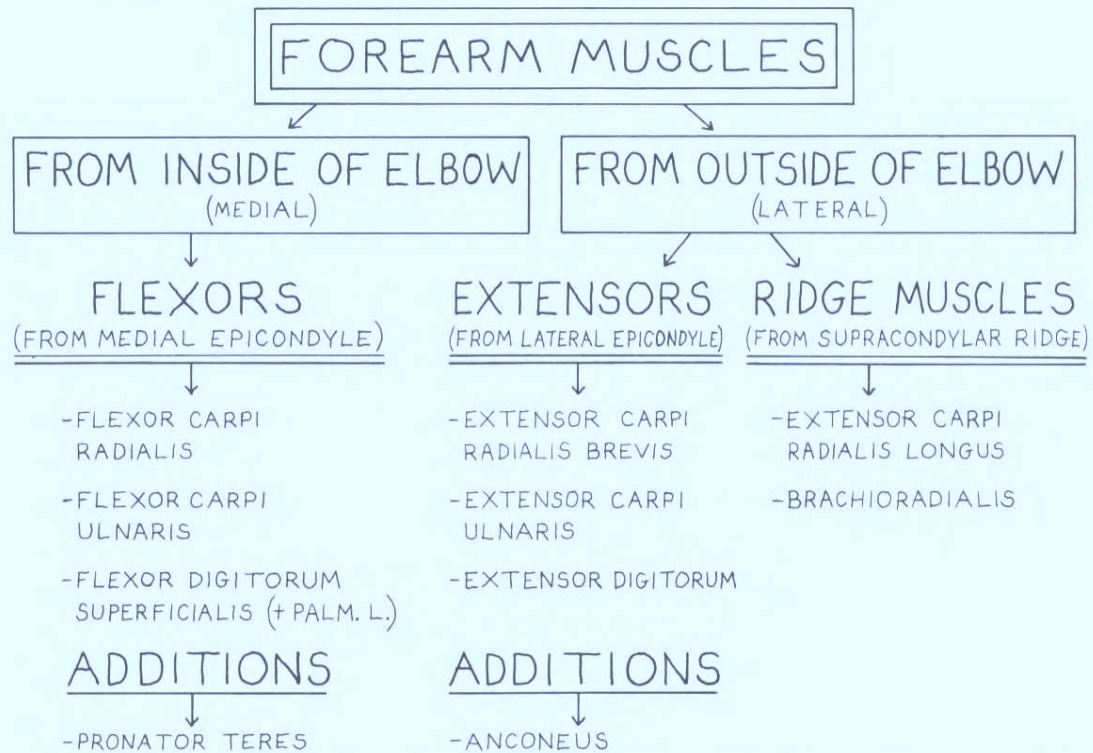
POSTERIOR (DORSAL) VIEW

MED. ← LAT.

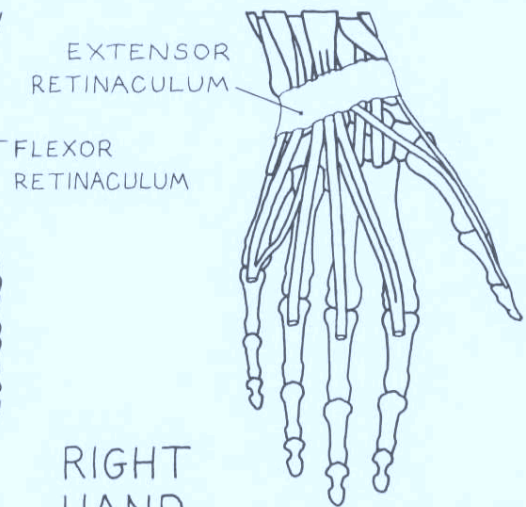


Brr Brachioradialis ECR Extensor carpi radialis ECRB Extensor carpi radialis brevis
 ECRL Extensor carpi radialis longus ECU Extensor carpi ulnaris ED Extensor digitorum
 EPL Extensor pollicis longus FCR Flexor carpi radialis FCU Flexor carpi ulnaris FD Flexor digitorum
 FDS Flexor digitorum superficialis PL Palmaris longus

The Forearm Muscles



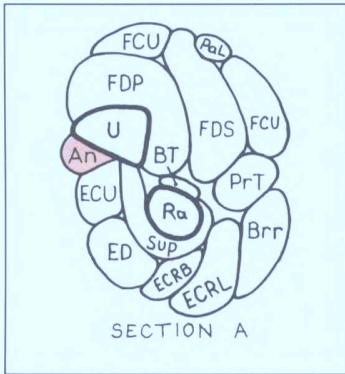
PALM VIEW



DORSAL (BACK) VIEW

RIGHT
HAND

The Forearm Muscles • ANCONEUS



SECTION A



Anconeus

ORIGIN By its own separate tendon from the bony surface *behind and inferior to* the lateral epicondyle of the humerus.

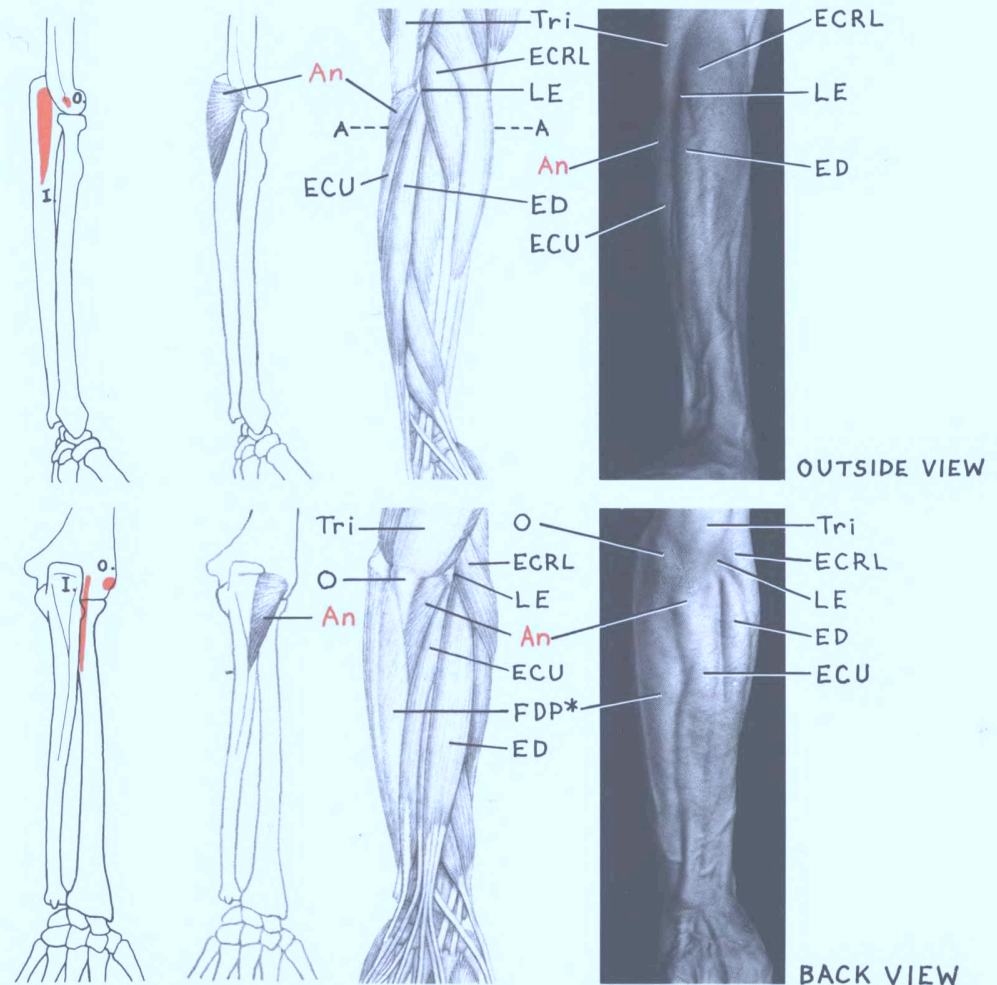
INSERTION Lateral surface of the olecranon, continuing down the upper fourth of the posterolateral surface of the ulna.

ACTION Extends and stabilizes the elbow joint.

STRUCTURE The anconeus is a small triangular muscle located on the outer back corner of the elbow, below the elbow joint. It fills the space between the lateral epicondyle and olecranon and then continues one-fourth of the way down the forearm. Its belly is sharply pointed inferiorly. The anconeus does not cover the head of the radius.

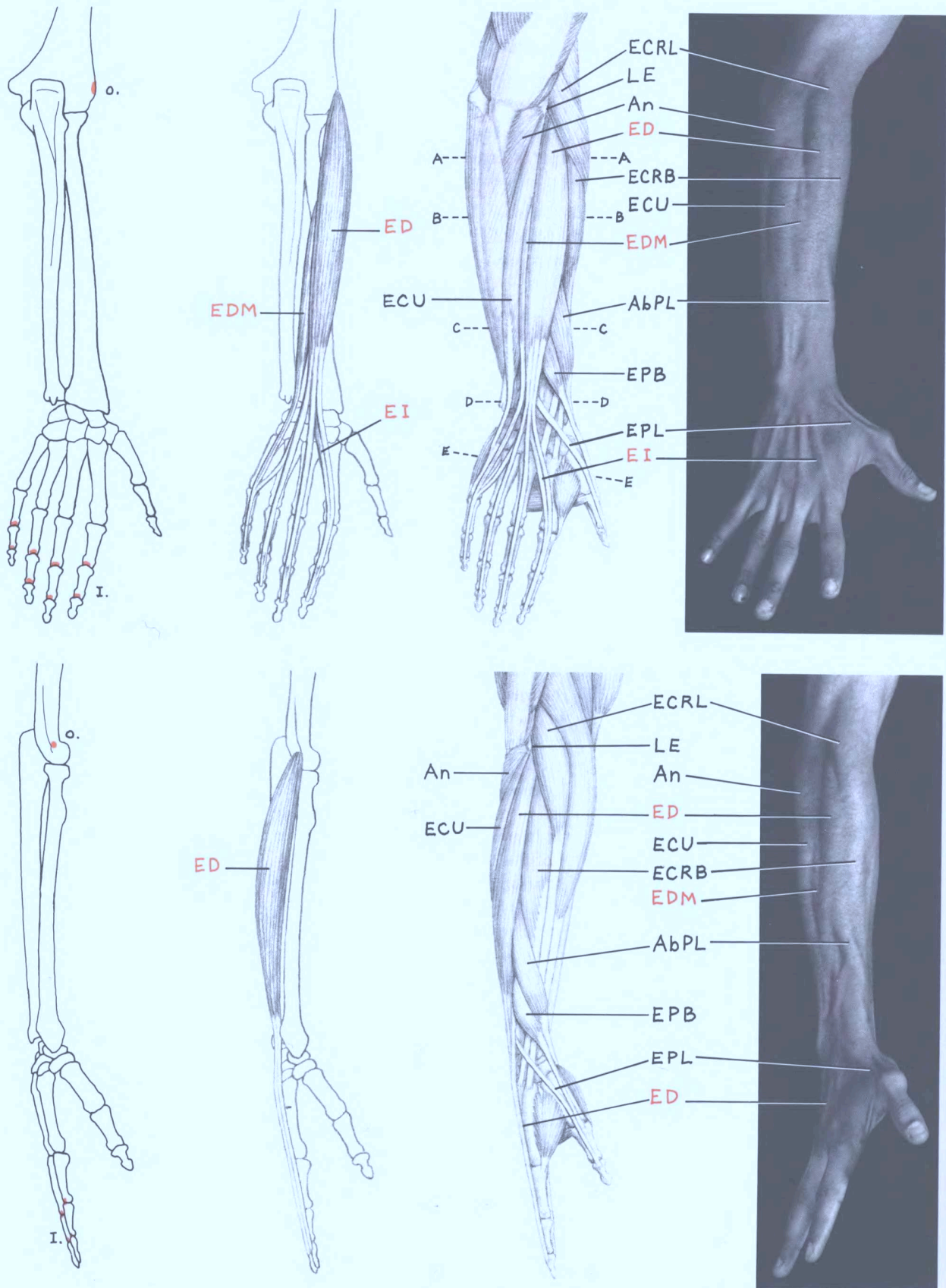
When the elbow joint is fully extended, the anconeus creates a distinct, bulging, low relief, quite separate from the forms of the triceps and the muscles originating from the lateral epicondyle of the humerus. The anconeus flattens as the elbow is flexed. The posterior edge of the upper half of its insertion is in contact with the ulna, while its lower half lies up against the flexor muscles of the forearm. The upper edge of the anconeus is in contact with the medial head of the triceps.

Aponeurotic fibers from the lateral edge of the triceps tendon continue downward onto the surface of the anconeus. These tendinous fibers may affect its form by creating a furrow or by producing a ridge.



An Anconeus ECRL Extensor carpi radialis longus ECU Extensor carpi ulnaris
ED Extensor digitorum FDP Flexor digitorum profundus LE Lateral epicondyle O Olecranon
Ra Radius Tri Triceps U Ulna * Under flexor carpi ulnaris

The Forearm Muscles • EXTENSOR DIGITORUM

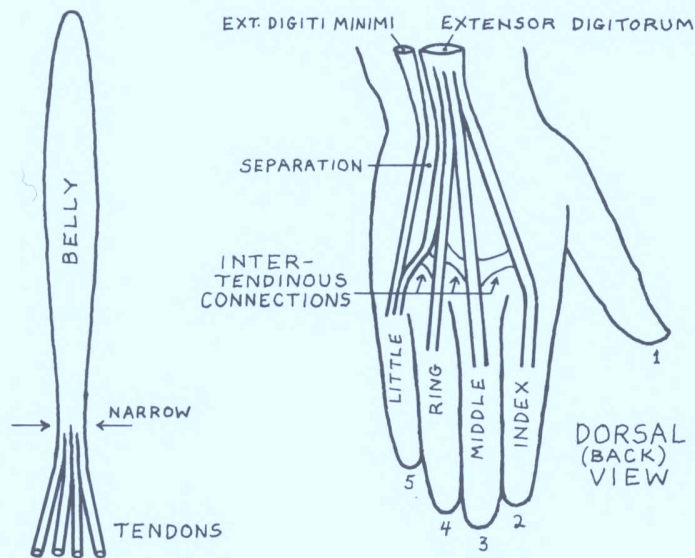
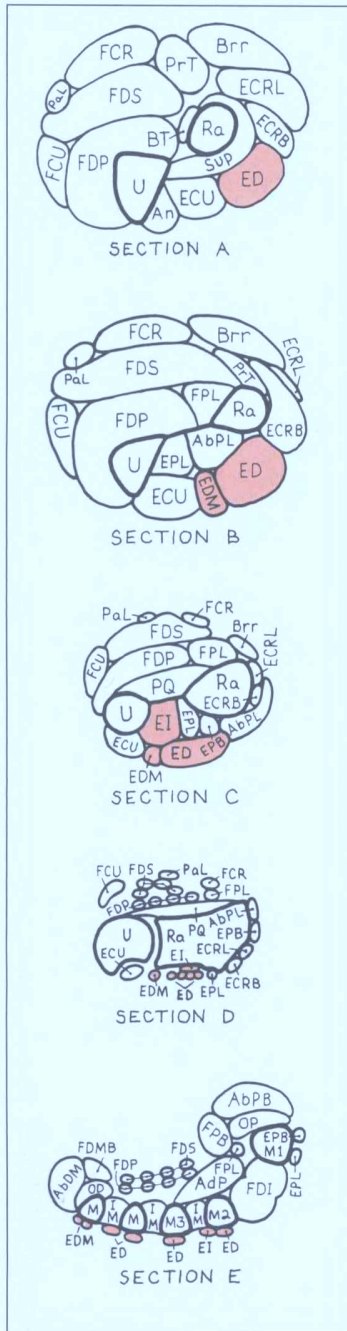


AbPL Abductor pollicis longus An Anconeus ECRB Extensor carpi radialis brevis
 ECRL Extensor carpi radialis longus ECU Extensor carpi ulnaris ED Extensor digitorum
 EDM Extensor digiti minimi EI Extensor indicis EPB Extensor pollicis brevis
 EPL Extensor pollicis longus IM Interosseous muscle LE Lateral epicondyle M Metacarpal
 Ra Radius Sup Supinator U Ulna

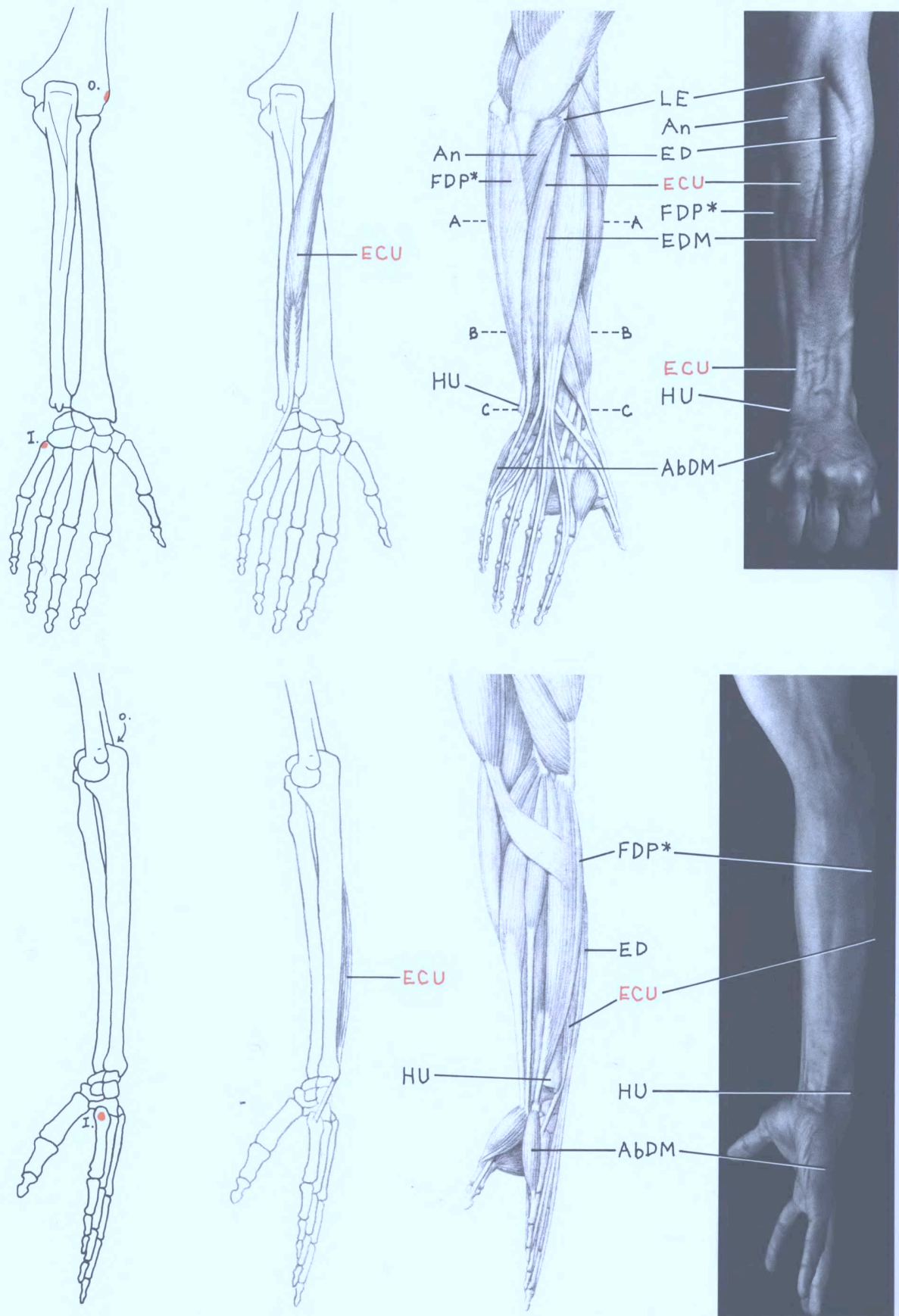
The Forearm Muscles • EXTENSOR DIGITORUM

digitorum, just proximal to the heads of the metacarpals, on the back of the hand. They limit *full* extension of one finger when an adjacent finger is flexed and conversely limit flexion of one finger when an adjacent finger is extended. The intertendinous connections are thin, wide, and flat and are rarely seen directly. Because the tendons of the extensor digitorum are layered, the intertendinous connections will pull the various layers of these tendons sideways when the fingers are flexed and extended. This reveals the layers, especially those of the middle, ring, and little fingers.

When making a fist, the tendons become dull crests on the rounded ends of the heads of the metacarpal bones. When the fingers are extended, the tendons disappear from view about one-third to one-half of the way down the back of the proximal phalanges, as they flatten into the dorsal extensor aponeurosis. The tendon to the index finger can occasionally be traced all the way down to the proximal interphalangeal joint.



The Forearm Muscles • EXTENSOR CARPI ULNARIS



AbDM Abductor digiti minimi An Anconeus ECU Extensor carpi ulnaris ED Extensor digitorum
 EDM Extensor digiti minimi EI Extensor indicis EPL Extensor pollicis longus
 FDP Flexor digitorum profundus HU Head of ulna LE Lateral epicondyle Ra Radius U Ulna
 * Under flexor carpi ulnaris

Extensor Carpi Ulnaris

ORIGIN Lateral epicondyle of the humerus (by the common extensor tendon), and by an aponeurosis along the upper two-thirds of the posterior border of the ulna.

INSERTION Tubercle on the outer surface of the base of the fifth metacarpal bone (of the little finger).

ACTION Extension and ulnar deviation of the hand at the wrist joint.

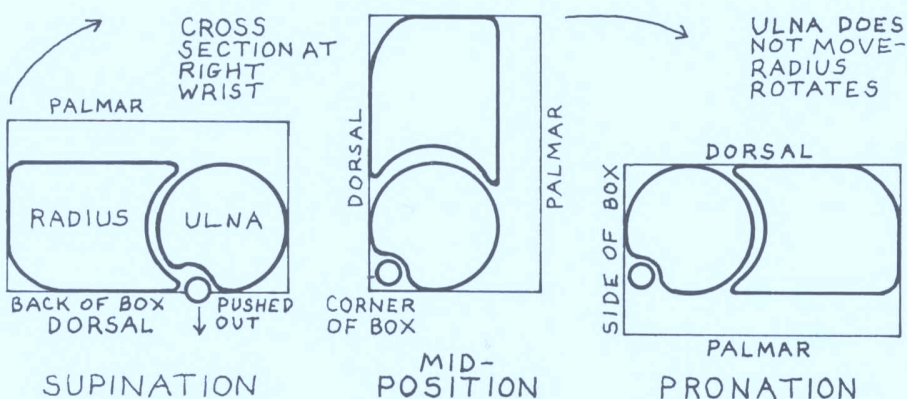

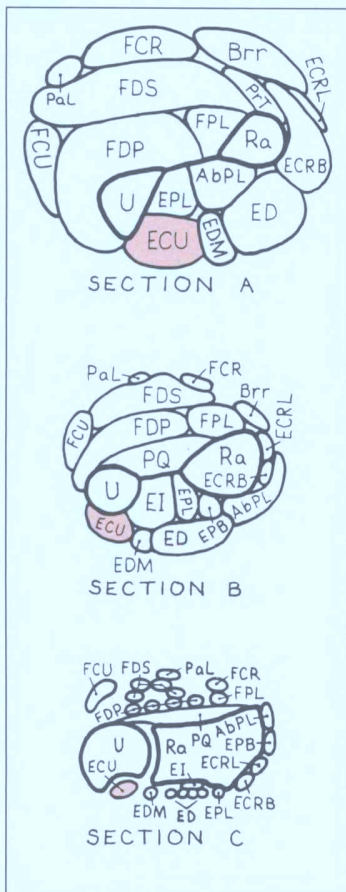
STRUCTURE The extensor carpi ulnaris is a narrow, elongated, flattened muscle, whose overall axis curves toward the ulna between its proximal and distal points of attachment. On the back of the middle third of the forearm, the extensor carpi ulnaris and forearm flexor muscles are separated by a groove, at the bottom of which lies the posterior border of the ulna.

The tendon of the extensor carpi ulnaris begins three-fourths of the way down the forearm. The muscle fibers continue down each side of the tendon, almost all the way down to the head of the ulna. The muscle and tendon may show up as a single elongated form, or the lower muscular portion may split into two elongated, parallel forms (the tendon appears recessed as a furrow). Distally, before reaching the wrist, the tendon may appear raised on the surface.

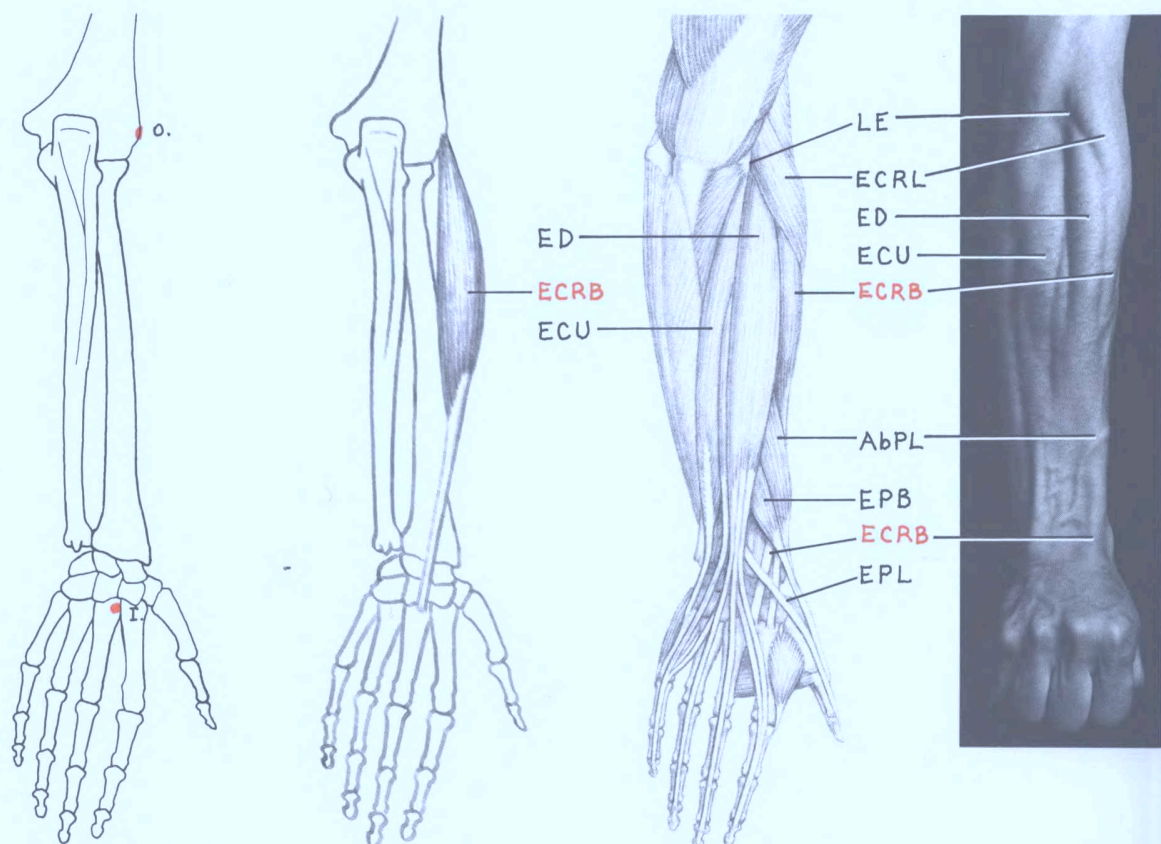
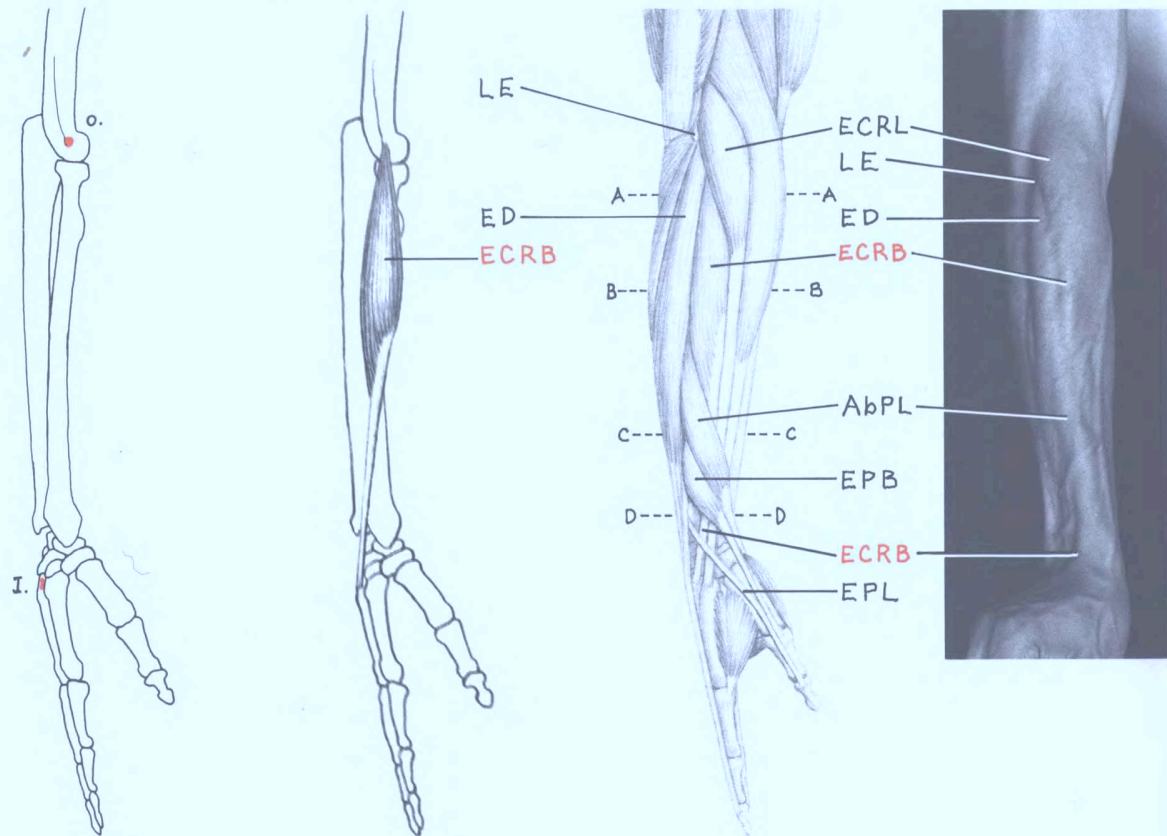
The tendon then passes through the bony groove in the head of the ulna, where it is lodged inconspicuously when the forearm is pronated. It may be seen distal to the head of

the ulna on the outer corner of the wrist as it crosses the wrist joint. The tendon becomes prominent at, above, and below the head of the ulna when the forearm is supinated. It becomes prominent during supination because the tendon is pulled slightly out of the bony groove in the head of the ulna by the rotation of its insertion point on the hand away from the head of the ulna (the ulna stays fixed and the hand rotates along with the radius during supination).

The wrist can be visualized as a box. When the forearm is pronated, the tendon of the extensor carpi ulnaris lies inconspicuously in the notch of the head of the ulna, on the *ulnar side of the box* of the wrist. During full supination, the tendon becomes raised and conspicuous and is located on the *back of the box* of the wrist. In the middle position of pronation/supination, the tendon is located in the actual *corner of the box* of the wrist, again lying inconspicuously within the notch of the head of the ulna. This shifting of the tendon relative to the box of the wrist occurs because during pronation and supination, the distal end of the radius (which is responsible for forming two planes of the box) rotates around the fixed (nonmoving) head of the ulna. Since the relationship of the tendon to the head of the ulna is also fixed (lodged in the notch), as the radius rotates it exposes different surface areas of the head of the ulna. The planes of the radius (or the surface of the box) changes its relationship to the tendon, and the tendon therefore appears in different locations on the box.



The Forearm Muscles • EXTENSOR CARPI RADIALIS BREVIS



AbPL Abductor pollicis longus ECRB Extensor carpi radialis brevis
 ECRL Extensor carpi radialis longus ECU Extensor carpi ulnaris ED Extensor digitorum
 EPB Extensor pollicis brevis EPL Extensor pollicis longus LE Lateral epicondyle PrT Pronator teres
 Ra Radius Sup Supinator U Ulna

Extensor Carpi Radialis Brevis

ORIGIN Lateral epicondyle of the humerus (by the common extensor tendon) and the radial collateral ligament of the elbow joint.

INSERTION Dorsal surface of the base of the metacarpal bone of the middle finger, toward its radial side.

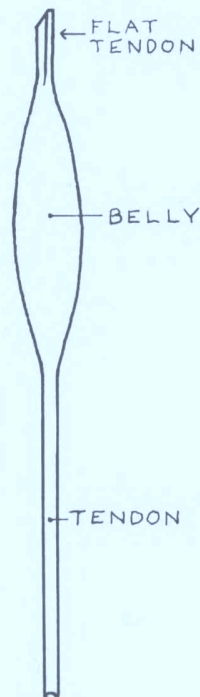
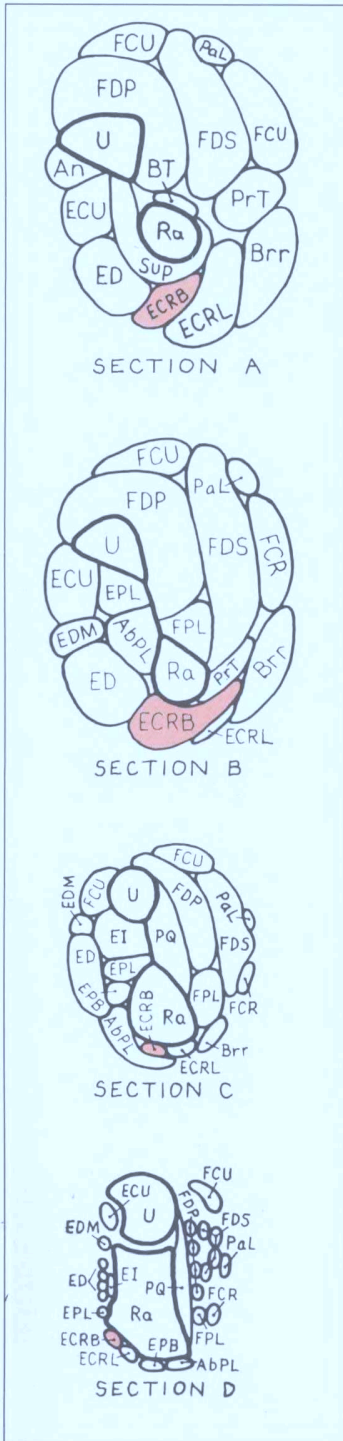
ACTION Extends and radially deviates the hand at the wrist joint.

STRUCTURE The extensor carpi radialis brevis begins proximally at the lateral epicondyle as a short, wide, flattened tendon compressed between the bellies of the extensor carpi radialis longus and extensor digitorum; its fleshy fibers, and therefore its form, do not begin at its origin at the lateral epicondyle. It soon expands into a thick fusiform belly located on the outer surface of the radius. Its fibers end halfway to two-thirds of the way down the forearm into a long, narrow, flat tendon. The belly of the extensor carpi radialis brevis therefore shows up as a well-defined fusiform relief on the extensor side of the forearm, beginning a couple of inches *below* the elbow joint and ending just below the middle of the forearm. The

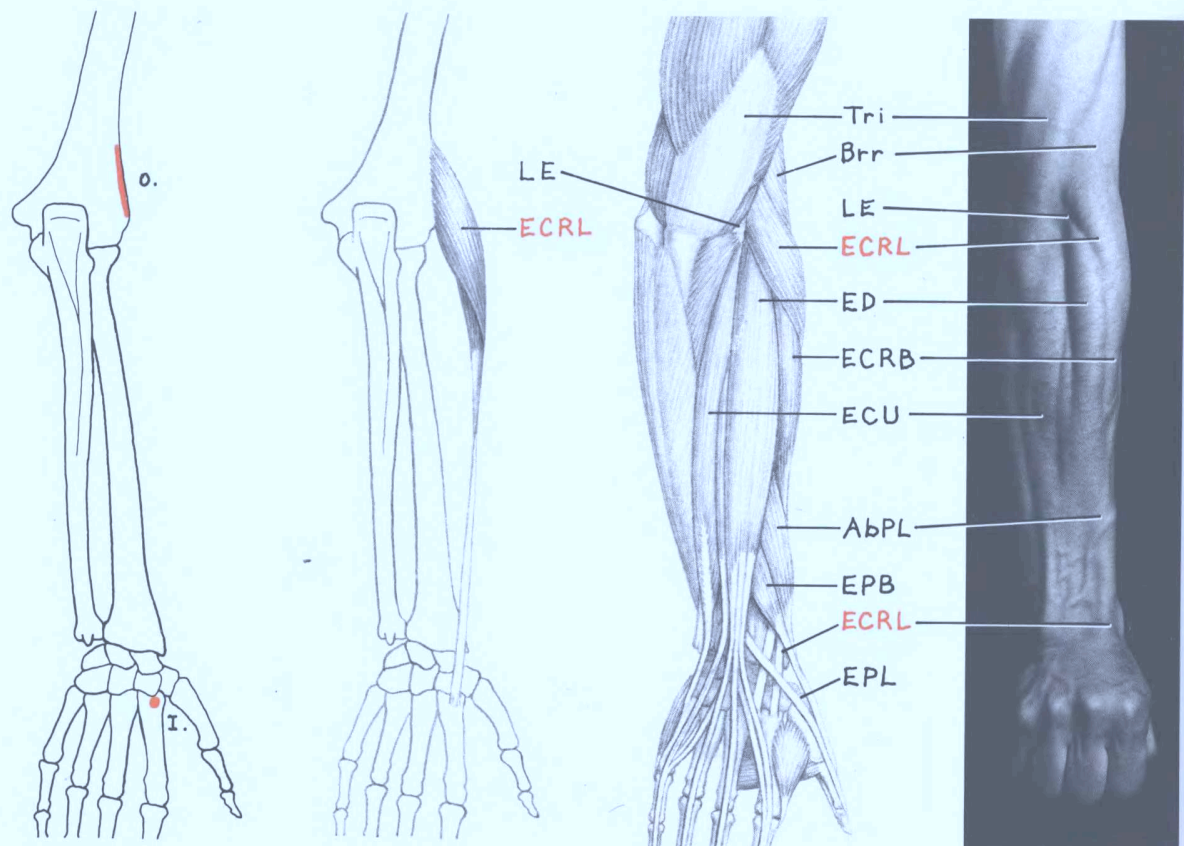
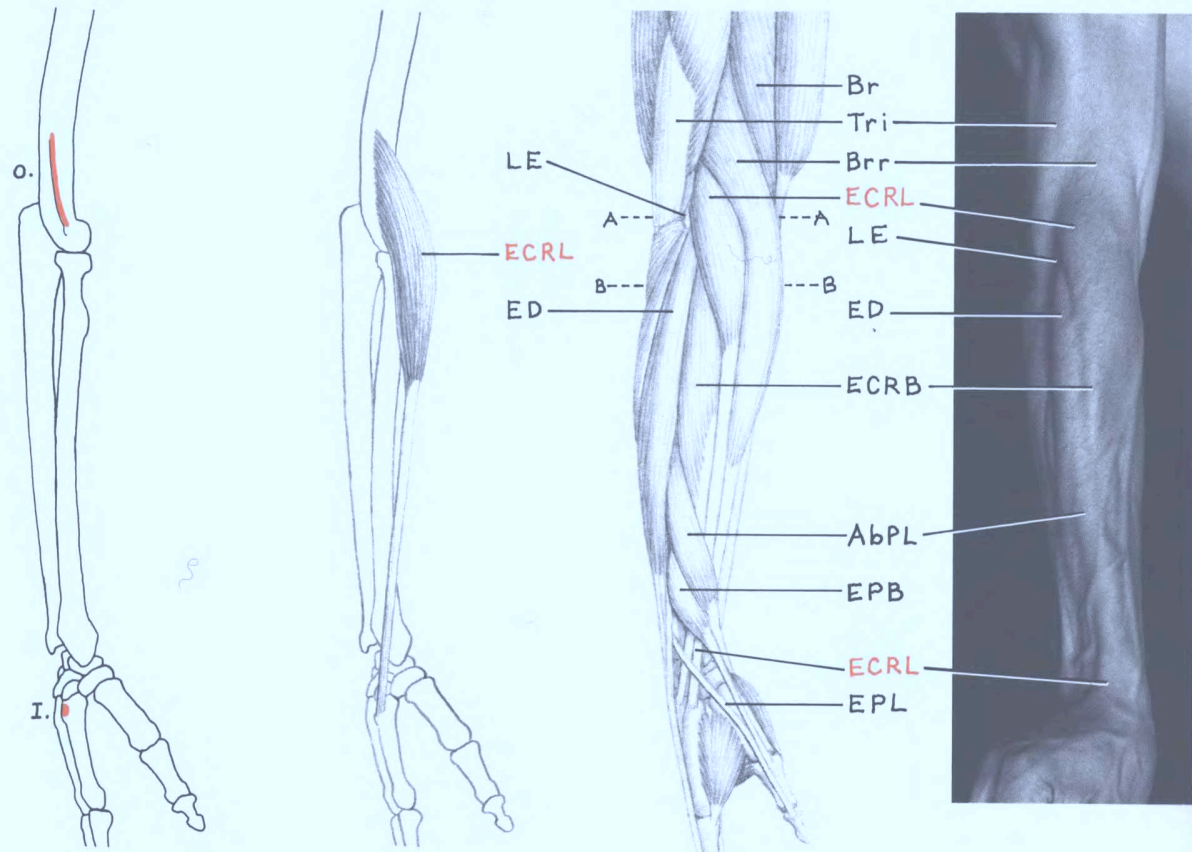
belly appears to “float” longitudinally in this region of the forearm, reaching neither the elbow nor the wrist, as the other epicondyle extensors do. The axis of the belly runs parallel to the long axis of the forearm. The belly is more prominent during supination (with the wrist extended) than during pronation.

The tendon of the extensor carpi radialis brevis, beginning on the radial side of its belly, travels down the forearm next to the tendon of the extensor carpi radialis longus and passes down the middle of the back surface of the lower end of the radius in its own bony groove. Together, the tendons of extensors carpi radialis longus and brevis, barely visible as a single linear ridge on the lower half of the forearm when the wrist is extended, pass under the abductor pollicis longus and extensor pollicis brevis. At the point where they cross the wrist joint at the end of the radius, they create a small, separate, transitional plane between the back of the wrist and the back of the hand when the wrist is extended.

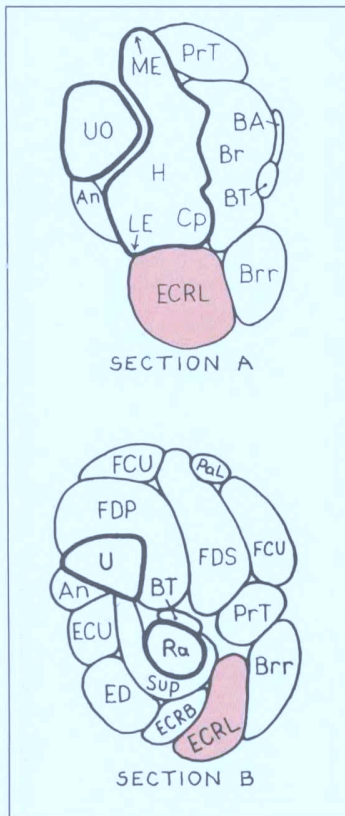
The oblique belly of the extensor carpi radialis longus covers the superior tendon of the extensor carpi radialis brevis.



The Forearm Muscles • EXTENSOR CARPI RADIALIS LONGUS



AbPL Abductor pollicis longus Br Brachialis Brr Brachioradialis Cp Capitulum
 ECRB Extensor carpi radialis brevis ECRL Extensor carpi radialis longus ECU Extensor carpi ulnaris
 ED Extensor digitorum EPB Extensor pollicis brevis EPL Extensor pollicis longus H Humerus
 LE Lateral epicondyle Ra Radius Sup Supinator Tri Triceps U Ulna UO Ulna—olecranon



Extensor Carpi Radialis Longus

ORIGIN Lower third of the lateral supracondylar ridge of the humerus, the front of the adjacent lateral intermuscular septum, and minimally from the common extensor tendon originating from the lateral epicondyle of the humerus.

INSERTION Dorsal surface of the metacarpal bone of the index finger, on its radial side.

ACTION Extends and radially deviates the hand at the wrist joint; assists in flexing the elbow joint.

STRUCTURE The extensor carpi radialis longus consists of a *short*, flat, fleshy belly that ends at the upper third of the forearm and a *long*, narrow, flat tendon that continues down the outer edge of the radius, alongside the tendon of the extensor carpi radialis brevis. The tendon then passes down the back surface of the end of the radius in its own bony groove. On the lower half of the forearm, the tendons of these two radial wrist extensors, passing under the abductor pollicis longus and extensor pollicis brevis, may appear as a thin raised ridge when the wrist is extended. After these tendons leave the distal end of the radius, they create a small transitional plane between the back of the wrist and the back of the hand when the wrist is extended.

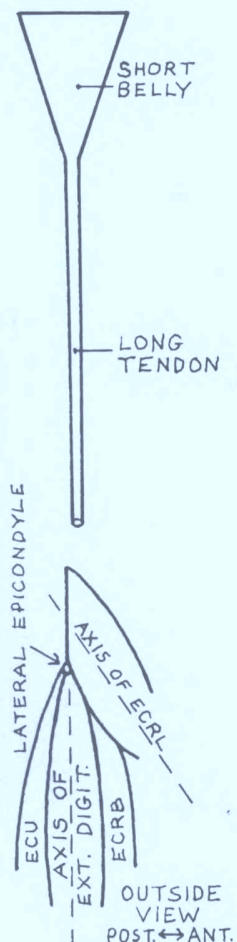
At their superior ends, the extensor carpi radialis longus and brachioradialis begin side by side at their origin, but as they descend, the belly of the extensor carpi radialis longus is soon partially covered by the belly of the brachioradialis. These two muscle bellies typically blend together into a single form when the elbow is extended (there may be a slight separation if the wrist is also extended). When the elbow joint is flexed to 90° with the wrist ex-

tended, the belly of the extensor carpi radialis longus is at its shortest and becomes a relatively prominent, short, triangular relief when tensed, quite separate from the brachioradialis. A depression forms where the belly of the extensor carpi radialis longus attaches to its tendon, near the upper end of the forearm. This belly is considerably shorter than the belly of the brachioradialis.

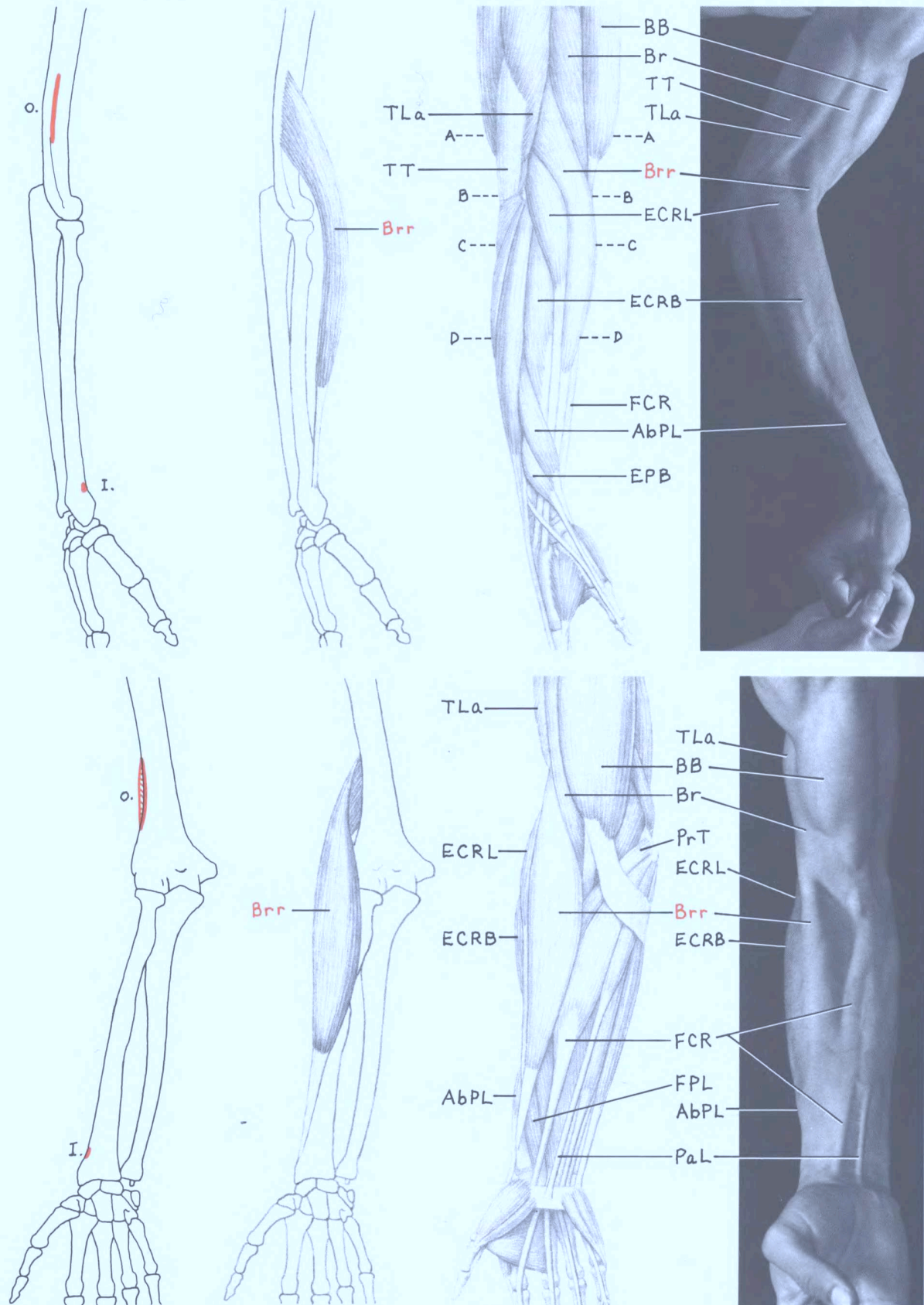
On the outside of the elbow, the lower (posterior) edge of the extensor carpi radialis longus lies oblique to the direction of the forearm extensors, which are directed more or less straight from their origin on the lateral epicondyle of the humerus toward the back of the hand (compare the axis of the extensor digitorum with the lower border of the extensor carpi radialis longus when the elbow is extended).

The belly of the extensor carpi radialis longus noticeably bulges more, and is separate from, the epicondyle extensors. In other words, the two *ridge muscles* (brachioradialis and extensor carpi radialis longus—originating from the lateral supracondylar ridge of the humerus) and the three *epicondyle muscles* (extensor carpi radialis brevis, extensor digitorum, and extensor carpi ulnaris—originating from the lateral epicondyle of the humerus) are very different and separate at the elbow. The ridge muscles as a group are oblique (from side to front) to the axis of the forearm, whereas the epicondyle muscles are straight in line with the axis of the forearm, and their upper ends lie recessed from the ridge muscles. Lower down on the forearm, however, all five muscles blend to create the cylindrical (ovoid) form of the forearm.

Occasionally, the ridge muscles will blend with the extensor digitorum, separating from the recessed proximal end of the extensor carpi ulnaris.



The Forearm Muscles • BRACHIORADIALIS



AbPL Abductor pollicis longus BB Biceps brachii Br Brachialis Brr Brachioradialis
 ECRB Extensor carpi radialis brevis ECRL Extensor carpi radialis longus EPB Extensor pollicis brevis
 FCR Flexor carpi radialis FPL Flexor pollicis longus H Humerus PaL Palmaris longus
 PrT Pronator teres Ra Radius TLa Triceps—lateral head TMe Triceps—medial head
 TT Triceps tendon U Ulna

Brachioradialis (Supinator Longus)

ORIGIN Upper two-thirds of the lateral supracondylar ridge of the humerus and the front of the adjacent lateral intermuscular septum.

INSERTION Lateral (thumb) side of the lower end of the radius, just proximal to the styloid process.

ACTION Flexes the forearm at the elbow joint. It does not pronate or supinate the forearm.

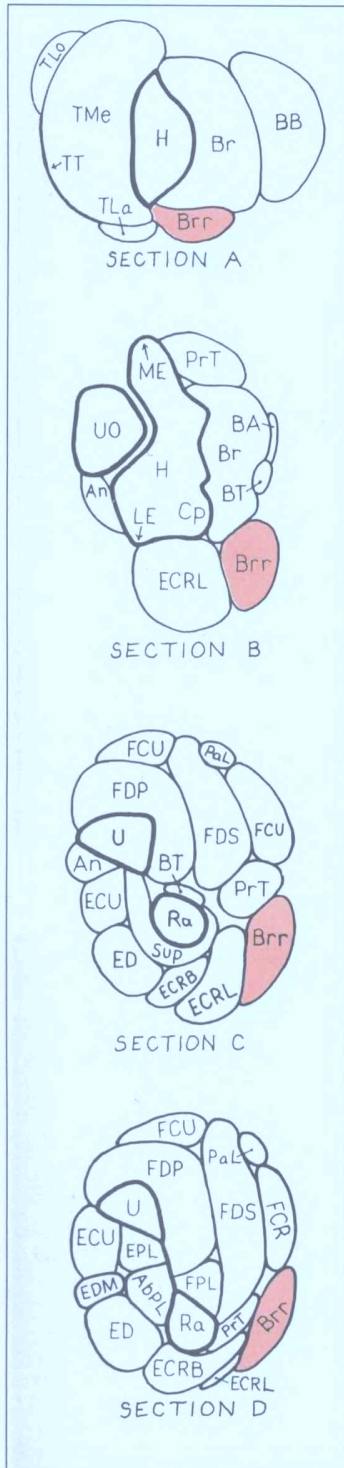
STRUCTURE Originating two-thirds of the way down the humerus between the triceps and brachialis, the belly of the brachioradialis begins wide and flat at its origin, twists toward the front of the arm as it descends (becoming rounder in cross section at the elbow), and widens and flattens again before ending in a flat tendon approximately one-half to two-thirds of the way down the forearm. The superior end of the brachioradialis begins near (approximately two inches from) the insertion of the deltoid. On the forearm, the belly creates a transition between the flexor and extensor muscle groups, partially overlapping the extensor carpi radialis longus on one side and the pronator teres and flexor carpi radialis on the other. The tendon of the brachioradialis lies on the radius and usually is not seen. Unlike most of the long tendons of the forearm, the tendon of the brachioradialis does not cross the wrist joint, but rather stops at the distal end of the radius.

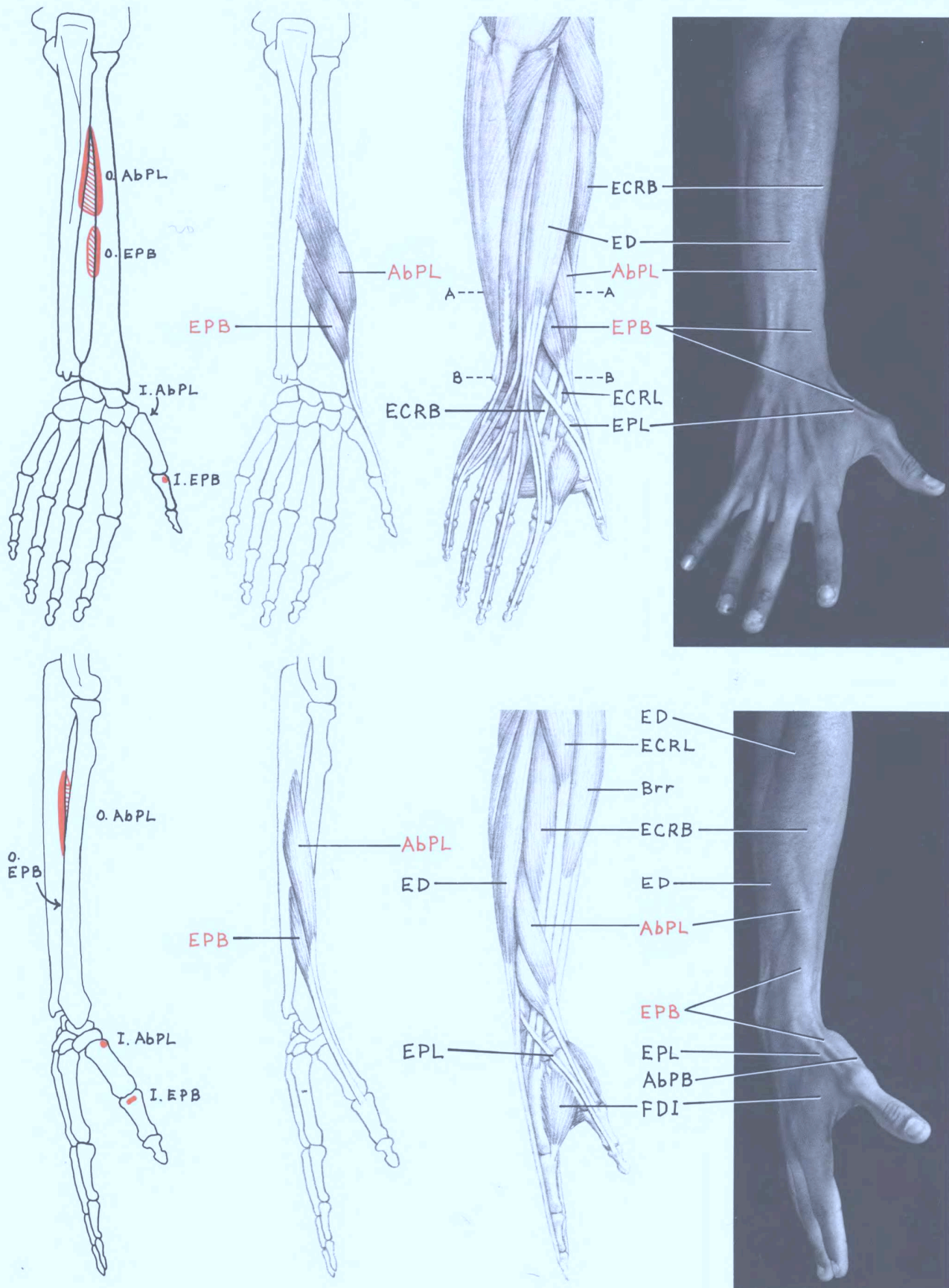
The brachioradialis begins side by side with the extensor carpi radialis longus on the supracondylar ridge, but the former soon partially

overlaps the medial edge of the latter as they both descend. Because they both originate from the supracondylar ridge above the lateral epicondyle of the humerus, the muscular form on the outside of the elbow extends higher than the muscular form of the flexor muscles on the inside, which originates lower down on the medial epicondyle. This is especially noticeable when the elbow is flexed.

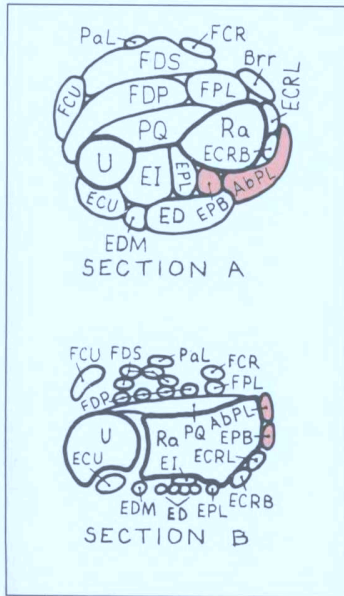
When the brachioradialis is relaxed and the elbow is in any position of flexion, the brachioradialis bends across the middle of its belly at the front of the elbow. The upper fibers inconspicuously contribute to the laterally compressed cylindrical form of the upper arm, while its lower fibers participate in producing the ovoid form of the forearm. If the muscle is then tensed (the forearm flexed against resistance), its belly pops up, creating a thickened raised ridge which passes from the outside of the lower end of the upper arm to the middle of the radial side of the forearm. The form of this ridge, however, remains slightly constricted in front of the elbow, where the bend appears in the relaxed condition. During elbow flexion, two or more skin folds cross the front of the elbow region, passing over the brachioradialis. The distal skin fold coincides with the bend in the belly.

When the elbow is straightened, the brachioradialis and extensor carpi radialis longus—the “ridge muscles”—typically blend together to create a single bulging form on the outside of the elbow.





AbPB Abductor pollicis brevis AbPL Abductor pollicis longus Brr Brachioradialis
 ECRB Extensor carpi radialis brevis ECRL Extensor carpi radialis longus ED Extensor digitorum
 EPB Extensor pollicis brevis EPL Extensor pollicis longus FDI First dorsal interosseous
 Ra Radius U Ulna



Abductor Pollicis Longus (Extensor Ossis Metacarpi Pollicis)

ORIGIN Areas on the posterior surfaces of the ulna and radius and the intervening interosseous membrane.

INSERTION Base of the metacarpal bone of the thumb, on its back surface toward its radial side (near the palm).

ACTION Abducts and extends the metacarpal of the thumb. It also radially deviates the hand and assists in flexing the hand at the wrist.

Extensor Pollicis Brevis

ORIGIN Area on the posterior surface of the radius and the adjacent interosseous membrane.

INSERTION Back surface of the base of the proximal phalanx of the thumb.

ACTION Extends the proximal phalanx of the thumb, and by continued action extends its metacarpal bone. It also deviates the hand radially.

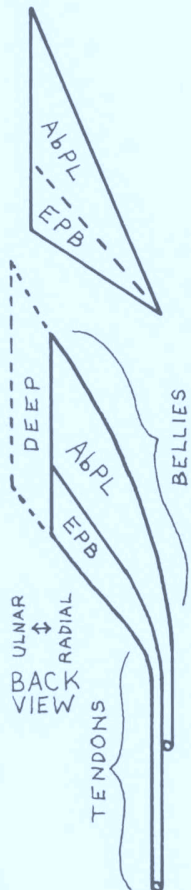
STRUCTURE The **abductor pollicis longus** and **extensor pollicis brevis** combine to create an oblique, narrow, triangular muscular form which wraps around the lower end of the radius. Together they can be considered the “**oblique carpal muscle group**.” Their single triangular form can be seen as a small swelling on the lower portion of the lateral side of the radius. The two muscles separate when they are strongly contracted. The oblique carpal muscles produce a small but important convexity three-fourths of the way down the forearm on its outer (radial) profile.

Arising deep in the back of the forearm, the

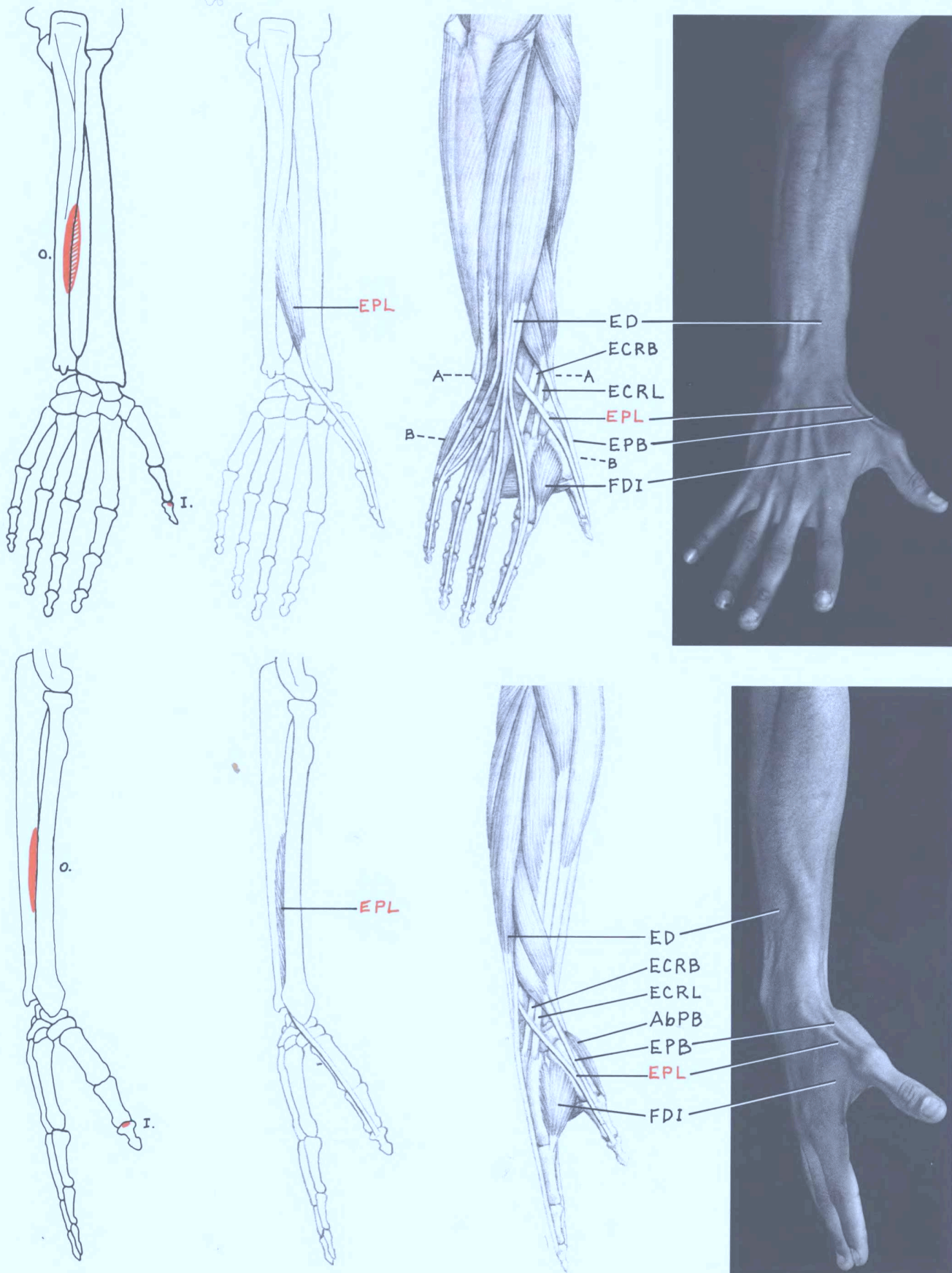
two flattened muscle bellies emerge from under the extensor digitorum and then cross over the tendons of the extensor carpi radialis brevis and longus in their oblique descent down the lower portion of the forearm. They become tendinous on the outer edge of the radius and pass downward together through a shallow bony groove on the lower end of the outside of the radius. The tendons usually *appear* to end at the base of the metacarpal of the thumb, forming the palmar tendon of the anatomical snuffbox at the wrist (see Extensor Pollicis Longus). As they cross the wrist joint, the tendon of the extensor pollicis brevis lies dorsal to, and usually adjacent to, the tendon of the abductor pollicis longus.

The **tendon of the abductor pollicis longus** inserts into the base of the metacarpal of the thumb, frequently sending tendinous slips to the trapezium bone of the carpus and the *surface* of the abductor pollicis brevis muscle at its origin. This tendon is thick and strong and actually consists of up to seven or eight combined tendons. Several of these are often seen on the surface, especially when the thumb is moved forward and back at the carpometacarpal joint.

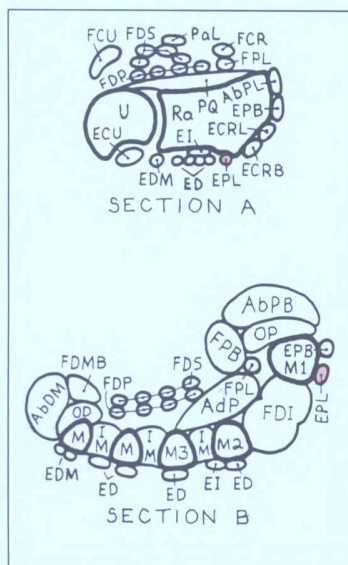
The very slender **tendon of the extensor pollicis brevis** passes down the back of the metacarpal of the thumb. It may be inconspicuous or quite distinct, first passing down the middle of the snuffbox and then down the back surface of the metacarpal of the thumb. When the extended thumb is advanced forward away from the palm (along a plane perpendicular to the plane of the palm), the tendons of extensor pollicis brevis and longus converge distally at the metacarpophalangeal joint of the thumb.



The Forearm Muscles • EXTENSOR POLLICIS LONGUS



AbPB Abductor pollicis brevis AbPL Abductor pollicis longus ECRB Extensor carpi radialis brevis
 ECRL Extensor carpi radialis longus ED Extensor digitorum EPB Extensor pollicis brevis
 EPL Extensor pollicis longus FDI First dorsal interosseous M Metacarpal Ra Radius U Ulna



Extensor Pollicis Longus

ORIGIN Middle third of the lateral portion of the posterior surface of the ulna and the adjacent area on the interosseous membrane.

INSERTION Back surface of the base of the distal phalanx of the thumb.

ACTION Extends the distal phalanx of the thumb, and by continued action, extends its proximal phalanx and metacarpal bone. It also adducts the thumb at the carpometacarpal joint, even when the thumb is flexing at the metacarpophalangeal and interphalangeal joints. It assists in extending the hand at the wrists.

STRUCTURE Beginning deep in the forearm, only the tendon of the extensor pollicis longus becomes visible after it leaves its oblique bony groove on the middle of the back of the distal end of the radius. At this point, it turns sharply toward the thumb, crosses over the tendons of the extensor carpi radialis brevis and longus, and descends along the back of the thumb—not directly on the midline, but slightly toward its ulnar (index finger) side. The tendon can usually be seen as far down as the interphalangeal joint. This tendon is very prominent when the thumb is extended and disappears when the thumb is flexed at the carpometacarpal joint. If the thumb is extended and then adducted toward the index finger, the visible tendon of the extensor pollicis longus bends (changes direction) at the metacarpophalangeal joint of the thumb.

Tendons to the Thumb

The thumb has three bones: a metacarpal, proximal phalanx, and distal phalanx. The base of each bone receives a tendon from a muscle. In other words, there are three bones and three tendons, one tendon per bone. The base of the metacarpal receives the tendon of the abductor pollicis longus (often a complex multiple ten-

don), the base of the proximal phalanx receives the tendon of the extensor pollicis brevis, and the base of the distal phalanx receives the tendon of the extensor pollicis longus. The tendons of the abductor pollicis longus and extensor pollicis brevis usually combine together visually, especially at the anatomical snuffbox (see below).

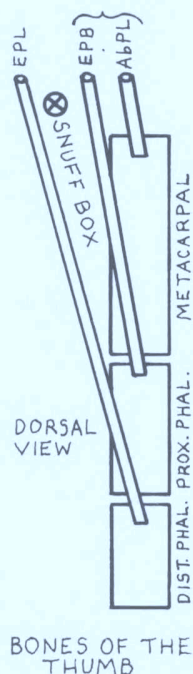
The three tendons to the thumb are part of the extrinsic muscle group of the hand. These muscles originate in the forearm and insert into the hand (on the thumb).

The Anatomical Snuffbox

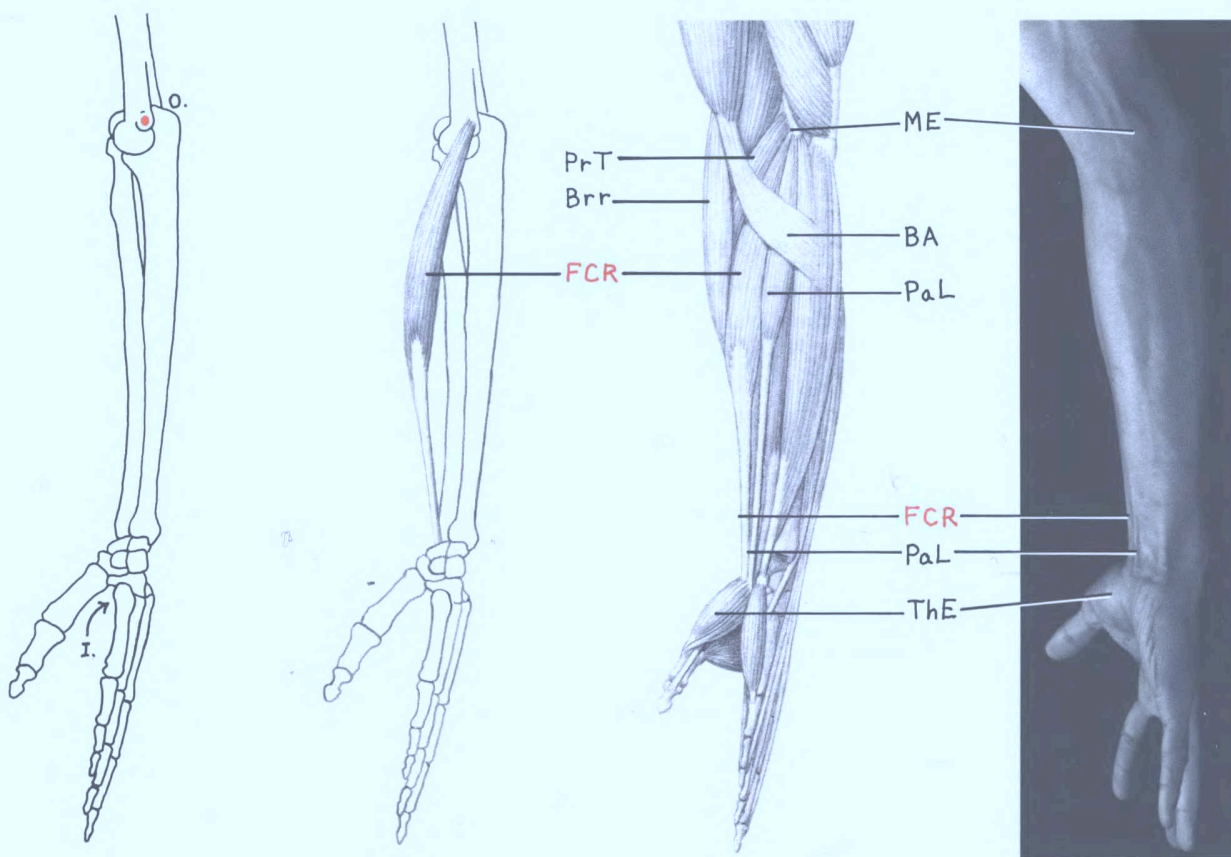
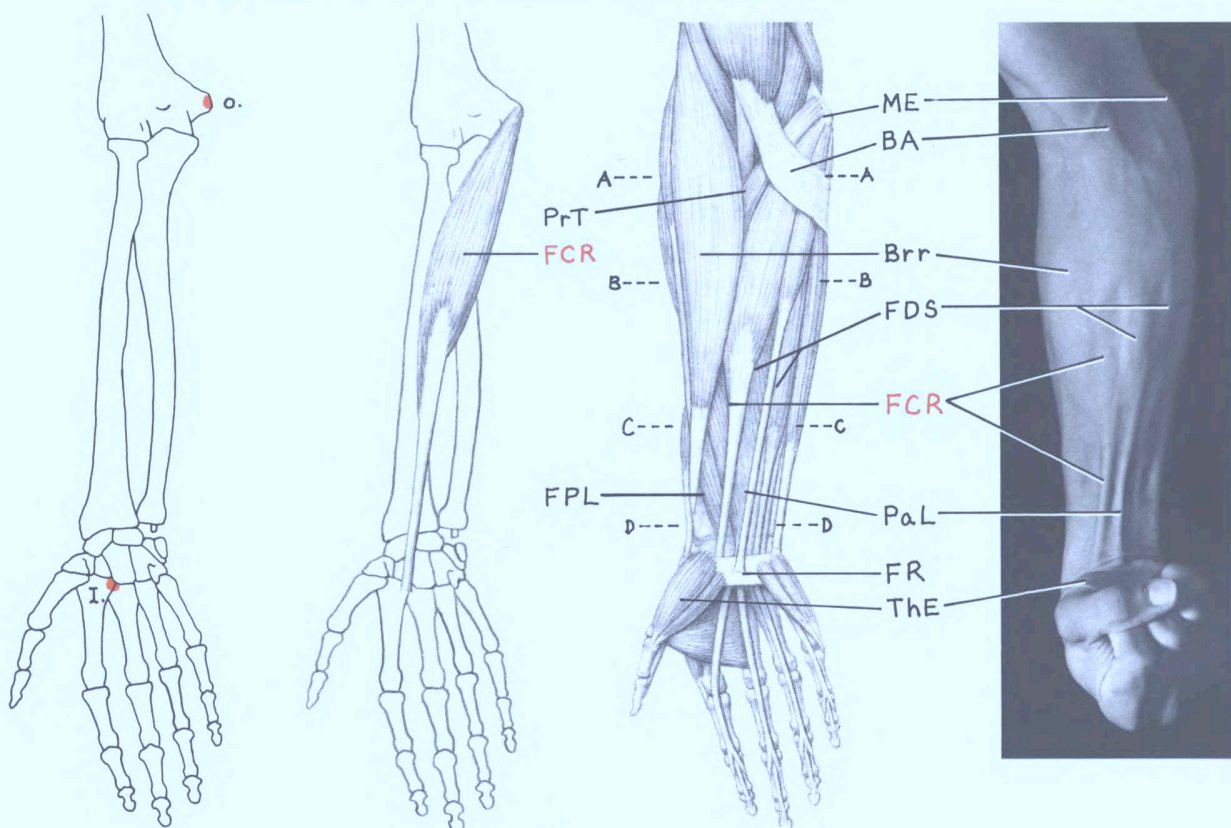
The **anatomical snuffbox** is the square, hollow depression located on the radial side of the wrist. It is bordered by the tendon of the extensor pollicis longus on the dorsal (posterior) corner of the wrist, the combined tendons of the extensor pollicis brevis and abductor pollicis longus on the palmar (ventral or anterior) corner of the wrist, the distal end of the radius proximally, and the base of the metacarpal of the thumb distally. The lateral carpal bones lie at the floor of the snuffbox.

The snuffbox appears when the thumb is extended with the tendons prominent. If the thumb is then abducted away from the palm (along a plane perpendicular to the plane of the palm), the tendons bordering the snuffbox converge distally.

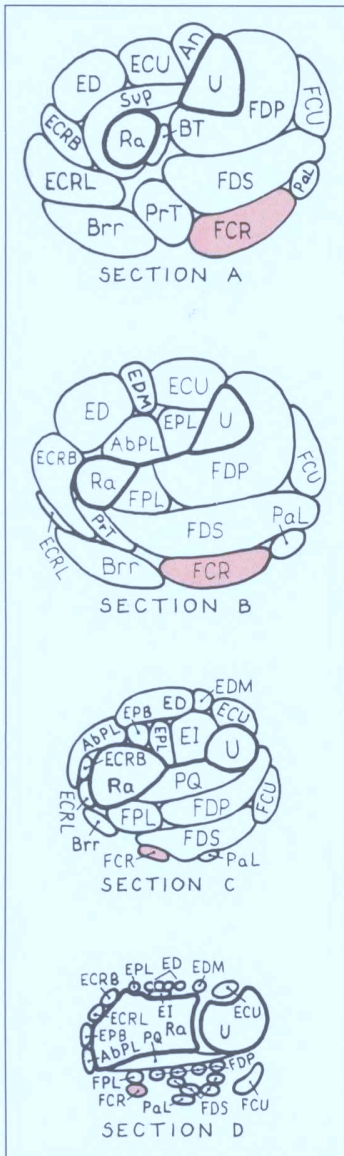
The tendon of the extensor pollicis brevis may either combine visually with the tendon of the abductor pollicis longus, lie inconspicuously on the outside of the wrist, or become visible between the tendons of the extensor pollicis longus and abductor pollicis longus as it passes down the center of the snuffbox and then down the dorsal surface of the metacarpal of the thumb.



The Forearm Muscles • FLEXOR CARPI RADIALIS



BA Bicipital aponeurosis Brr Brachioradialis FCR Flexor carpi radialis
 FDS Flexor digitorum superficialis FPL Flexor pollicis longus FR Flexor retinaculum
 ME Medial epicondyle PaL Palmaris longus PrT Pronator teres Ra Radius ThE Thenar eminence
 U Ulna



Flexor Carpi Radialis

ORIGIN Medial epicondyle of the humerus (by the common flexor tendon).

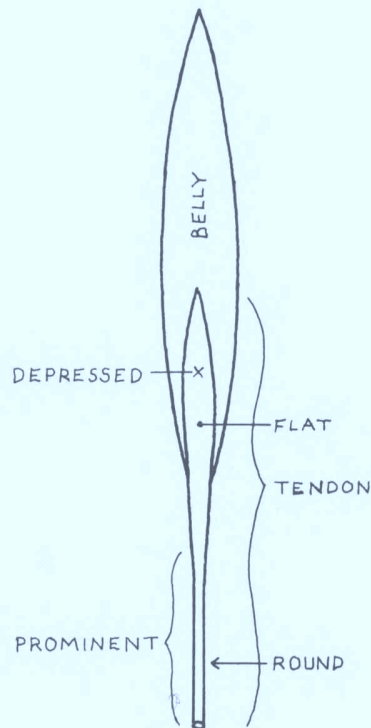
INSERTION Bases of the metacarpal bones of the index and middle fingers, deep in the palm.

ACTION Flexes and radially deviates the hand at the wrist joint.

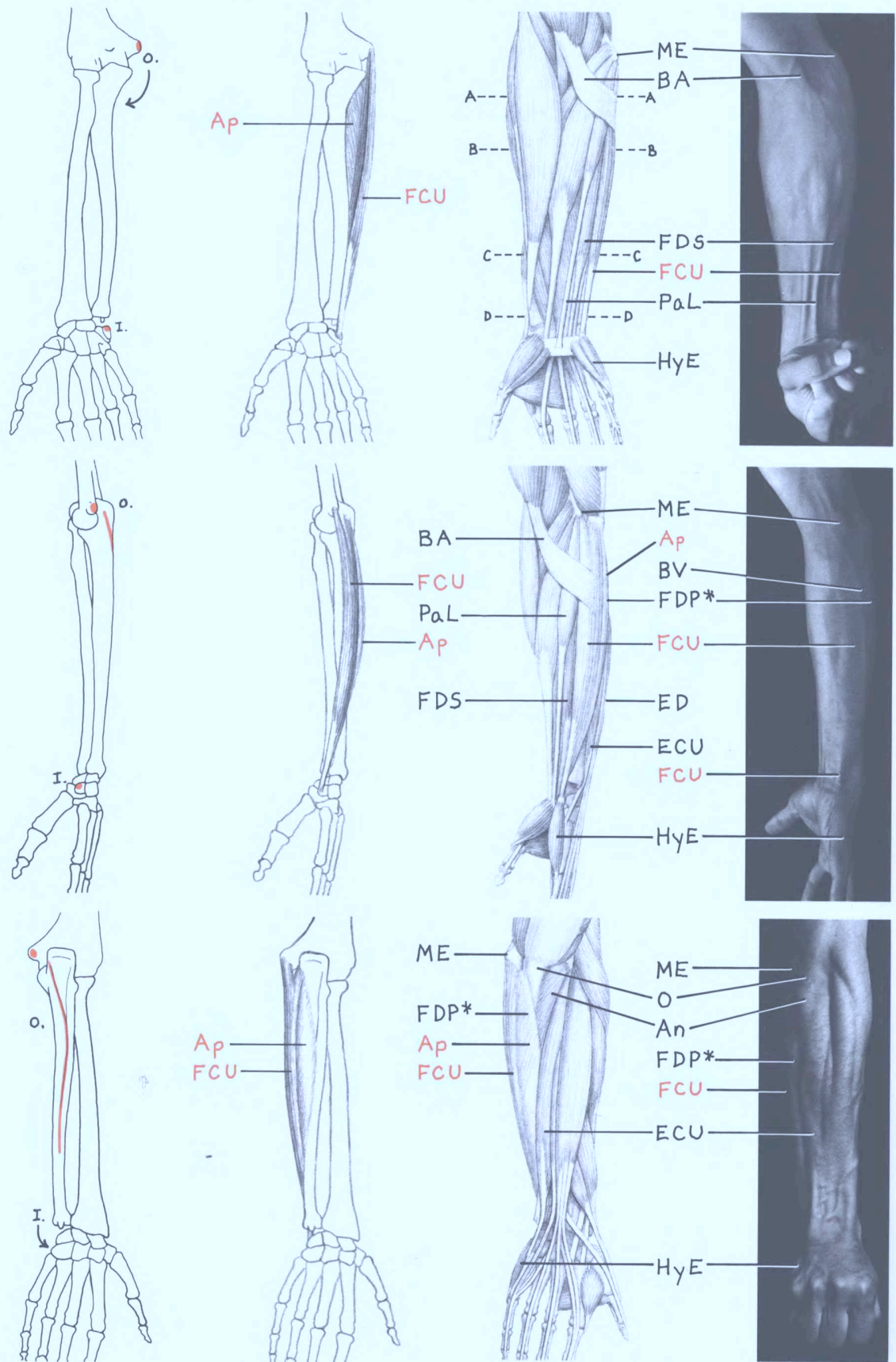
STRUCTURE The fleshy belly of the flexor carpi radialis, located on the *upper half* of the forearm, is slightly flattened distally. Its tendon, beginning *one-third* of the way down the forearm, is flat, wide, and pointed proximally and rounded distally. The muscle fibers of the belly split and pass down each side of the tendon for a short distance. Because of this arrangement, when the muscle is tensed, the wide proximal

end of the tendon usually becomes slightly depressed between the bulging V-shaped distal end of the belly. The muscle fibers on the radial side of the tendon then blend visually with the form of the brachioradialis.

Just proximal to the wrist, the cordlike tendon of the flexor carpi radialis is very prominent, especially when the wrist is flexed and radially deviated. It lies just off the midline, toward the radial side of the forearm. This tendon is thicker than the tendon of the palmaris longus, is directed toward the index finger (when the hand is straight), and passes out of view at the base of the hand. In the anatomical position (supinated forearm), the entire flexor carpi radialis lies oblique on the forearm, as it passed from its origin to its insertion.



The Forearm Muscles • FLEXOR CARPI ULNARIS



An Anconeus Ap Aponeurosis BA Bicipital aponeurosis BV Basilic vein ECU Extensor carpi ulnaris
 ED Extensor digitorum FCU Flexor carpi ulnaris FDP Flexor digitorum profundus
 FDS Flexor digitorum superficialis HyE Hypothenar eminence ME Medial epicondyle O Olecranon
 PaL Palmaris longus Ra Radius U Ulna * Under flexor carpi ulnaris

Flexor Carpi Ulnaris

ORIGIN *Humeral head:* Medial epicondyle of the humerus (by the common flexor tendon).

Ulnar head: Medial border of the olecranon, continuing down the upper two-thirds of the posterior border of the ulna.

INSERTION Pisiform bone of the wrist.

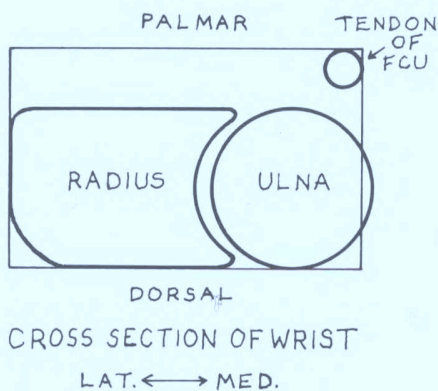
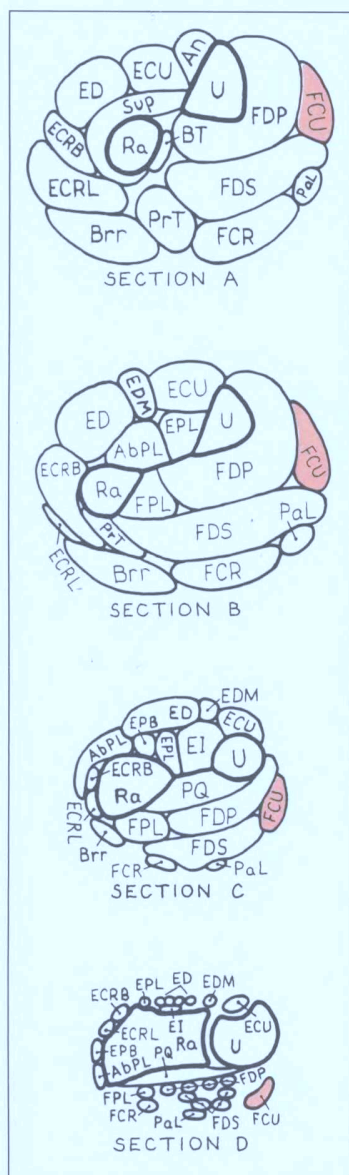
ACTION Flexion and ulnar deviation of the hand at the wrist joint.

STRUCTURE The humeral and ulnar heads of the flexor carpi ulnaris combine to form a single *flat* belly which is extremely difficult to isolate on the surface. Basically, this muscle adds bulk to the general form of the flexor muscle mass on the forearm. The belly of the flexor carpi ulnaris tapers distally as its muscle fibers insert along the ulnar edge of its tendon, almost all the way down to the insertion. The tendon is relatively prominent on the distal quarter of the forearm, but less so than the tendons of the palmaris longus and flexor carpi radialis. At the distal fifth of the forearm, when the wrist joint is straight or flexed, the tendon of the flexor carpi ulnaris does not lie in contact with the ulna, and the interval between them is filled

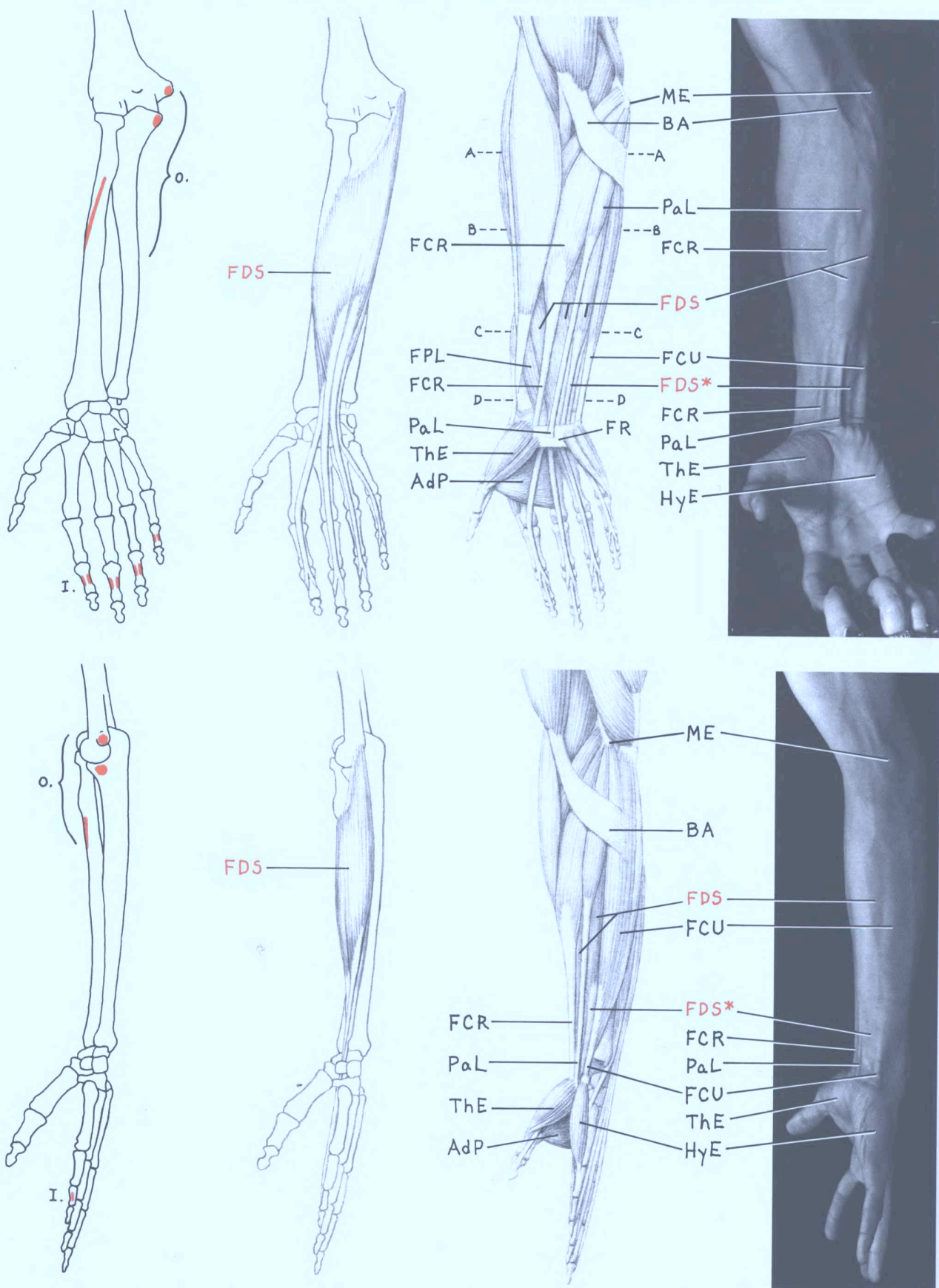
with fat. When the wrist is extended, the tendon approaches the bone, and the fat is squeezed out. The tendon directly creates the inner front corner of the box of the wrist (in the anatomical position).

The ulnar edge of the proximal two-thirds of the belly of the flexor carpi ulnaris thins into an aponeurosis which in turn passes *over the surface* of the flexor digitorum profundus, to ultimately attach along the posterior border of the ulna. In other words, the flexor digitorum profundus is located in the interval between the *belly* of the flexor carpi radialis and the posterior border of the ulna, covered only by the thin aponeurosis of the flexor carpi ulnaris (which has no form of its own). The ulnar edge of the belly of the flexor carpi ulnaris may on rare occasion show up as a furrow. The basilic vein is at times located in the middle third of this furrow.

When the little finger is abducted, the abductor digiti minimi pulls on the pisiform bone. During this action, the flexor carpi ulnaris simultaneously contracts to stabilize the pisiform, and its tendon then becomes more prominent.



The Forearm Muscles • FLEXOR DIGITORUM SUPERFICIALIS



AdP Adductor pollicis BA Bicipital aponeurosis FCR Flexor carpi radialis FCU Flexor carpi ulnaris
 FDP Flexor digitorum profundus FDS Flexor digitorum superficialis FPL Flexor pollicis longus
 FR Flexor retinaculum HyE Hypothenar eminence ME Medial epicondyle PaL Palmaris longus
 PrT Pronator teres Ra Radius ThE Thenar eminence U Ulna * To ring finger

The Forearm Muscles • FLEXOR DIGITORUM SUPERFICIALIS

Flexor Digitorum Superficialis (Flexor Digitorum Sublimis)

ORIGIN Originates from all three arm bones—humerus, ulna, and radius—as follows: the medial epicondyle of the **humerus** (by the common flexor tendon); the medial side of the coronoid process of the **ulna** and the ulnar collateral ligament of the elbow joint (the ligament connects the coronoid process of the ulna to the medial epicondyle of the humerus); and an oblique line on the anterior surface of the **radius**, beginning at the radial (bicipital) tuberosity and ending halfway down the bone.

INSERTION The edges of the palmar surfaces of the middle phalanges of the index, middle, ring, and little fingers (fingers two through five). It has no attachment to the thumb.

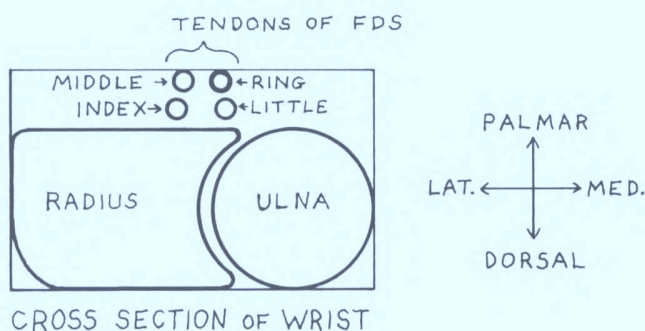
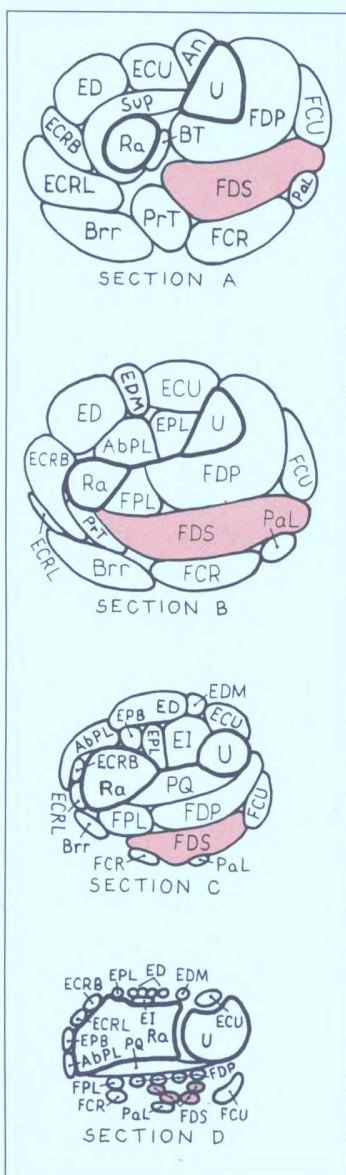
ACTION Flexes the middle phalanges of fingers two through five, and by continued action, flexes their proximal phalanges and then the wrist joint. It does not flex the distal phalanges.

STRUCTURE The flexor digitorum superficialis is a wide, fairly large muscle layer in the forearm, mostly deep but partly superficial. The superficial part comes to the surface at several places, but can only occasionally be seen directly, when the fist is clenched, in the long narrow intervals between the flexor carpi radialis, palmaris longus, and flexor carpi ulnaris.

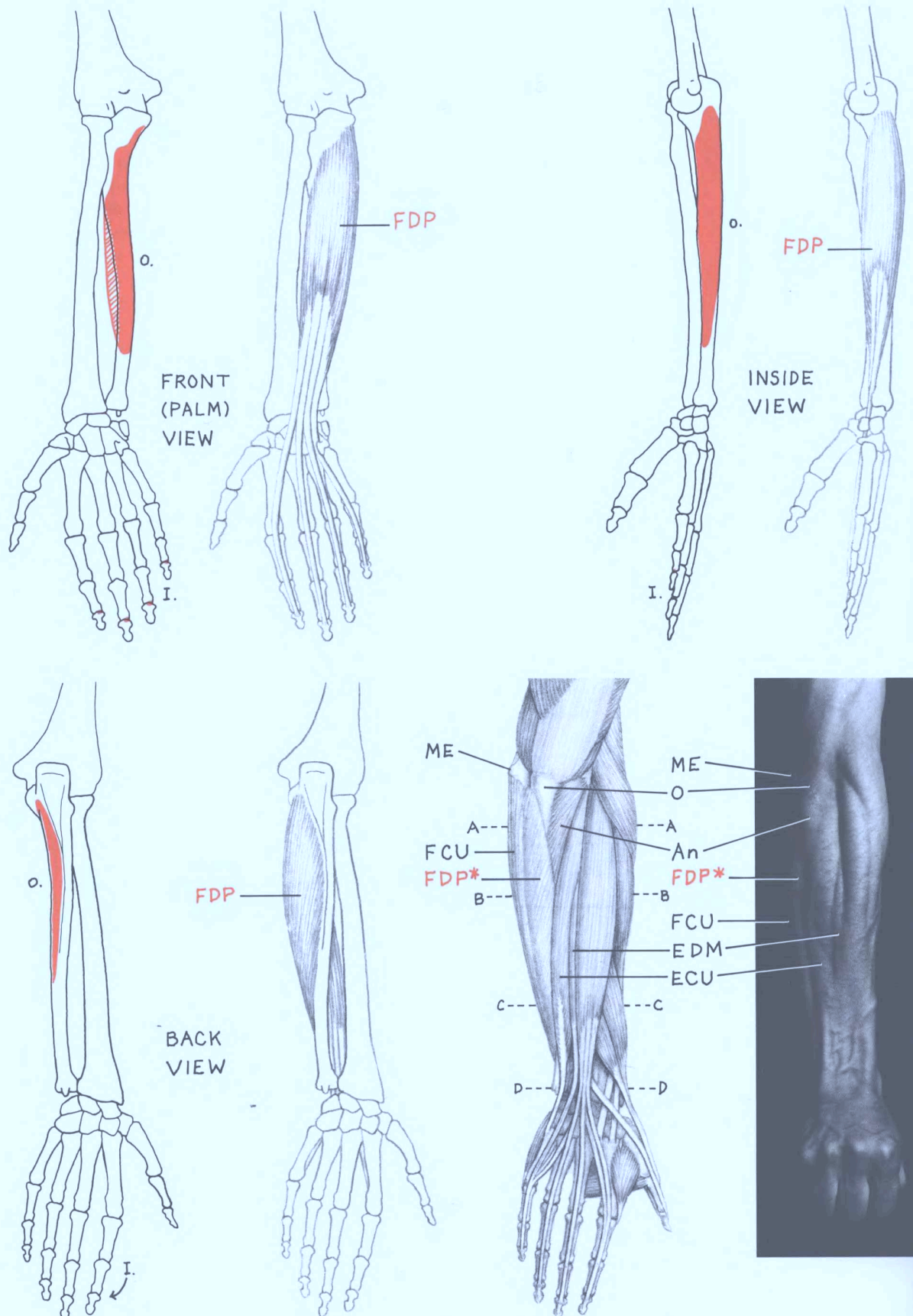
On the distal quarter of the forearm, the subcutaneous tendon of the flexor digitorum superficialis to the ring finger is usually easily seen, lying between the tendons of the palmaris longus and flexor carpi ulnaris. It is most readily seen when the hand is clenched into a fist and the wrist is slightly flexed. If the hand is then deviated toward the ulnar side, the tendon of the flexor digitorum superficialis to the middle finger slides laterally (toward the ulna) out from under the tendon of the palmaris longus.

In the palm, the tendons of the flexor digitorum superficialis all lie on the same plane as they pass distally to their respective fingers. When the palmar fat is thin, and the fingers are partly flexed against resistance, these tendons may be seen in relief on the palm, radiating from the wrist toward the fingers.

When the wrist is fixed in the straight position and the fingers are repeatedly flexed and extended, the belly of the flexor digitorum superficialis can be seen sliding up and down the lower portion of the forearm. Because the flexor digitorum profundus is also working during these actions, both these finger flexors influence the shape of the forearm—they thicken the upper mass of the forearm during finger flexion (they get shorter and thicker when they contract).



The Forearm Muscles • FLEXOR DIGITORUM PROFUNDUS



An Anconeus BT Biceps tendon ECU Extensor carpi ulnaris EDM Extensor digiti minimi
 FCU Flexor carpi ulnaris FDP Flexor digitorum profundus FDS Flexor digitorum superficialis
 FPL Flexor pollicis longus ME Medial epicondyle O Olecranon PaL Palmaris longus
 PQ pronator quadratus Ra Radius U Ulna * Under flexor carpi ulnaris

Flexor Digitorum Profundus

ORIGIN Extensive, continuous area on the ulna—from the middle third of its posterior border, the upper three-fourths of its medial surface (exclusive of its uppermost one inch), and the middle third of its anterior surface. It also originates from the adjacent ulnar half of the interosseous membrane. (It does not originate from the radius or the humerus.)

INSERTION Palmar aspect of the base of the distal phalanges of the index, middle, ring, and little fingers (fingers two through five). It has no attachment to the thumb.

ACTION Powerfully flexes the distal phalanges of fingers two through five, and by continued action, flexes the other finger joints, as well as the wrist.

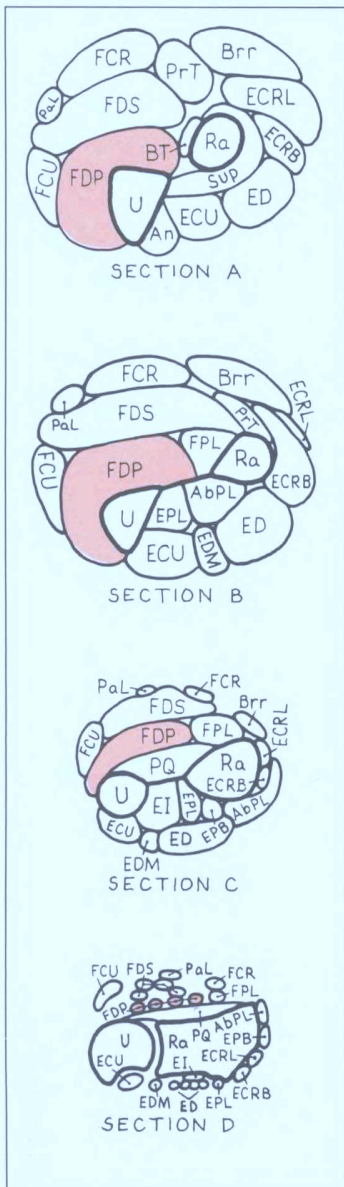
STRUCTURE Situated for the most part deep in the forearm, the flexor digitorum profundus is the largest of the forearm muscles and adds substantially to the volume of the flexor muscle mass. At the wrist, its four tendons lie deep to the other tendons of the forearm. A portion of its belly lies just under the thin aponeurotic expansion of the flexor carpi ulnaris, and actually produces surface form along the flexor side of the posterior border of the ulna.

This superficial strip of flexor digitorum pro-

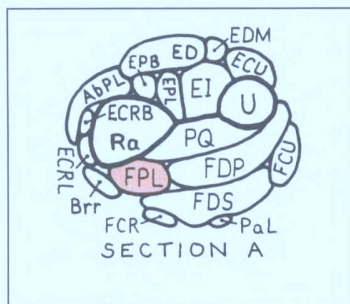
fundus belly may on occasion be distinctly seen on the surface as a narrow form, tapering inferiorly, on the upper two-thirds of the back of the forearm. It is located between the posterior border of the ulna (and the medial side of the olecranon) and the edge of the *muscle fibers* of the flexor carpi ulnaris. It is most likely to be seen when the forearm is pronated, the wrist extended, and the fingers repeatedly flexed and extended. Whether or not this portion of the flexor digitorum profundus is distinctly seen on the surface, it, not the flexor carpi ulnaris, is responsible for directly creating the form of the flexor mass immediately adjacent to the posterior border of the ulna.

In the middle third of the forearm, the flexor muscles (specifically the flexor digitorum profundus) are separated from the extensor muscles (specifically the extensor carpi ulnaris) by a furrow, at the bottom of which lies the posterior border of the ulna.

When the wrist is fixed in the straight position and the fingers are repeatedly flexed and extended, the bellies of the flexor digitorum profundus and superficialis influence the shape of the forearm. When they contract to flex the fingers, they enlarge the medial side of the proximal half of the forearm as they shorten and thicken.



The Forearm Muscles • FLEXOR POLLICIS LONGUS



Flexor Pollicis Longus

ORIGIN Middle half of the anterior surface of the radius and the adjacent interosseous membrane.

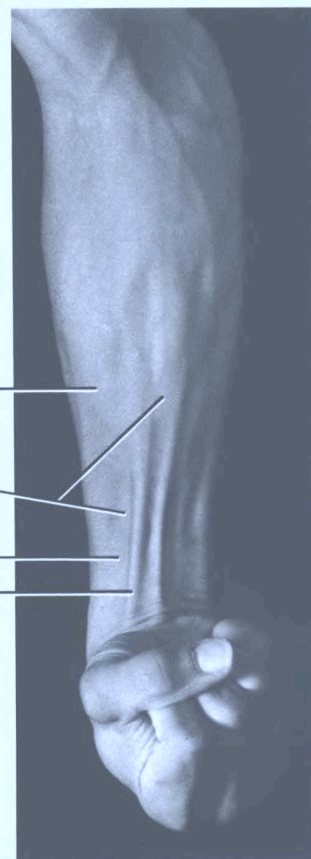
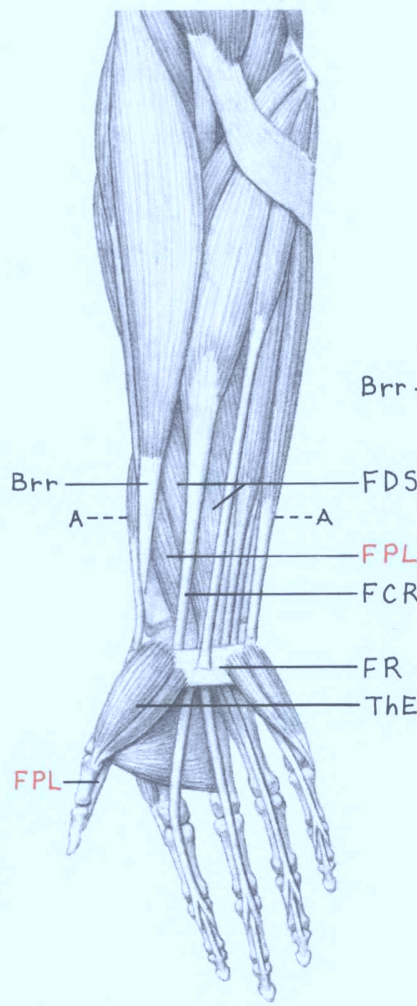
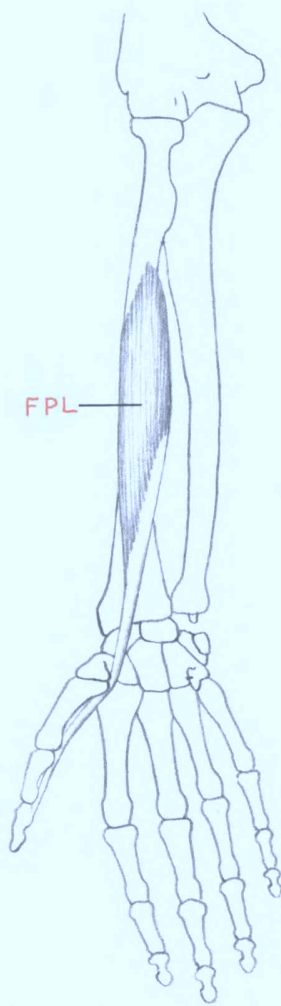
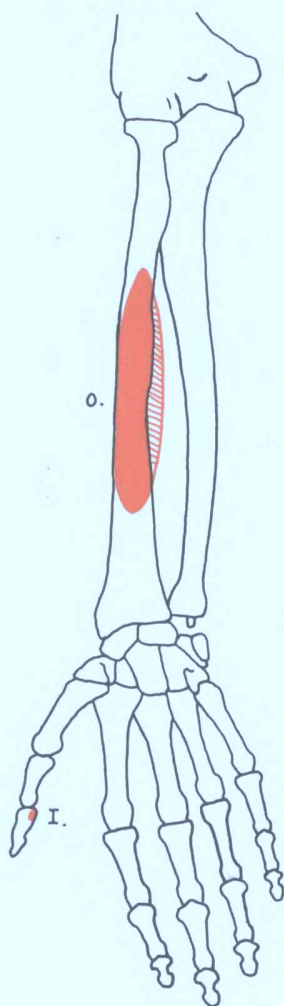
INSERTION Palmar aspect of the base of the distal phalanx of the thumb.

ACTION Flexes the distal phalanx of the thumb.

STRUCTURE The flexor pollicis longus is situated for the most part deep in the forearm, where it adds some fullness on the anterior surface of the radius. It becomes partially superficial on the front of the lower half of the forearm. Never distinct, the belly of the flexor

pollicis longus can be seen moving in this area as the distal phalanx of the thumb is flexed and extended. When the interphalangeal joint of the thumb is flexed, the belly shortens, and a slight depression forms a short distance proximal to the wrist as the distal end of the belly slides upward. Also in this position, it will be noticed that the thickness (dorsal to palmar) of the proximal phalanx of the thumb has increased, caused by the pulling away of the tendon of the flexor pollicis longus from the phalanx.

The flexor pollicis longus therefore very subtly affects surface form in two areas: on the front of the lower end of the forearm and on the proximal phalanx of the thumb.



BA Bicipital aponeurosis Brr Brachioradialis FCR Flexor carpi radialis FCU Flexor carpi ulnaris
FDP Flexor digitorum profundus FDS Flexor digitorum superficialis FPL Flexor pollicis longus
FR Flexor retinaculum HyE Hypothenar eminence ME Medial epicondyle PaL Palmaris longus

The Forearm Muscles • PALMARIS LONGUS

Palmaris Longus

ORIGIN Medial epicondyle of the humerus (by the common flexor tendon).

INSERTION Distal part of the flexor retinaculum of the wrist and the apex of the palmar aponeurosis.

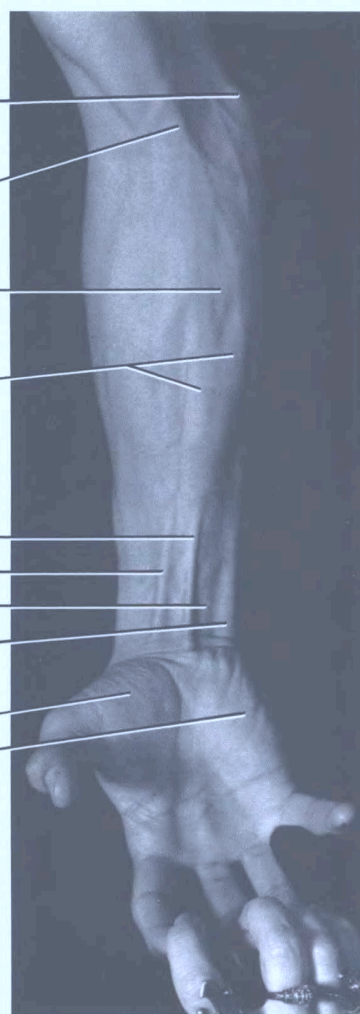
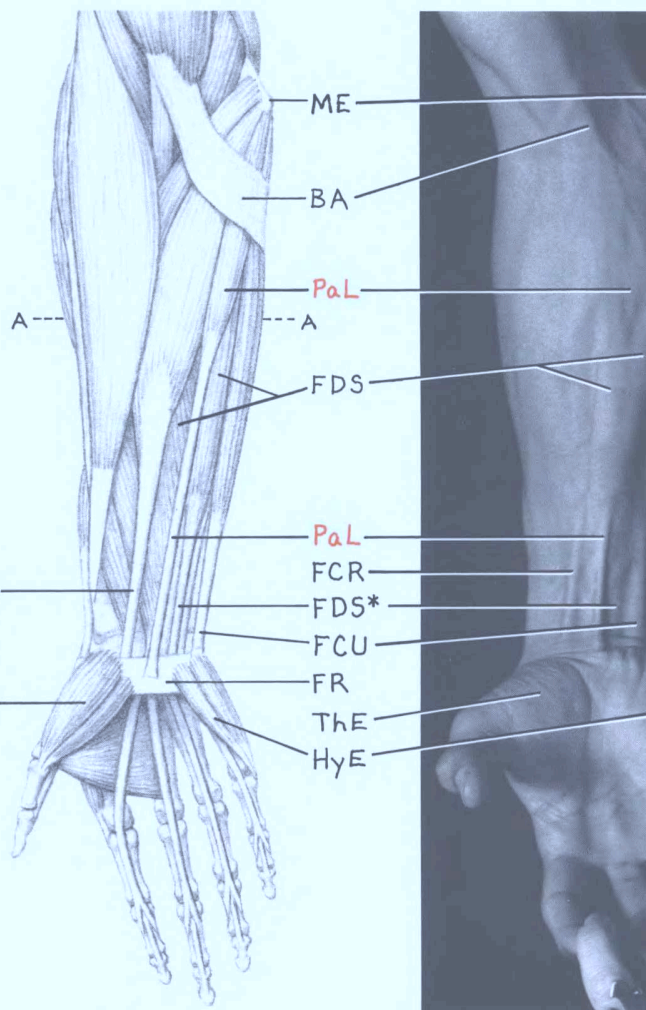
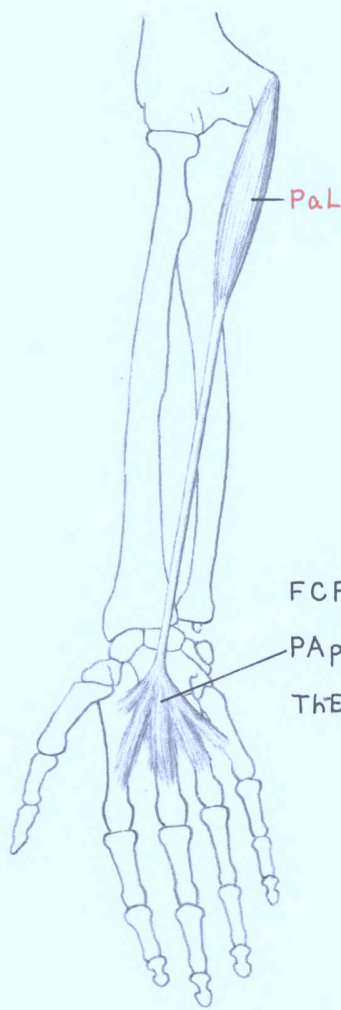
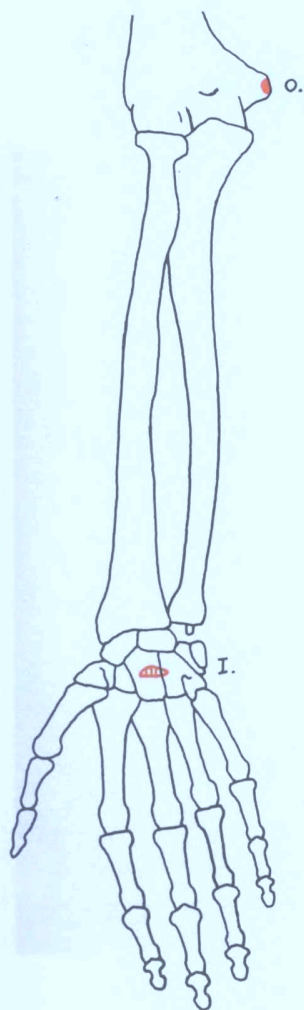
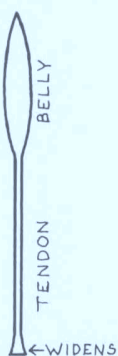
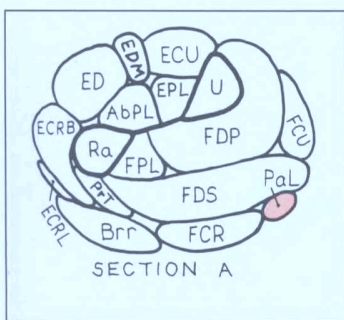
ACTION Flexes the hand at the wrist.

STRUCTURE The palmaris longus consists of a short, narrow, fusiform muscle belly proximally and its very long, slender, slightly flattened tendon. Its belly may be seen only rarely as a *short* elliptical relief descending from the medial epicondyle of the humerus. The tendon can easily be seen passing down the *middle* of

the lower two-thirds of the anterior (flexor) aspect of the forearm. It widens slightly just as it reaches the base of the hand. This tendon is the most conspicuous tendon at the wrist; it becomes especially prominent when the wrist is partially flexed and the hand is clawed.

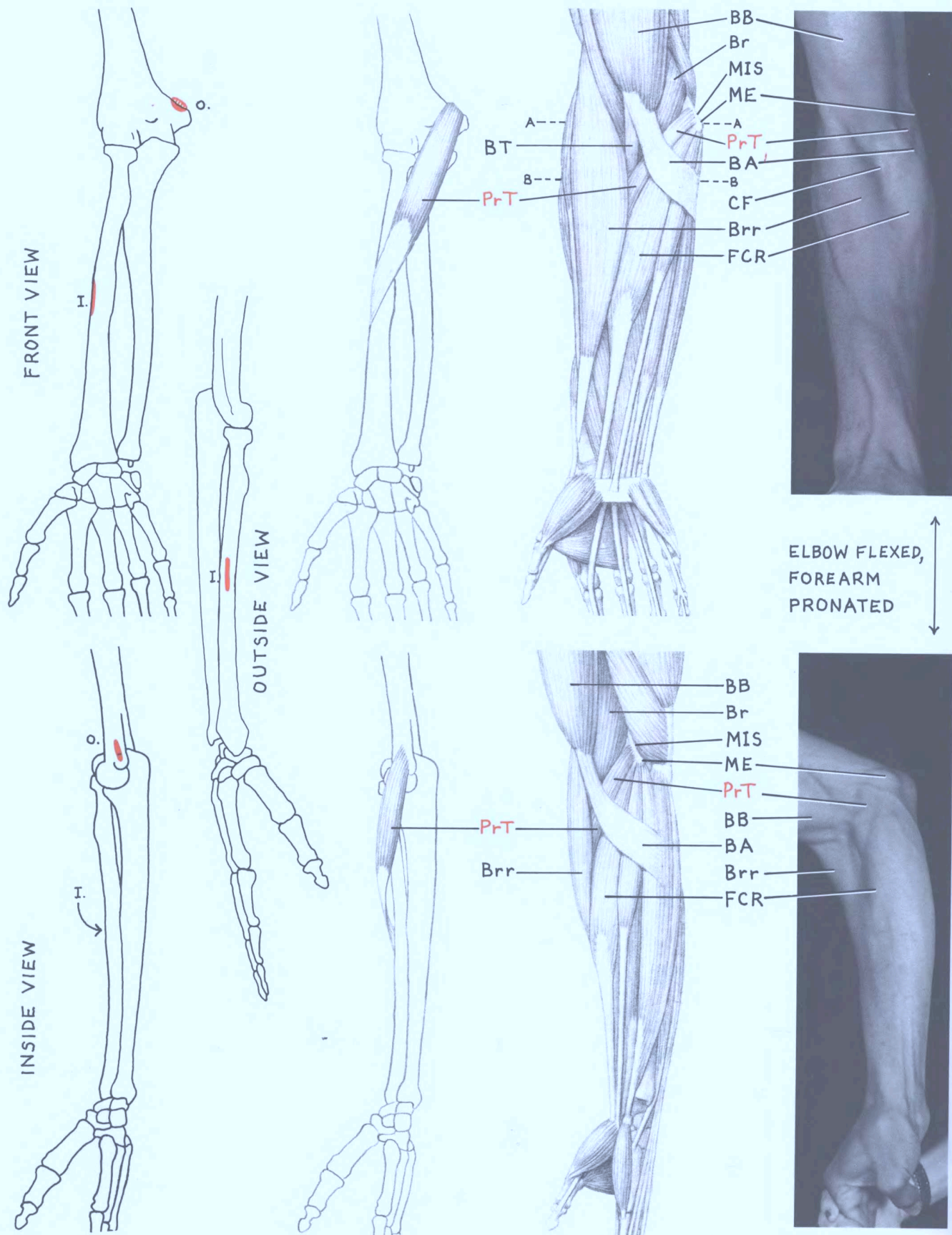
The tendon frequently sends a tendinous slip to the surface of the muscles of the thumb, which creates a subtle raised ridge on the thenar eminence (on the abductor pollicis brevis) when the thumb is abducted.

The palmaris longus is reported to be absent in approximately twelve percent of the population.



PAp Palmar aponeurosis PQ Pronator quadratus Ra Radius ThE Thenar eminence U Ulna
* To ring finger

The Forearm Muscles • PRONATOR TERES



BA Bicipital aponeurosis BB Biceps brachii Br Brachialis Brr Brachioradialis BT Biceps tendon
 CF Cubital fossa FCR Flexor carpi radialis FDS Flexor digitorum superficialis H Humerus
 ME Medial epicondyle MIS Medial intermuscular septum PrT Pronator teres Ra Radius
 TMe Triceps—medial head U Ulna

The Forearm Muscles • PRONATOR TERES

Pronator Teres

ORIGIN The medial epicondyle of the humerus and the adjacent anterior surface of the bone. The origin is located immediately proximal to the origin of the common flexor tendon of the forearm flexors. It also originates from the common flexor tendon itself, as well as from the medial intermuscular septum of the upper arm.


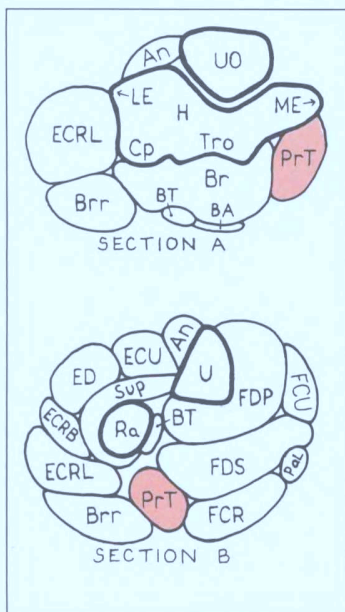
INSERTION A short, rough, vertical line located halfway down the lateral surface of the radius (at its point of maximum convexity).

ACTION Pronates the forearm; assists in flexing the elbow joint.

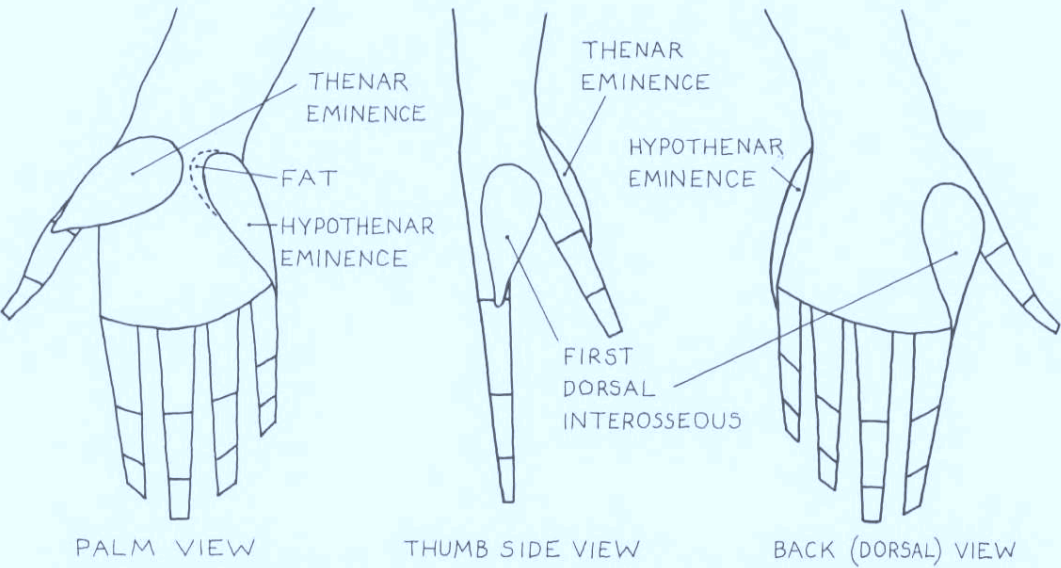
STRUCTURE The pronator teres is a short, fleshy, cylindrical muscle which begins slightly

higher than, and then contributes to, the flexor mass on the forearm. The distal end of its belly, covered by the brachioradialis, ends in a flat tendon before inserting. Although the pronator teres is for the most part superficial, it is difficult to see in isolation; its oblique form is most likely to be seen when the elbow is partially flexed, the forearm pronated, the wrist fully extended, and all the muscles tensed. It is separated from the brachioradialis by a small triangular interval, the **cubital fossa**, best seen in the aforementioned position.

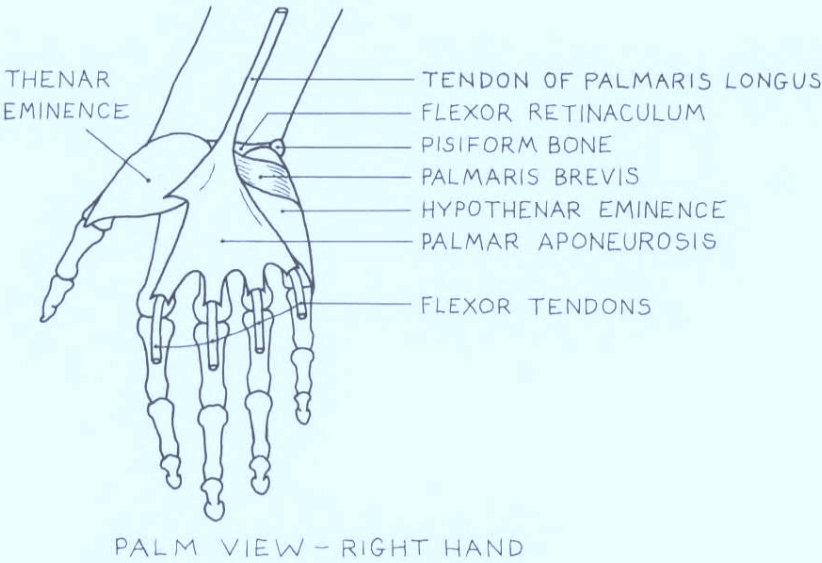
The form of the pronator teres is not affected by the constricting action of the bicipital aponeurosis. The ulnar head of this muscle is small and deep; it has no effect on surface form.



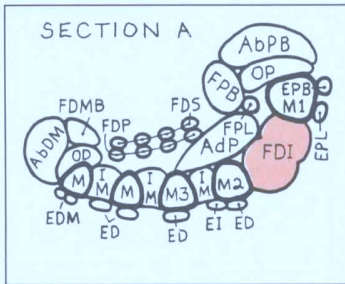
The Hand Muscles



**3 TEARDROP MUSCLE MASSES OF HAND
(RIGHT HAND)**



The Hand Muscles • FIRST DORSAL INTEROSSEOUS



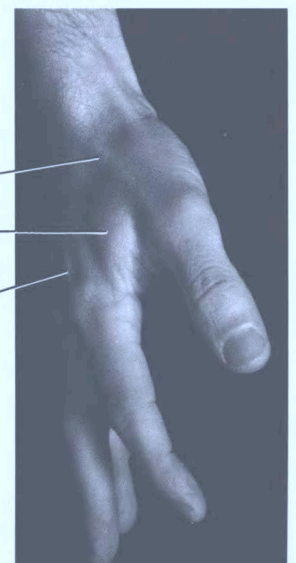
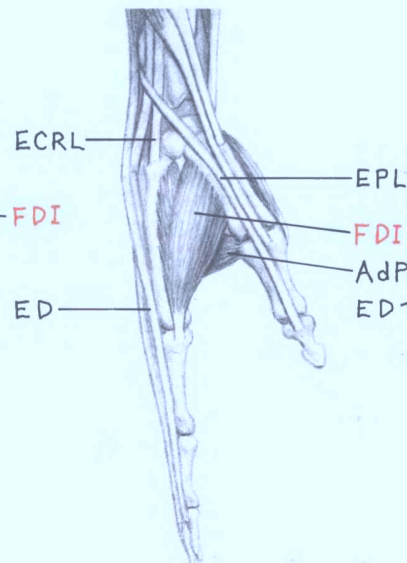
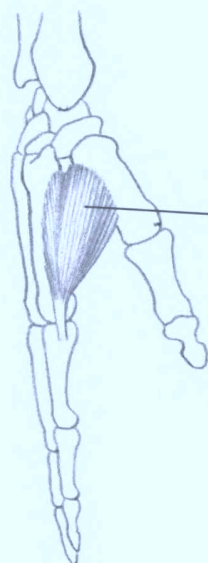
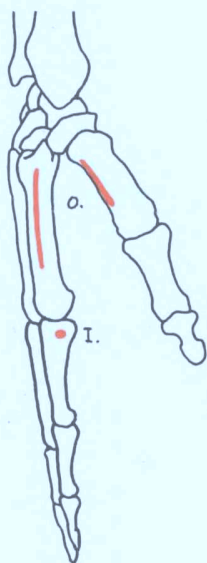
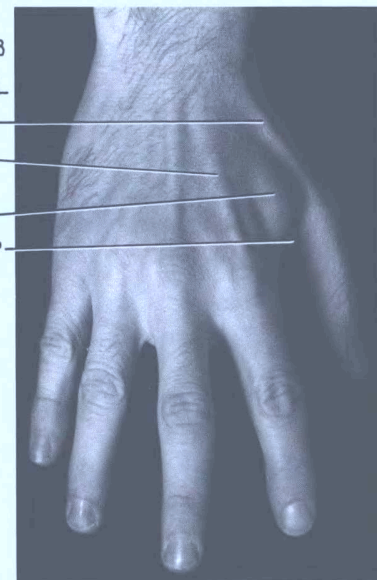
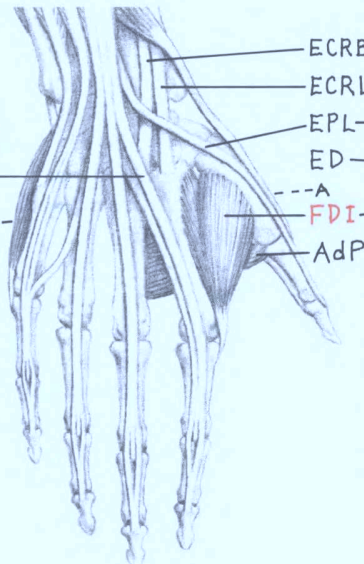
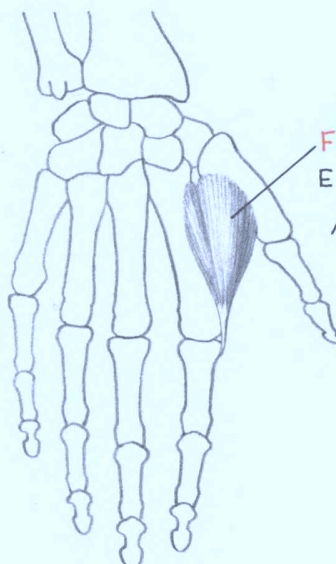
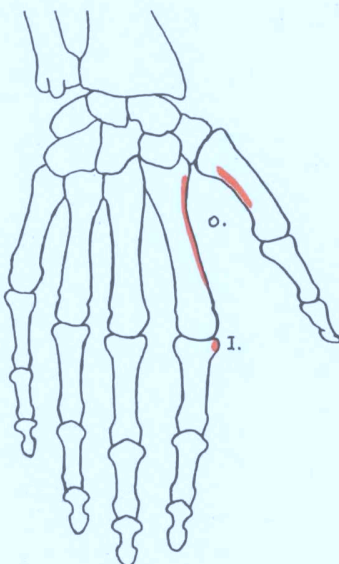
First Dorsal Interosseous (Abductor Indicis)

ORIGIN Proximal half of the ulnar side of the shaft of the metacarpal of the thumb and the proximal three-fourths of the radial side of the shaft of the metacarpal of the index finger (a V-shaped origin).

INSERTION Radial side of the base of the proximal phalanx of the index finger, with a small attachment to the dorsal extensor aponeurosis of the index finger.

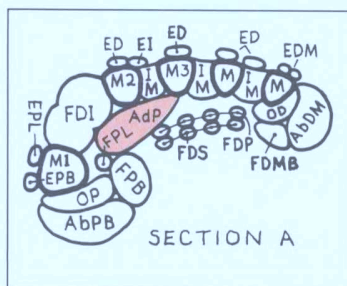
ACTION Adducts the index finger away from the middle finger; flexes its metacarpophalangeal joint; extends both interphalangeal joints via the dorsal extensor aponeurosis. It does not adduct the metacarpal of the thumb.

STRUCTURE The first dorsal interosseous is the largest of the four dorsal interosseous muscles and is the only one that creates surface form. It is located on the back of the hand in the V-shaped interval between the metacarpal bones of the thumb and index finger (the dorsal surfaces of these bones remain subcutaneous). Its two heads, each coming from a metacarpal, usually show up as a single bulging form that is either teardrop-shaped or oval. A slight separation between the heads may occasionally show at the proximal end of the belly when the muscle is tensed. The muscle belly, and therefore its bulging form, tapers into a tendon before reaching the level of the metacarpophalangeal joint.



AbPB Abductor pollicis brevis AdP Adductor pollicis ECRB Extensor carpi radialis brevis
ECRL Extensor carpi radialis longus ED Extensor digitorum EPL Extensor pollicis longus
FDI First dorsal interosseous FDP Flexor digitorum profundus FDS Flexor digitorum superficialis

The Hand Muscles • ADDUCTOR POLLICIS—TRANSVERSE HEAD



Adductor Pollicis—Transverse Head

ORIGIN Distal two-thirds of the palmar surface of the metacarpal of the middle finger.

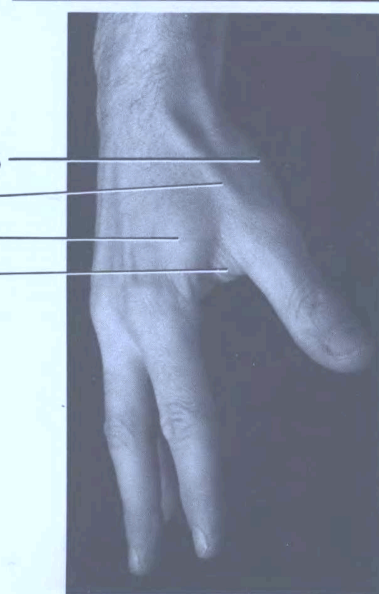
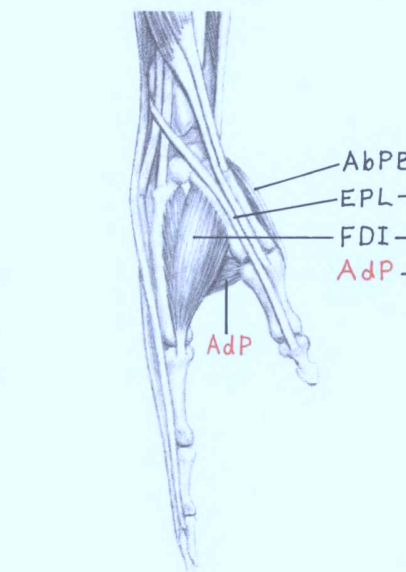
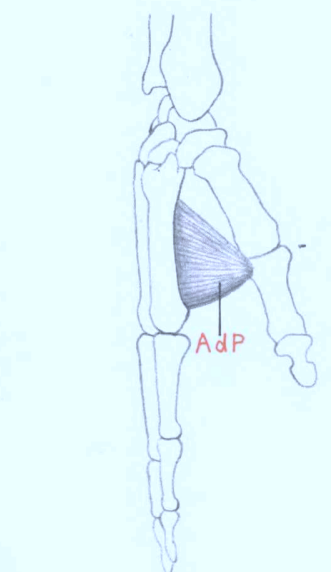
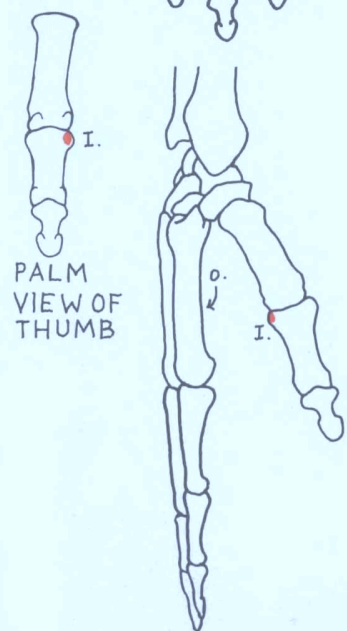
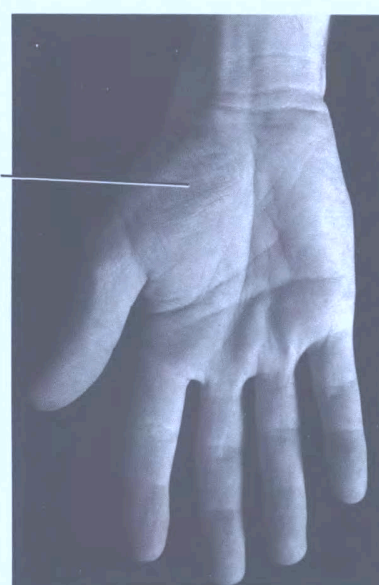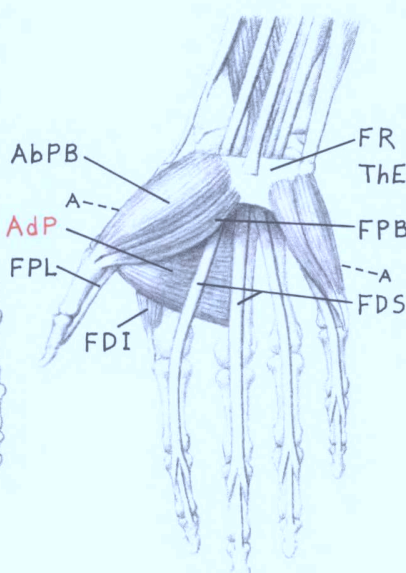
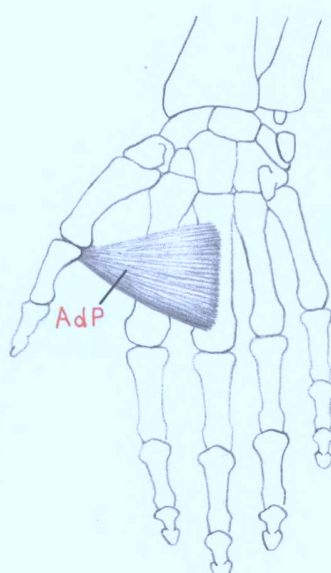
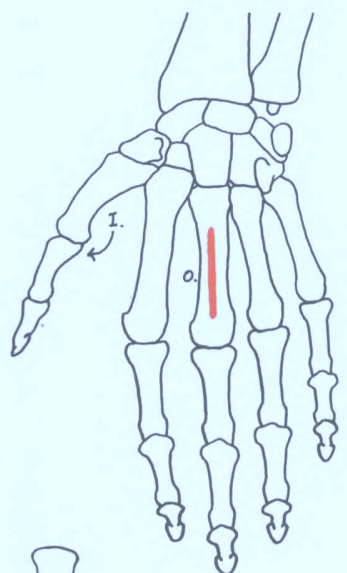
INSERTION Ulnar side of the base of the proximal phalanx of the thumb.

ACTION Adducts and flexes the thumb at the carpometacarpal joint; flexes its proximal phalanx at the metacarpophalangeal joint.

STRUCTURE The flat, triangular, **transverse head** of the adductor pollicis passes from the middle of the palm to the thumb. Barely notice-

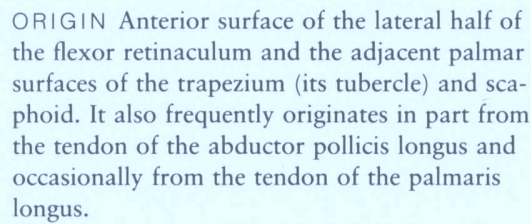
able in life, its palmar surface and distal edge are covered by a layer of loose skin. A small portion, however, can be seen on the dorsal side of the hand between the first dorsal interosseous and the base of the proximal phalanx of the thumb. The tendon of insertion of the adductor pollicis contains the ulnar sesamoid bone of the metacarpophalangeal joint of the thumb.

The more proximal **oblique head** of the adductor pollicis lies deep to the thenar eminence in the palm.



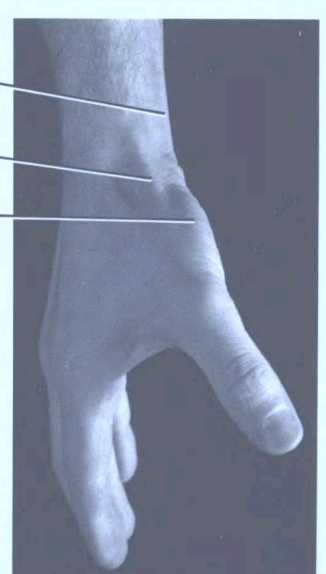
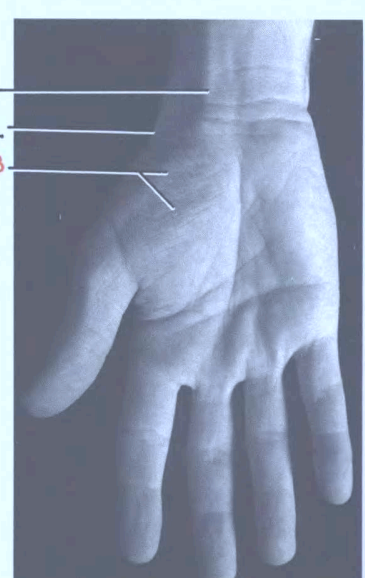
FPB Flexor pollicis brevis FPL Flexor pollicis longus FR Flexor retinaculum IM Interosseous muscle
M Metacarpal ThE Thenar eminence

Abductor Pollicis Brevis



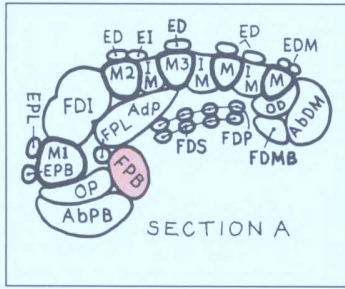
ACTION Abducts the thumb away from (anterior to) the palm (on a plane perpendicular to the palm) at the carpometacarpal joint; it simultaneously rotates the thumb medially at the same joint (a saddle joint). It assists in flexing the metacarpophalangeal joint of the thumb, and by its attachment into the tendon of the

STRUCTURE Largest of the thenar muscles, the abductor pollicis brevis is a flat, elongated, triangular muscle. When the thumb is abducted, the form of this muscle divides longitudinally into two narrow parallel forms: a more prominent *lateral form* that originates from the carpal bones and tendon of insertion of the abductor pollicis longus and a *medial form* that originates from the flexor retinaculum. These forms are produced by the descent of tendinous slips from the tendons of the abductor pollicis longus and palmaris longus onto the surface of the belly of the abductor pollicis brevis. When the thumb is abducted, numerous thin, transverse skin wrinkles develop across the surface of this muscle.



214

The Hand Muscles • FLEXOR POLLICIS BREVIS



Flexor Pollicis Brevis

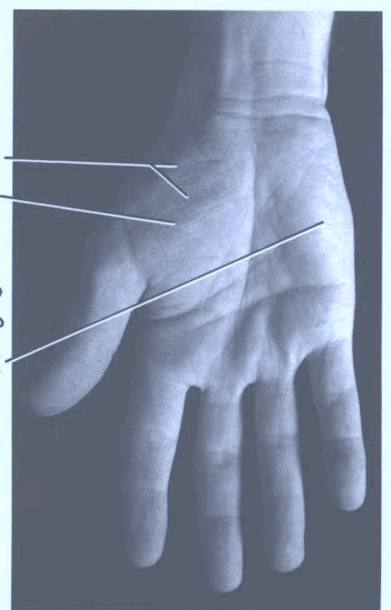
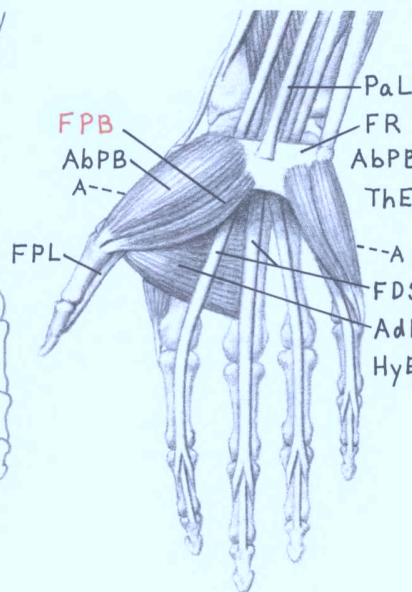
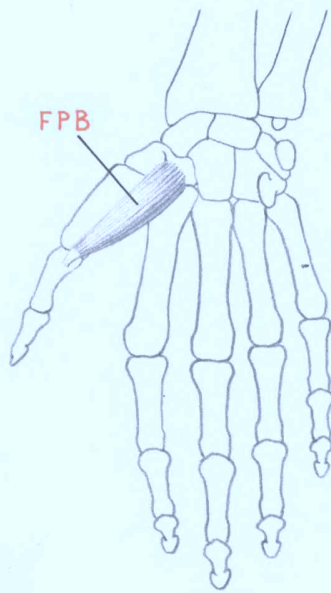
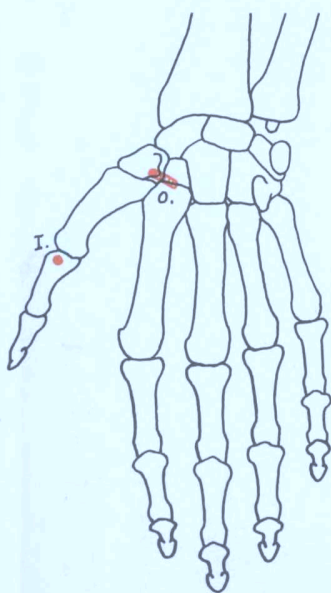
ORIGIN Palmar surface of the trapezium (an area medial and distal to the origin of the abductor pollicis brevis) and the distal border of the lateral half of the flexor retinaculum.

INSERTION Radial and part of the palmar side of the base of the proximal phalanx of the thumb.

ACTION Flexes the proximal phalanx of the thumb; assists in opposition of the thumb against the other fingers. It also assists in me-

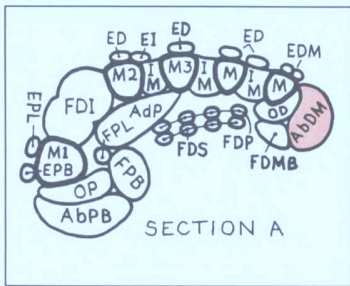
dial rotation of the metacarpal of the thumb at the carpometacarpal joint.

STRUCTURE The flexor pollicis brevis is a small, narrow muscle, located medial to the abductor pollicis brevis, which contributes to the form of the thenar eminence. Although it is for the most part subcutaneous with its medial edge at the medial border of the thenar eminence, its actual form is usually obscured by a layer of palmar fat. Its tendon of insertion contains the radial sesamoid bone of the metacarpophalangeal joint of the thumb.



FR Flexor retinaculum HyE Hypothenar eminence M Metacarpal OP Opponens pollicis
PaL Palmaris longus ThE Thenar eminence

The Hand Muscles • ABDUCTOR DIGITI MINIMI



Abductor Digiti Minimi

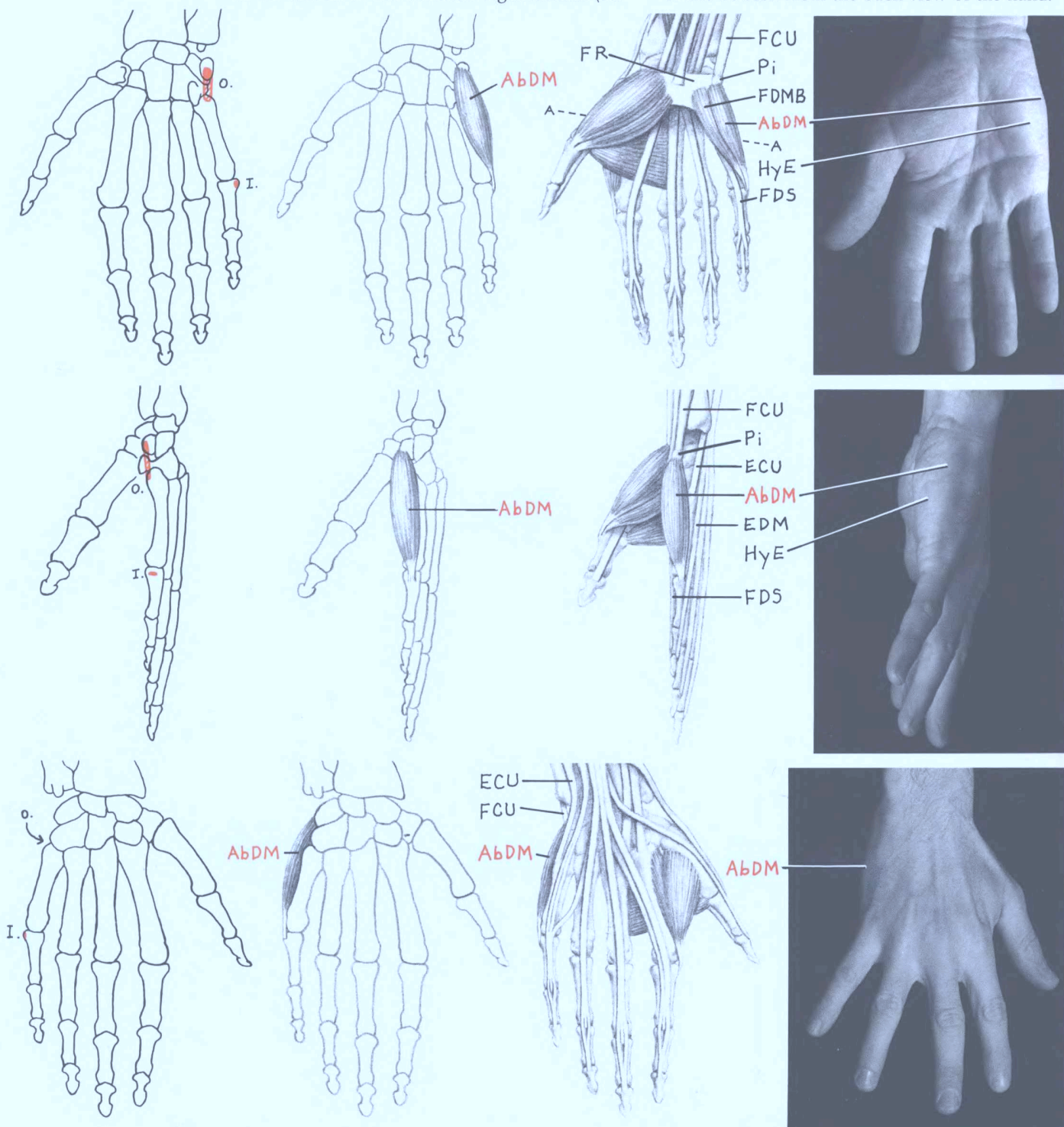
ORIGIN Tip of the pisiform bone and from the anterior surface of the ligament connecting the pisiform bone to the base of the fifth metacarpal.

INSERTION Ulnar side of the base of the proximal phalanx of the little finger (in common with the flexor digiti minimi brevis) and ulnar border of the dorsal extensor aponeurosis of the tendon of the extensor digiti minimi (on

the back of the proximal phalanx of the little finger).

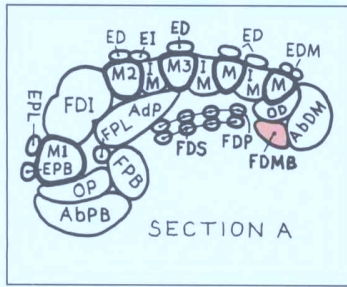
ACTION Abducts and flexes the little finger at the metacarpophalangeal joint; extends the interphalangeal joints (via its insertion into the dorsal extensor aponeurosis).

STRUCTURE The abductor digiti minimi is the largest of the hypothenar muscles. It wraps around the ulnar side of the hand up to the *side* of the metacarpal of the little finger; therefore, it can be seen from the back view of the hand.



AbDM Abductor digiti minimi ECU Extensor carpi ulnaris EDM Extensor digiti minimi
FCU Flexor carpi ulnaris FDMB Flexor digiti minimi brevis FDS Flexor digitorum superficialis

The Hand Muscles • FLEXOR DIGITI MINIMI BREVIS



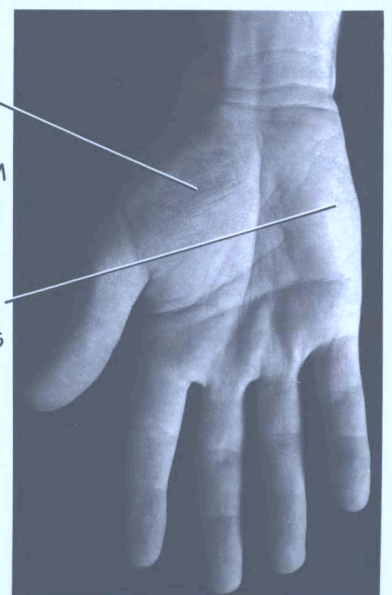
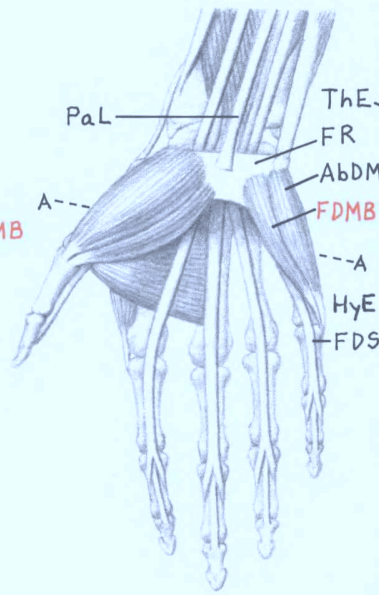
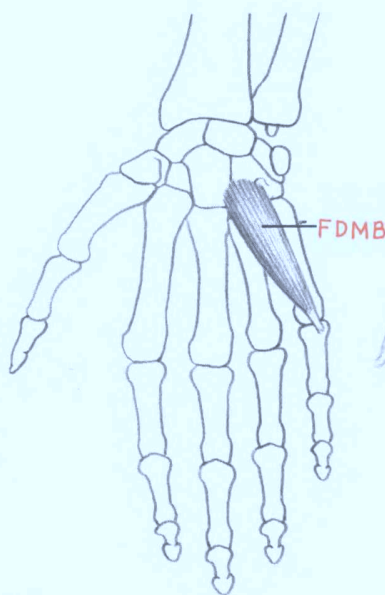
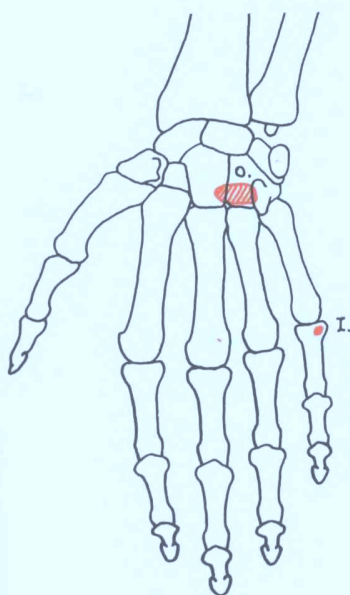
Flexor Digiti Minimi Brevis

ORIGIN Medial surface of the hook of the hamate bone and anterior surface of the medial half of the flexor retinaculum.

INSERTION Ulnar and part of the palmar side of the base of the proximal phalanx of the little finger (in common with the abductor digiti minimi).

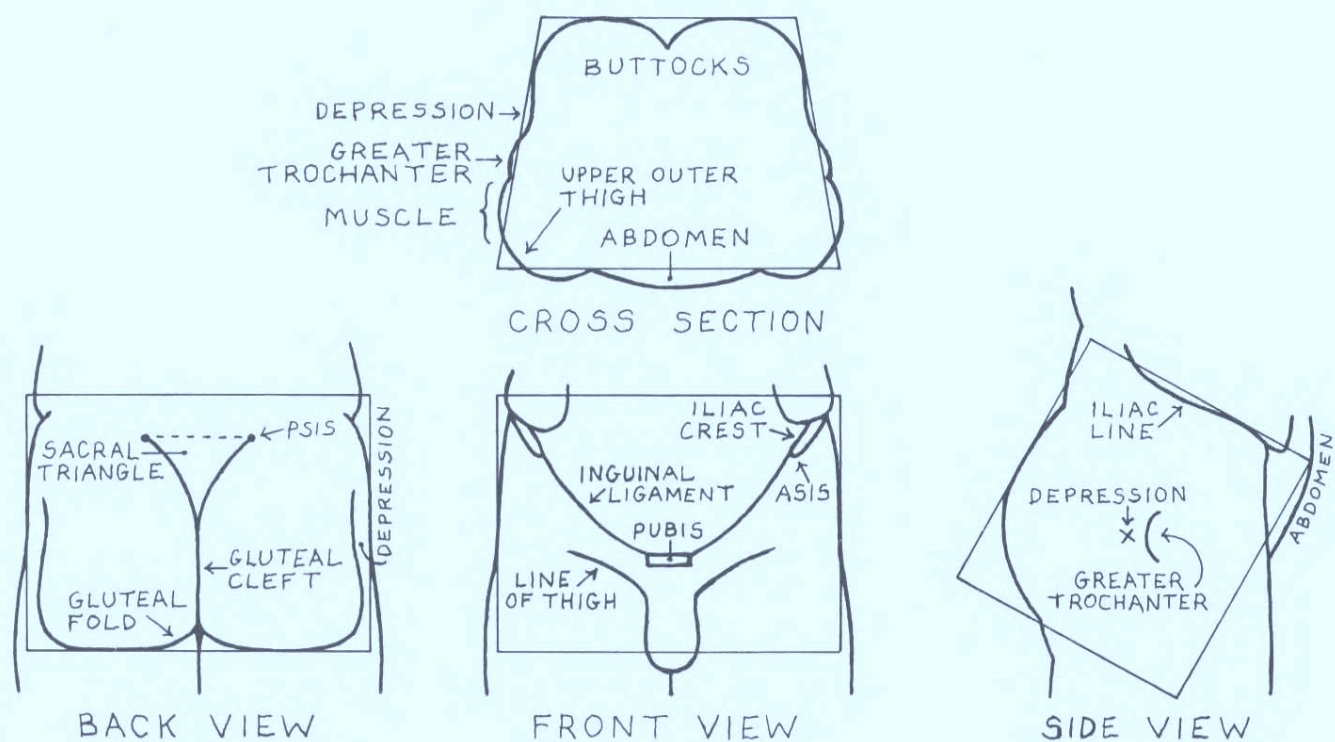
ACTION Flexes the proximal phalanx of the little finger; assists in abducting it.

STRUCTURE The flexor digiti minimi brevis is a very narrow muscle located between the abductor digiti minimi and opponens digiti minimi. Contributing to the volume of the hypothenar eminence, its actual form is obscured by a layer of palmar fat.

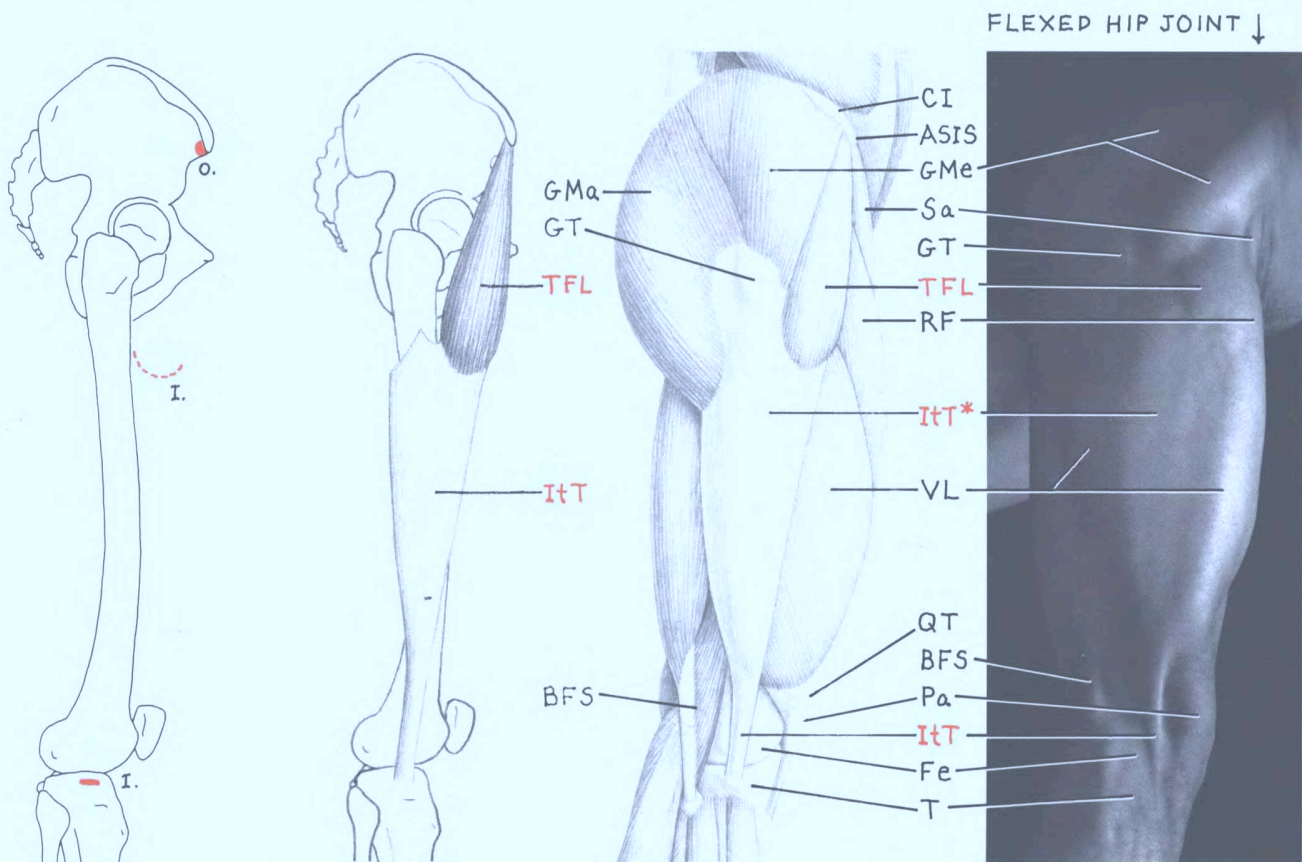
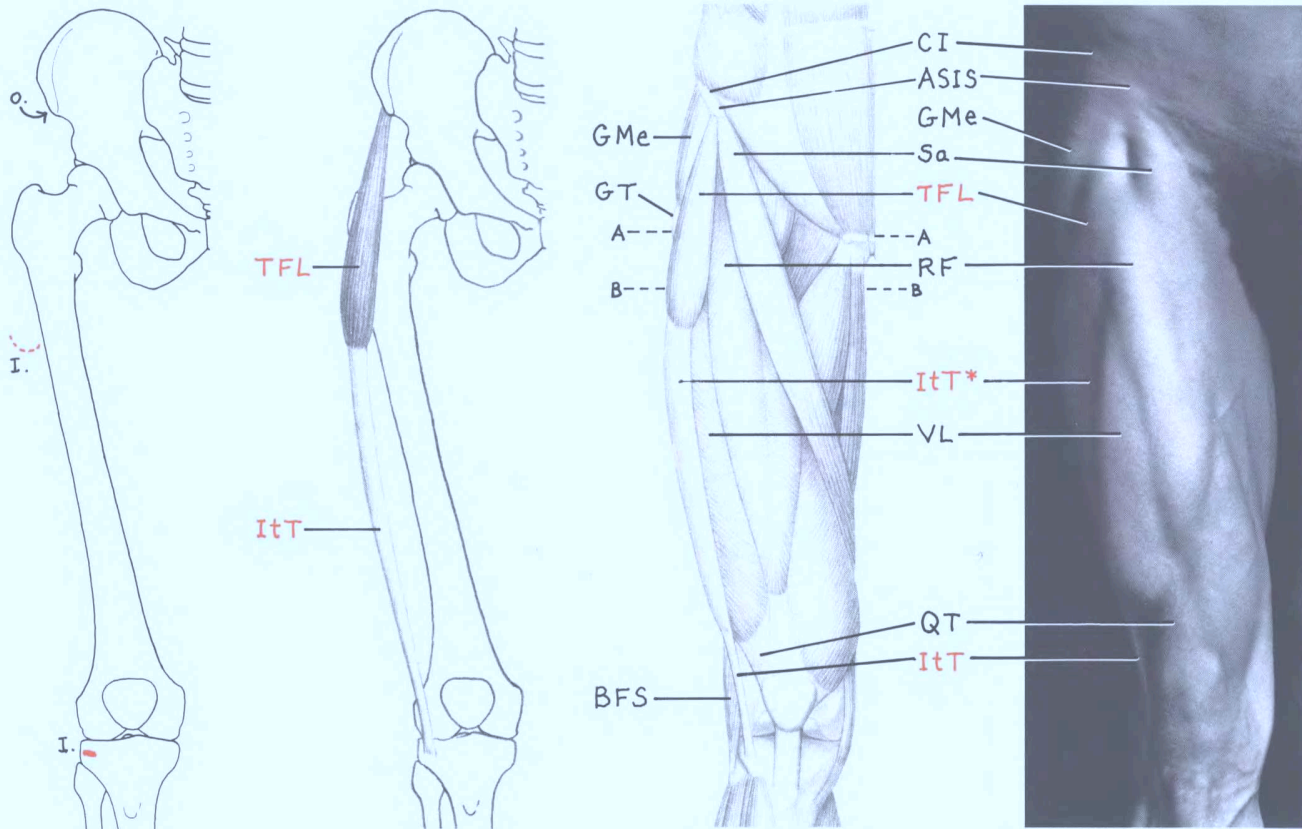


FR Flexor retinaculum HyE Hypothenar eminence M Metacarpal OD Opponens digiti minimi
PaL Palmaris longus Pi Pisiform bone ThE Thenar eminence

The Hip Muscles

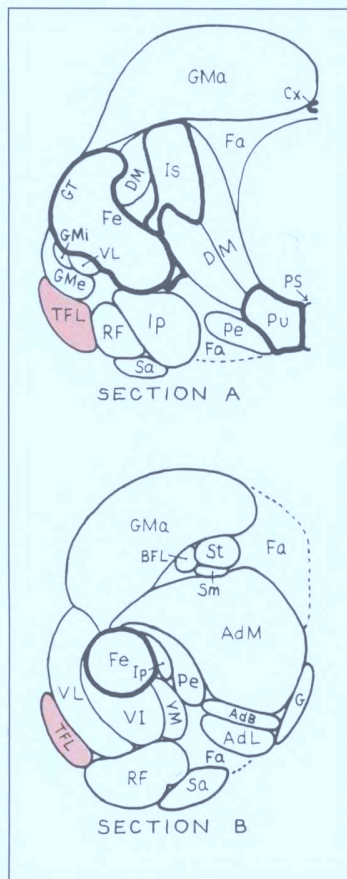


The Hip Muscles • TENSOR FASCIA LATA



ASIS Anterior superior iliac spine BFS Biceps femoris—short head CI Crest of ilium Fe Femur
 GMa Gluteus maximus GMe Gluteus medius GT Greater trochanter ItT Iliotibial tract Pa Patella
 QT Quadriceps tendon RF Rectus femoris Sa Sartorius T Tibia TFL Tensor fascia lata
 VL Vastus lateralis * On vastus lateralis

The Hip Muscles • TENSOR FASCIA LATA



Tensor Fascia Lata

ORIGIN Anterior part of the outer lip of the iliac crest and a small area of the adjacent outer surface of the ilium immediately posterior to the anterior superior iliac spine.

INSERTION The upper portion the iliotibial tract, which in turn inserts into the lateral condyle of the tibia.

ACTION Flexes, abducts, and medially rotates the thigh. The tensor fascia lata pulling on the iliotibial tract stabilizes the outside of the knee joint.

STRUCTURE The tensor fascia lata is a short, thick, teardrop-shaped muscle located on the outer front corner of the pelvis. Its form begins at the front point of the hip and ends where the muscle attaches into the iliotibial band, at a level just below and in front of the greater trochanter of the femur (near the level of the bottom of the buttocks). Its wider, flattened, distal end lies *on top of* the form of the vastus lateralis.

In the standing position, the belly becomes stretched into an elongated oval shape (somewhat pointed inferiorly), but as the thigh is flexed, it changes into its characteristic teardrop shape. As the thigh continues flexing, the distal end widens (front to back). At full hip flexion, the belly is crossed transversely by a deep skin fold.

When the thigh is partly flexed at the hip joint and then medially rotated, the tensor fascia lata partially or completely merges with the anterior portion of the gluteus medius to produce a single, oval, bulging form. When they are distinct from each other, the gluteus medius extends to the bottom of the front edge of the greater trochanter, whereas the tensor descends lower and does not attach to the greater tro-

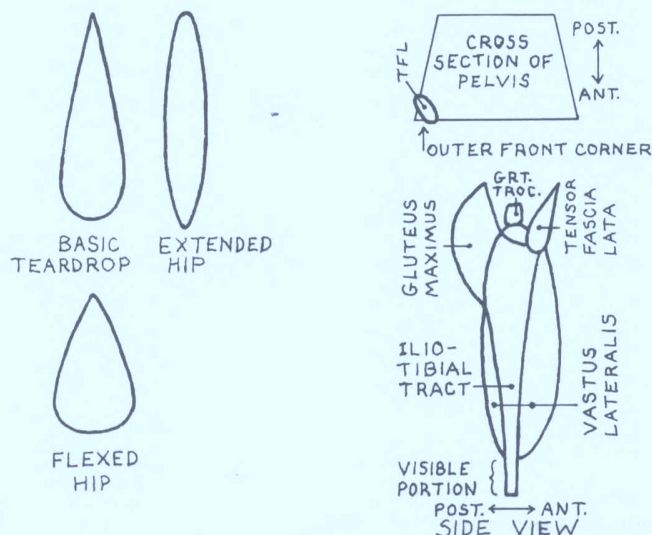
chanter. The tensor muscle is separated from the greater trochanter by fleshy fibers of the gluteus medius.

The lower end of the tensor muscle is often the widest point of the male hips.

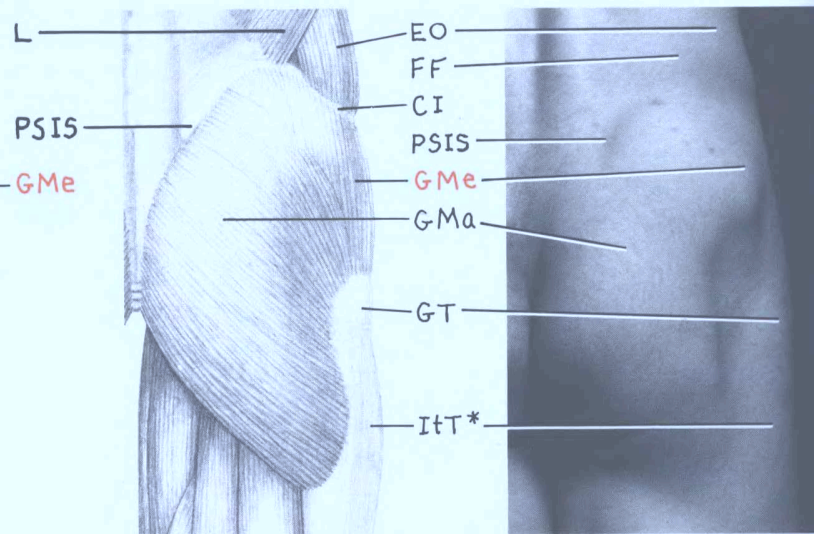
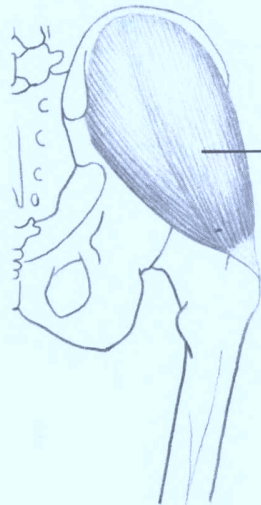
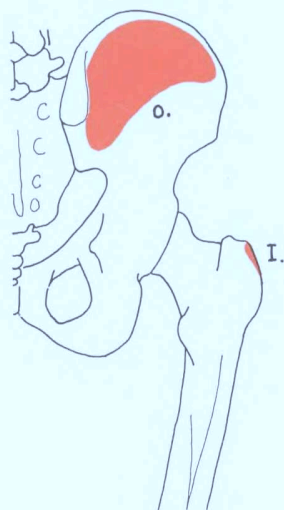
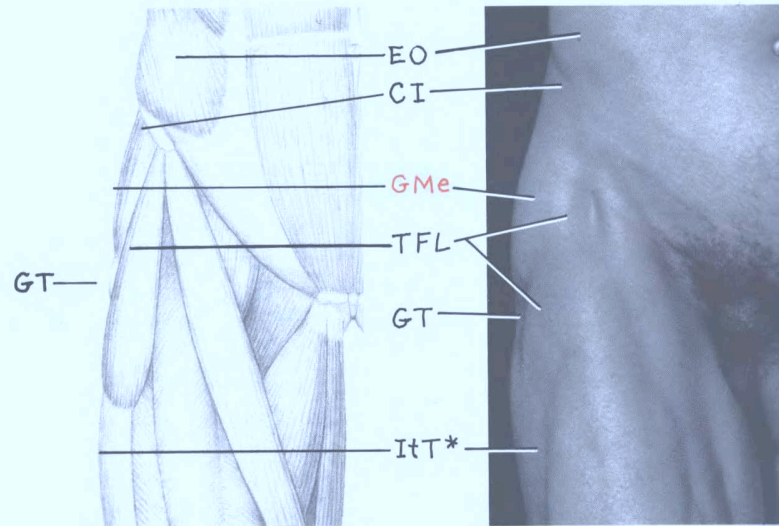
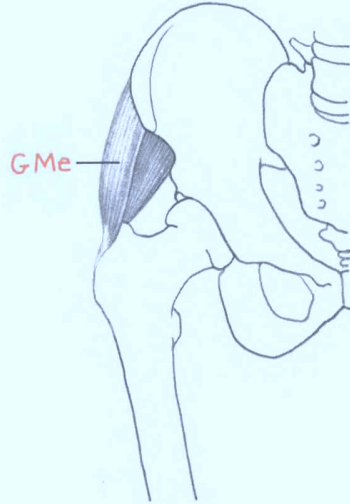
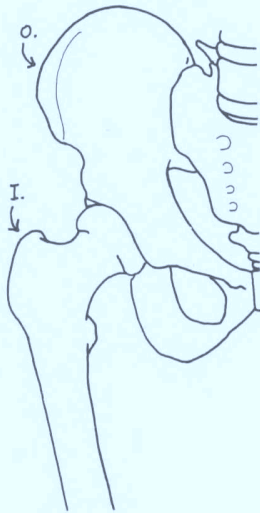
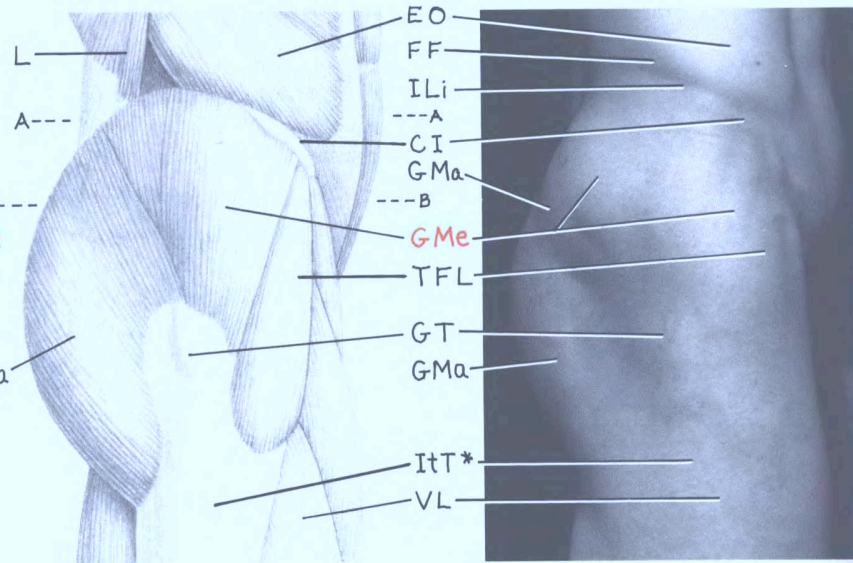
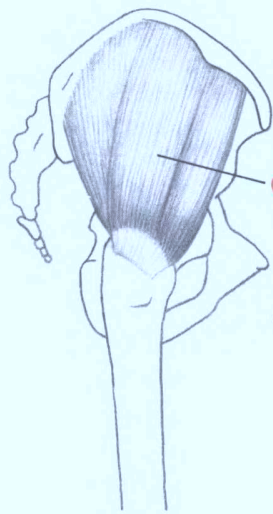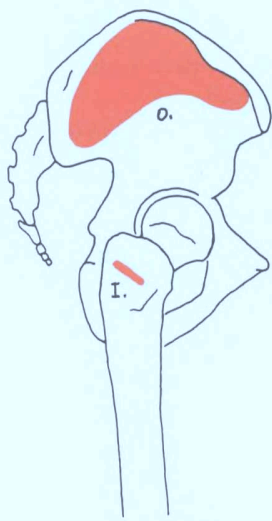
The **iliotibial tract** is a long, wide, thin band that lies on the outer surface of the thigh. It begins superiorly at the level of the greater trochanter and ends inferiorly where it distinctly inserts into the lateral condyle of the tibia. This tract is a *thickening of the normal fascia* that surrounds the entire leg. Both the tensor fascia lata and gluteus maximus insert into its upper end, and the tract functions as their tendon of insertion into the tibia below (it is technically fascia, not tendon). The iliotibial tract wraps around the posterior surface of the vastus lateralis and fuses with the lateral intermuscular septum, which eventually attaches to the linea aspera on the back of the femur.

When the muscles of the leg are tensed, the lower end of the iliotibial tract regularly shows up as a distinct, narrow, vertical form on the outside of the extended knee (after it passes *off* the form of the vastus lateralis). There are no muscle fibers in this form. Its posterior edge continues downward from the posterior edge of the vastus lateralis (seen in side view). This form lies anterior to the belly of the short head of the biceps femoris and is in contact with it or is separated from it by a narrow interval.

As it lies on the vastus lateralis, the thin iliotibial tract has no form of its own. But when pulled taut by the two muscles that attach into its upper end, the iliotibial tract creates numerous long, vertical furrows and ridges in the underlying vastus lateralis muscle mass, much like a pillowcase would do when pulled tight against the surface of a soft pillow inside it (see Vastus Lateralis).



The Hip Muscles • GLUTEUS MEDIUS



CI Crest of ilium EO External oblique FF Flank fat pad GMa Gluteus maximus
GMe Gluteus medius GMi Gluteus minimus GT Greater trochanter I Ilium II Iliacus ILi Iliac line
ItT Iliotibial tract (on vastus lateralis) L Latissimus dorsi PSIS Posterior superior iliac spine
Sa Sartorius Sac Sacrum TFL Tensor fascia lata VL Vastus lateralis

The Hip Muscles • GLUTEUS MEDIUS

Gluteus Medius

ORIGIN Outer surface of a portion of the ilium (pelvis), up to the crest of the ilium.

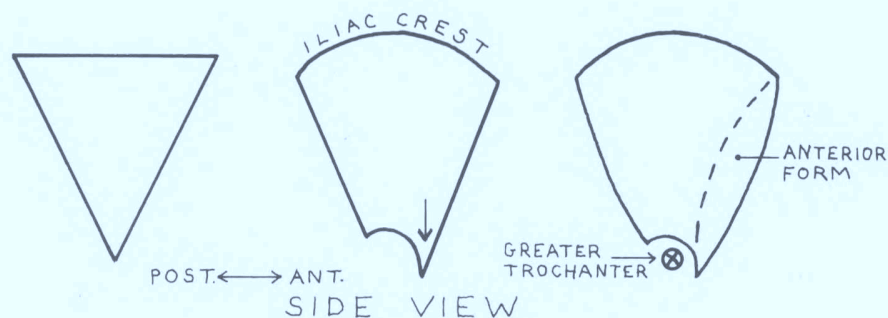
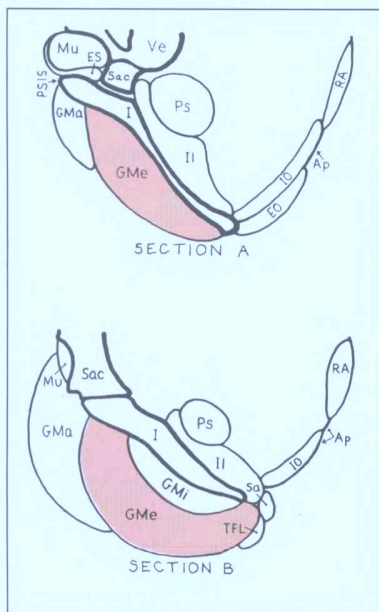
INSERTION A wide oblique line running downward and forward on the outer (lateral) surface of the greater trochanter of the femur.

ACTION Abducts the thigh; keeps the pelvis horizontal during walking when the advancing leg is not in contact with the ground. Posterior fibers extend and laterally rotate the thigh; anterior fibers medially rotate the thigh.

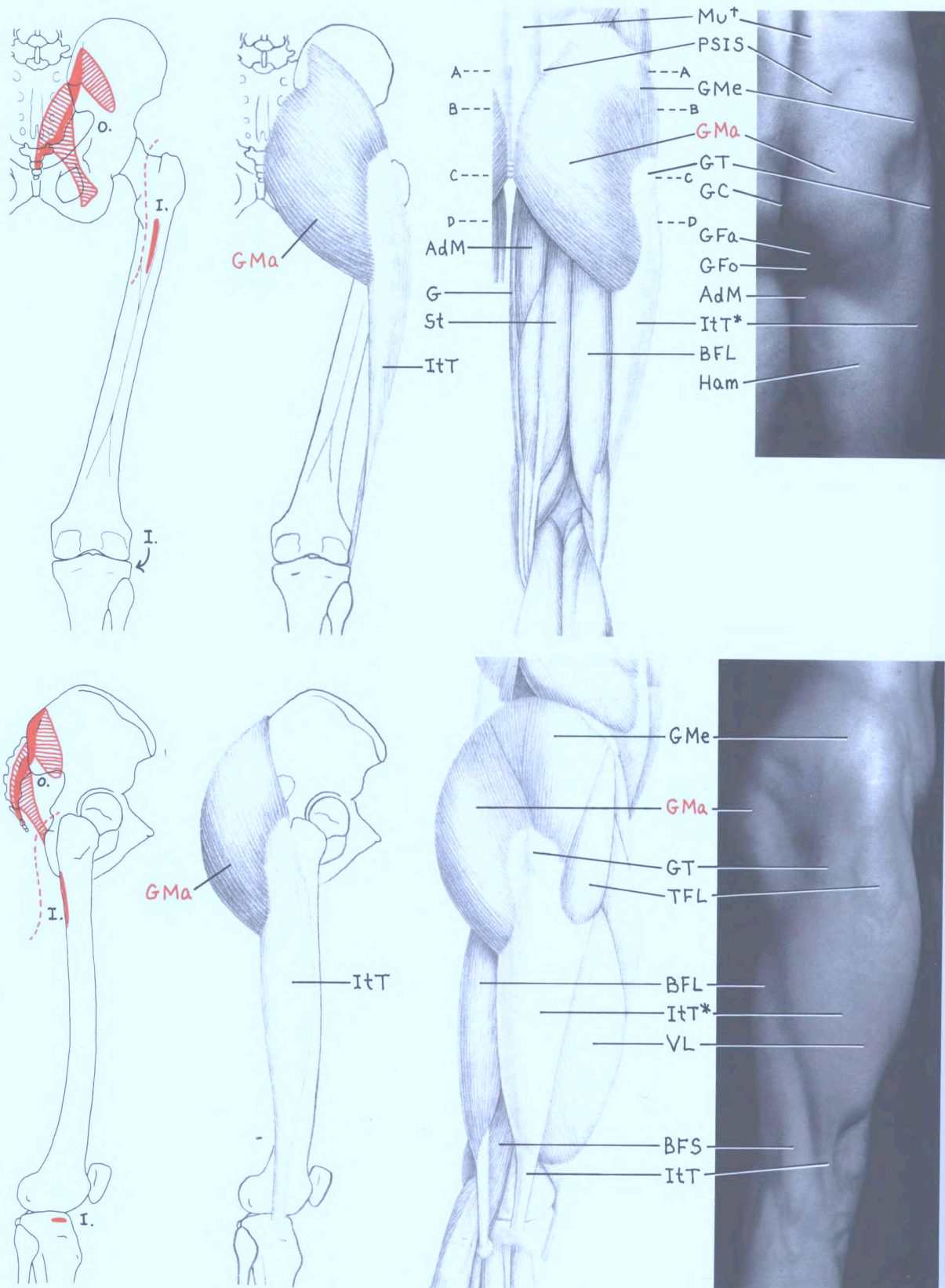
STRUCTURE The gluteus medius is a wide, thick, fan-shaped muscle that tapers inferiorly into a strong flattened tendon at its insertion. The mass of the muscle ends on top and in front of the greater trochanter; its tendon (not visible) continues downward and posteriorly over the surface of the greater trochanter to the actual line of insertion. The form of the greater trochanter is therefore not covered by muscle fibers and is visible. The anterior fibers of the

gluteus medius continue down the front edge of the greater trochanter for a short distance; they can bulge quite considerably during flexion and medial rotation of the femur. This anterior bulge, separate and distinct from the rest of the gluteus medius, is often confused with the tensor fascia lata, but the tensor muscle's form begins from a very small area of origin on the outer front corner of the ilium and ends lower on the thigh than does the gluteus medius (the tensor ends on the surface of the vastus lateralis). The anterior form of the gluteus medius is pointed inferiorly.

The posterior edge of the posterior portion of the gluteus medius is covered by the gluteus maximus. The line between these muscles is occasionally visible, and then only subtly. The posterior portion of the gluteus medius and the anterior portion of the gluteus maximus usually create a single, large, hemispherical form on the outer back corner of the pelvic region when both are tensed.



The Hip Muscles • GLUTEUS MAXIMUS



AdM Adductor magnus BFL Biceps femoris—long head BFS Biceps femoris—short head
 Cx Coccyx DM Deep muscle ES Erector spinae Fa Fat Fe Femur G Gracilis
 GC Gluteal cleft GFa Gluteal fat pad GFo Gluteal fold GMa Gluteus maximus
 GMe Gluteus medius GT Greater trochanter Ham Hamstring muscles I Ilium Is Ischium
 ItT Iliotibial tract Mu Multifidus PSIS Posterior superior iliac spine Sac Sacrum
 Sm Semimembranosus St Semitendinosus TFL Tensor fascia lata VL Vastus lateralis
 * On vastus lateralis † Under erector spinae

The Hip Muscles • GLUTEUS MAXIMUS

Gluteus Maximus

ORIGIN Expanded and roughened posterior fourth or fifth of the crest of the ilium, including the posterior superior iliac spine and the small area below it on the outer surface of the ilium; the posterior surfaces of the lateral edges of the sacrum's lower half and the coccyx (not from the last two coccygeal vertebrae); the sacrotuberous ligament between the sacrum and ischial tuberosity; the sacroiliac ligaments between the sacrum and ilium; the lateral surface of the aponeurosis of the erector spinae (which lies on the multifidus); and the surface of the posterior portion of the gluteus medius.

INSERTION *Upper half:* Upper portion of the iliotibial tract, which ultimately inserts into the lateral condyle of the tibia. *Lower half:* Superficial fibers into the iliotibial tract; deep fibers into the gluteal tuberosity of the femur, which is a thickened vertical line (an upward extension of the linea aspera) on the back of the femur.

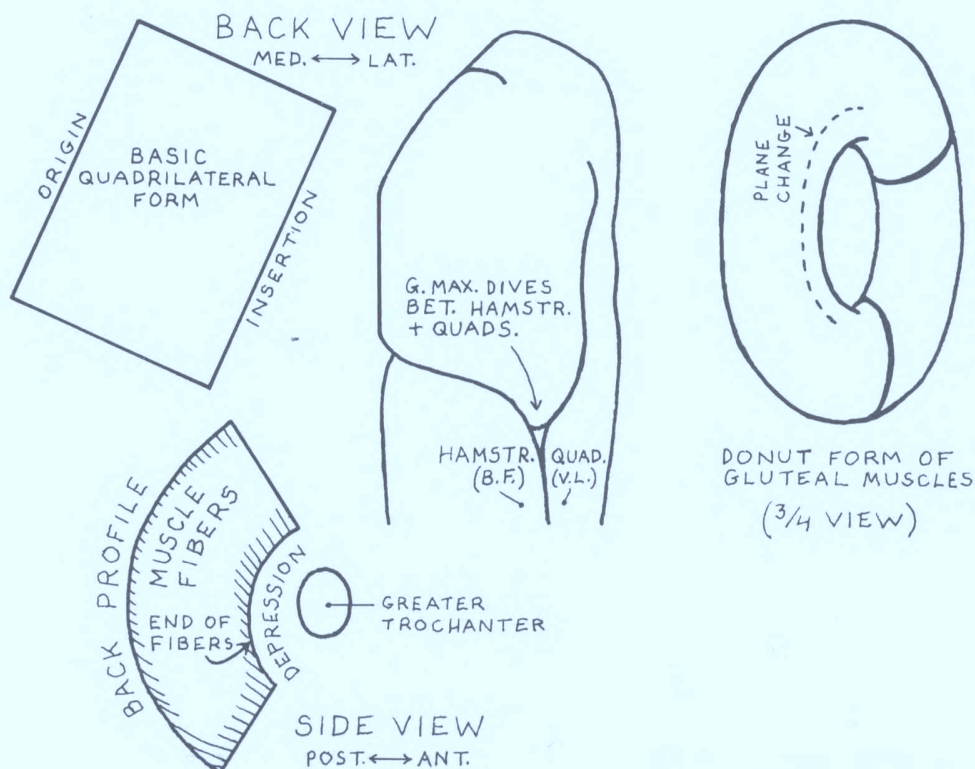
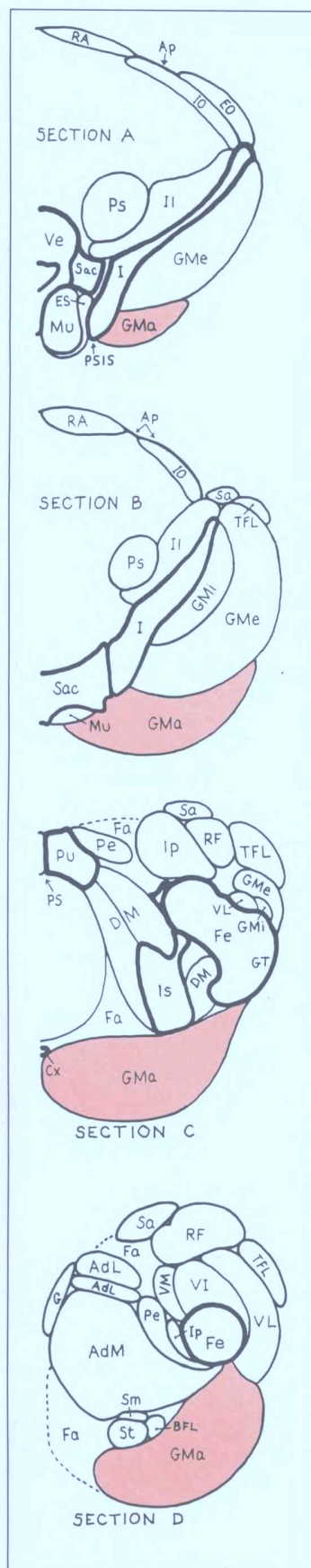
ACTION Powerfully extends and laterally rotates the thigh at the hip joint; extends the pelvis when it is flexed forward. The upper fibers assist in abducting the thigh; the lower fibers assist in adducting it.

STRUCTURE The gluteus maximus is a thick, fleshy, quadrilateral muscle that forms the ma-

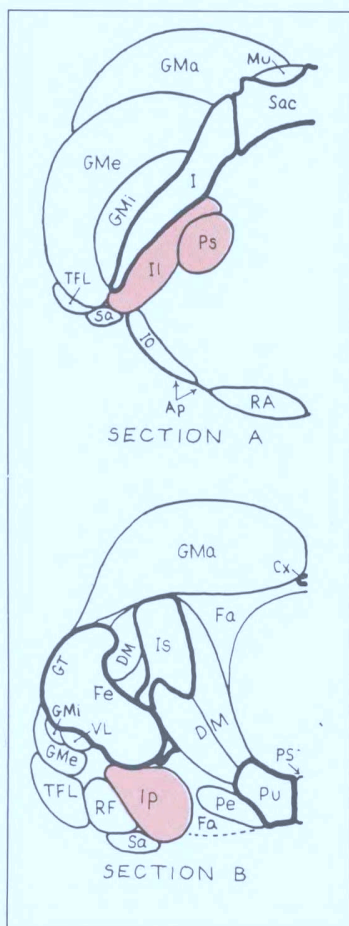
ior volume of the buttock. It is directed downward and outward from its origin and wraps around the outer back corner of the pelvis. It consists of coarse muscle fibers which may at times form several wide, elongated bundles on the surface. The upper edge of the muscle is faintly indicated by a slight furrow where it overlaps the posterior portion of the gluteus medius. Its lower edge, passing from the bottom of the coccyx down to the outside of the leg, is concealed in the standing leg by a crescent-shaped fat pad that lies on the lower inner corner of the muscle. When the hip joint is completely flexed, the lower edge of the muscle may occasionally be seen in its entirety. The gluteus maximus covers the back but not the bottom of the ischial tuberosity, even when the hip joint is flexed, which prevents muscle fibers from getting damaged in the sitting position.

The gluteus maximus and the posterior half of the gluteus medius create a somewhat doughnut-shaped form on the outer back corner of the pelvis. Its back profile (seen in side view) is sometimes rounded almost into a perfect arc of a circle. The lower half of the arc straightens when the muscle is tensed (without the hip joint moving).

The inferior end of the form of the gluteus maximus, on the outer back corner of the thigh, is directed *between* the forms of the vastus lateralis and the long head of the biceps femoris



The Hip Muscles • ILIOPSOAS



Iliopsoas (Iliacus and Psoas Major)

ORIGIN *Iliacus*: Upper two-thirds of the iliac fossa and the base of the sacrum. *Psoas major*: Anterior surfaces and lower borders of the transverse processes of all the lumbar vertebrae; by five slips from the upper and lower margins of the sides of the bodies of the vertebrae and the intervening intervertebral discs, beginning from the lower margin of the last thoracic vertebra and ending at the upper margin of the fifth lumbar vertebra.

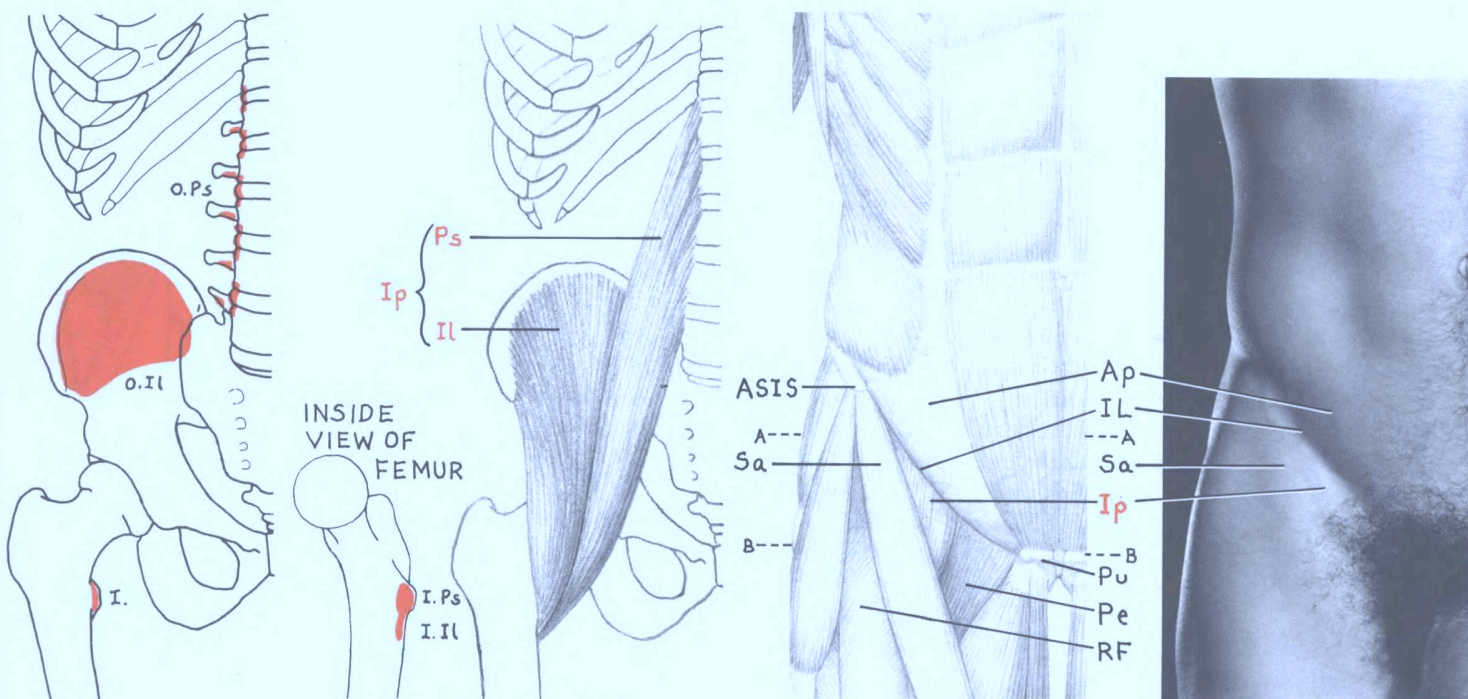
INSERTION *Iliacus*: Lateral side of the tendon of insertion of the psoas major and onto the shaft of the femur for an inch or so immediately below and anterior to lesser trochanter. *Psoas major*: Lesser trochanter of the femur.

ACTION Powerful flexor of the hip joint; it flexes the thigh (when kicking) or pelvis (and trunk—when doing a sit-up). It also laterally rotates the thigh. The psoas assists in flexing the lumbar vertebrae.

STRUCTURE The iliopsoas is made up of the large, flat, triangular *iliacus* and the fusiform

psoas major. Considered as a single muscle group, it begins deep in the back of the abdomen and converges toward its insertion on the inner back corner of the femur. It passes down the bony notch on the front of the acetabulum of the pelvis (directly in front of the hip joint), just below the anterior *inferior* iliac spine. Coursing downward under the inguinal ligament, the iliopsoas becomes partly subcutaneous as it leaves the abdomen, but soon disappears as it dives deep.

The iliopsoas is never prominent. It lies partially under the upper end of the sartorius, which it pushes slightly forward in the extended hip. The superficial portion of the iliopsoas, primarily the *iliacus*, is located just medial to the superior end of the sartorius and immediately below the inguinal ligament. It bulges slightly when the hip is extended. This superficial portion becomes slightly recessed from the surface when the hip joint is flexed (as the sartorius is raised forward). Its form may be seen when the leg is abducted toward the horizontal and laterally rotated, at which time the superficial area is slightly recessed, but appears as a short, downwardly pointed triangular form.



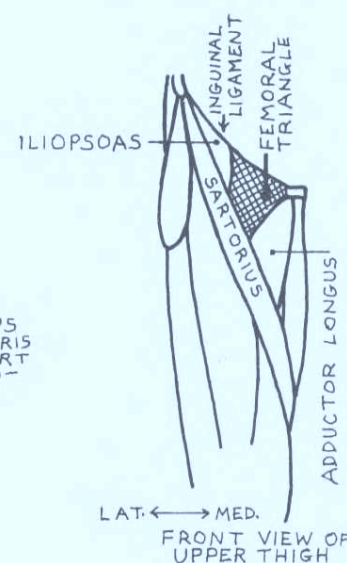
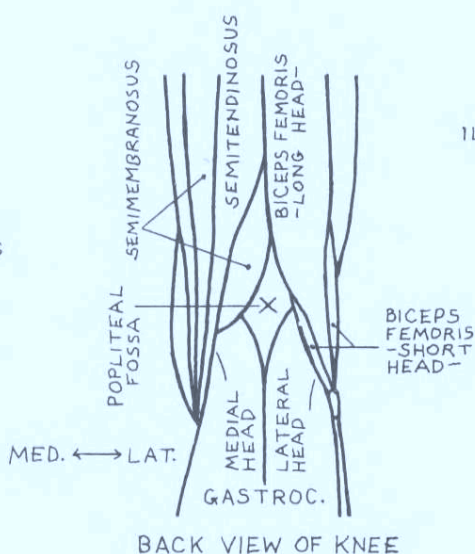
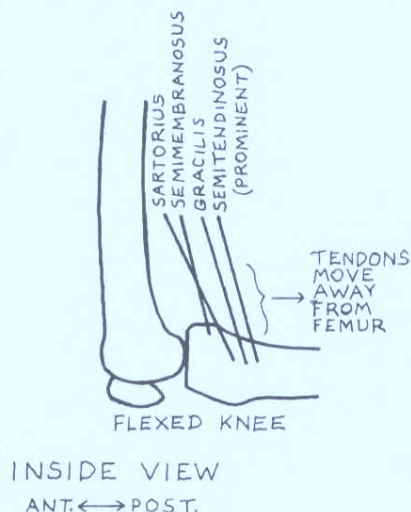
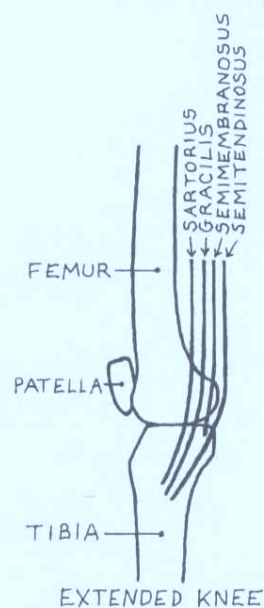
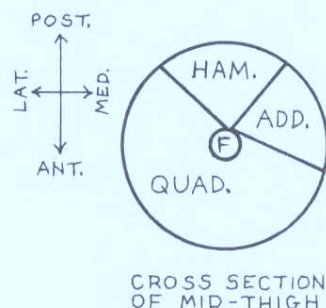
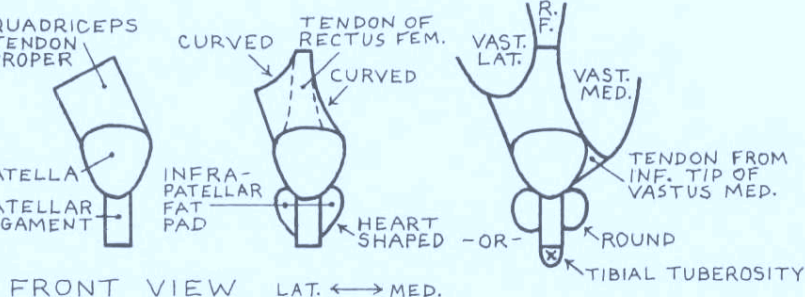
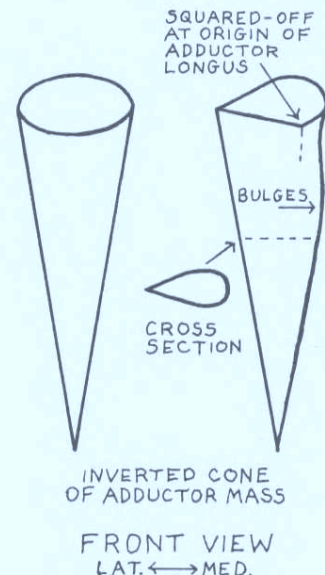
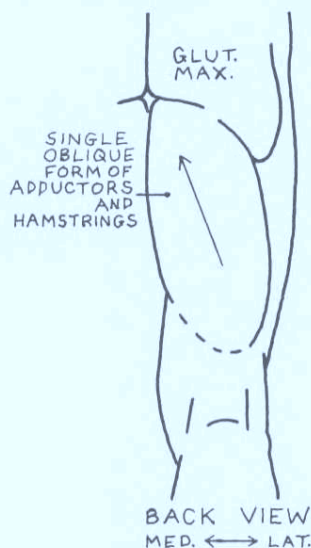
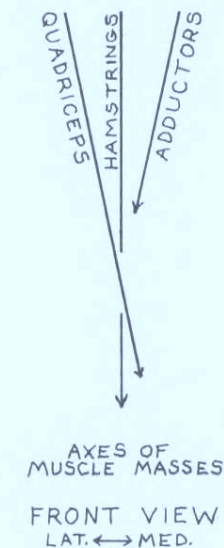
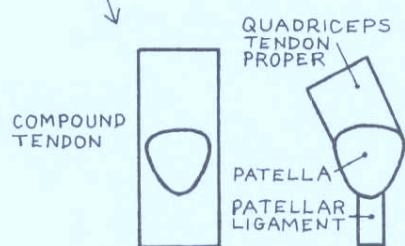
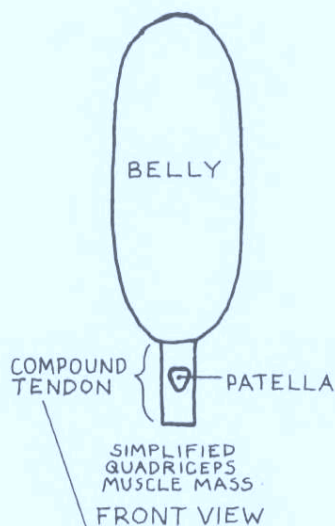
Ap Aponeurosis of external oblique ASIS Anterior superior iliac spine Fa Fat Fe Femur
GMe Gluteus medius I Ilium IL Inguinal ligament II Iliacus IO Internal oblique Ip Iliopsoas
Pe Pectineus PS Pubic symphysis Ps Psoas major Pu Pubis RF Rectus femoris Sa Sartorius

The Upper Leg Muscles

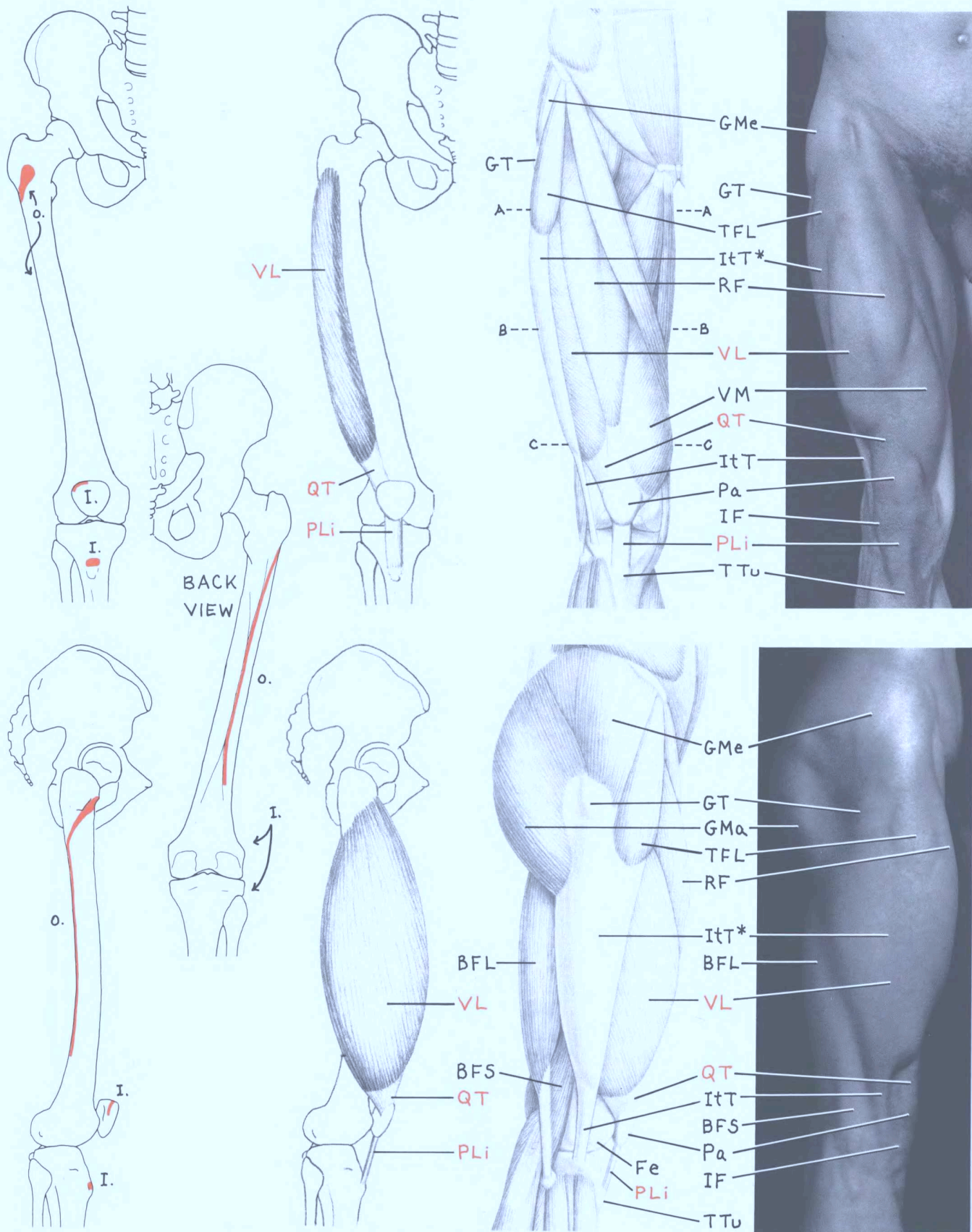
FORMS	QUADRICEPS	
1.	VASTUS MED.	FROM FEMUR
2.	VASTUS LAT.	
(DEEP)	VASTUS INTER.	
3.	RECTUS FEM.	FROM PELVIS

FORMS	HAMSTRINGS	
MED. GROUP	1. SEMITEND.	FROM PELVIS
	2. SEMIMEMB.	
	BICEPS FEM.	
LAT. GROUP	3. -LONG HEAD	FROM FEMUR
	4. -SHORT HEAD	

	ADDUCTORS	
FROM PELVIS	ADDUCTOR LONG.	TO FEMUR
	ADDUCTOR MAG.	
	GRACILIS	
		TO TIBIA



The Upper Leg Muscles • VASTUS LATERALIS



BFL Biceps femoris—long head BFS Biceps femoris—short head Fe Femur GMe Gluteus medius
 GMe Gluteus medius GT Greater trochanter IF Infrapatellar fat pad ItT Iliotibial tract Pa Patella
 PLi Patellar ligament QT Quadriceps tendon RF Rectus femoris TFL Tensor fascia lata
 TTu Tibial tuberosity VI Vastus intermedius VL Vastus lateralis VM Vastus medialis
 * On vastus lateralis

Vastus Lateralis (Vastus Externus)

ORIGIN A line that begins on the front of the greater trochanter of the femur, curves around the outside of the femur below the trochanter, reaches the linea aspera on the midline of the back of the femur, and descends along its lateral lip to end halfway down, or lower, on the bone. It also originates from the lateral intermuscular septum between the vastus lateralis and short head of the biceps femoris.

INSERTION By the quadriceps tendon into the lateral border and upper outer corner of the patella. It ultimately inserts into the tibial tuberosity via the patellar ligament.

ACTION Extends the lower leg at the knee joint (lifts the body from a squatting position by extending the knee joint or lowers the body against the pull of gravity by controlling the rate of knee flexion).

STRUCTURE Largest of the quadriceps muscles, the vastus lateralis occupies the lateral side of the thigh, yet also extends partially around to both the front and back of the thigh. Note that the line of origin begins on the *front* surface at the *top* of the femur, and it is here where its muscle mass begins to bulge forward. The upper portion of the muscle, lying on the *outer* surface of the femur just below the greater trochanter, begins quite thin, but thickens as it descends.

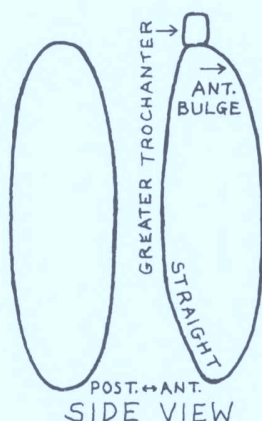
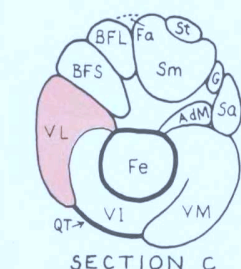
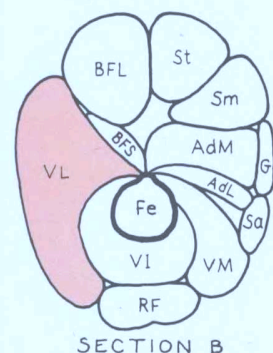
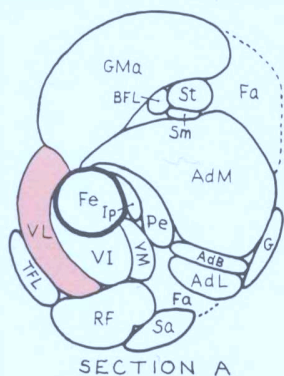
The lower portion of the posterior edge (in side view) may be straight. Its outer surface is somewhat flattened. The muscle mass of the

vastus lateralis ends inferiorly a couple of inches above the top of the patella, at a level lower than the bottom of the rectus femoris and higher than the bottom of the vastus medialis. The muscle fibers do not reach the patella, nor do they cover the lateral condyle of the femur. When the knee is flexed, the vastus lateralis is stretched and becomes thinner.

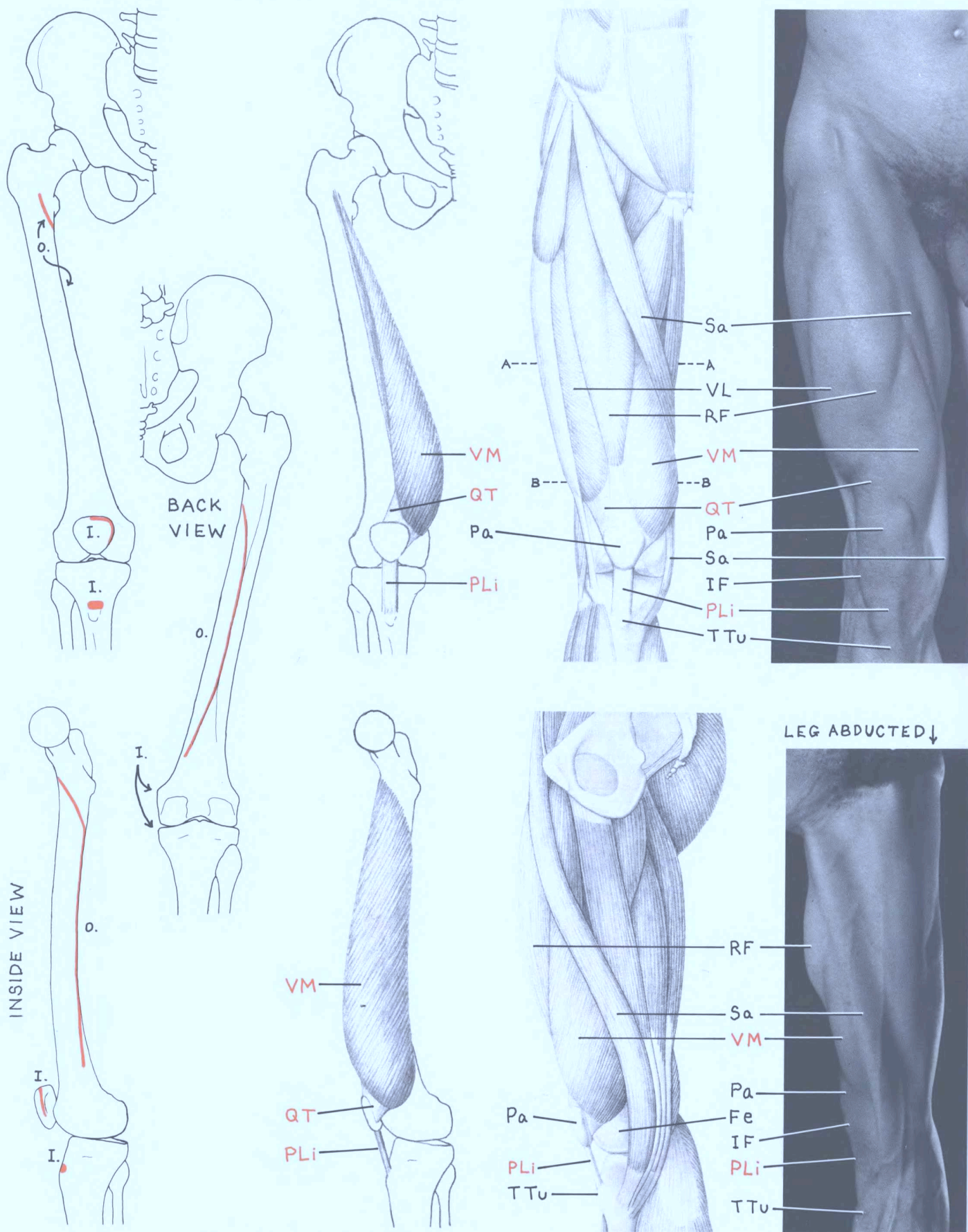
When the iliotibial tract, which lies on top of the vastus lateralis, is pulled taut, one or more longitudinal furrows, elongated flattened planes, and/or raised ridges appear on the outer surface of the belly of the vastus lateralis. Various patterns may emerge. Because the tensor fascia lata and gluteus maximus insert into the superior end of the iliotibial tract, and because the tract ultimately inserts into the lateral condyle of the tibia, the tension furrows and flattenings are usually directed from various parts of these contracting muscles above to the insertion point below.

An oblique furrow directed downward and forward may develop from the bottom of the tensor fascia lata. Because it is not directed toward the outside of the knee, it is not caused by a tensed iliotibial tract, but rather by a portion of the fascia of the leg anterior to the actual tract. At the outside of the knee, the iliotibial tract is continued downward from the *posterior* edge of the vastus lateralis. The tract creates its own elongated surface form after it leaves the surface of the vastus lateralis.

The **vastus intermedius** is an extensive muscle that lies deep to all the other quadriceps bellies, adding muscular fullness under them.



The Upper Leg Muscles • VASTUS MEDIALIS



AdL Adductor longus AdM Adductor magnus Fe Femur IF Infrapatellar fat pad Pa Patella
 PLi Patellar ligament QT Quadriceps tendon RF Rectus femoris Sa Sartorius TTu Tibial tuberosity
 VI Vastus intermedius VL Vastus lateralis VM Vastus medialis

Vastus Medialis (Vastus Internus)

ORIGIN A line beginning on the *front* of the femur at the level of the lesser trochanter which curves around the inside of the shaft of the bone to reach the linea aspera on the back of the femur. It descends along its medial lip, then veers medially into the upper part of the medial supracondylar line of the femur. The vastus medialis also originates from the tendons of the adductor longus and magnus and from the medial intermuscular septum.

INSERTION By the quadriceps tendon into the medial border of the patella and by muscle fibers directly into the patella's upper inner corner. The vastus medialis ultimately inserts into the tibial tuberosity via the patellar ligament.

ACTION Extends the leg at the knee joint.

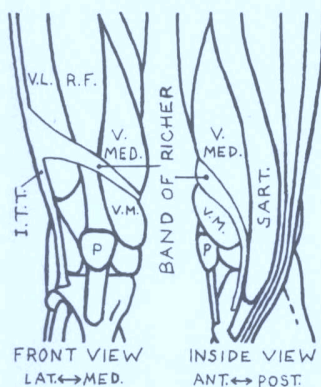
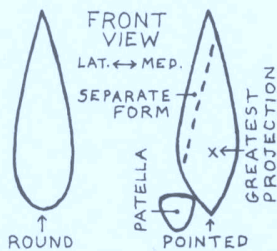
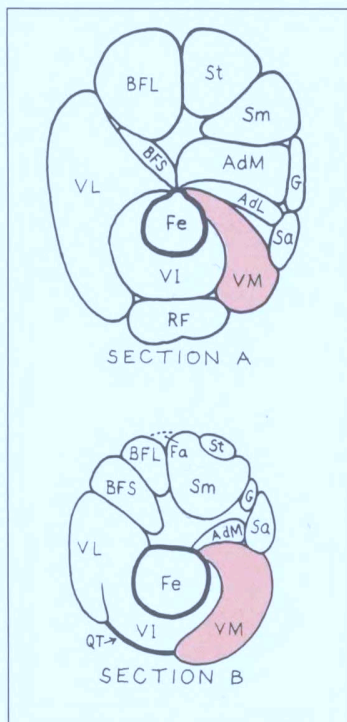
Functionally, the vastus medialis can be divided into two portions. The upper portion, or **vastus medialis longus**, extends the knee. The lower portion, or **vastus medialis oblique**, does not extend the knee, but rather pulls the patella medially and posteriorly to counteract the lateral pull of the vastus lateralis. This keeps the patella tracking in its groove between the femoral condyles.

STRUCTURE Lowest of the quadriceps muscles, the vastus medialis is a bulging teardrop form located on the inner front corner of the lower two-thirds of the thigh. The very bottom of its form ends on the *inside* of the knee (either rounded or pointed), at the level of the *middle* of the patella. Its form touches the upper inner corner of the patella, where an oblique skin fold appears, especially when the muscle is tensed.

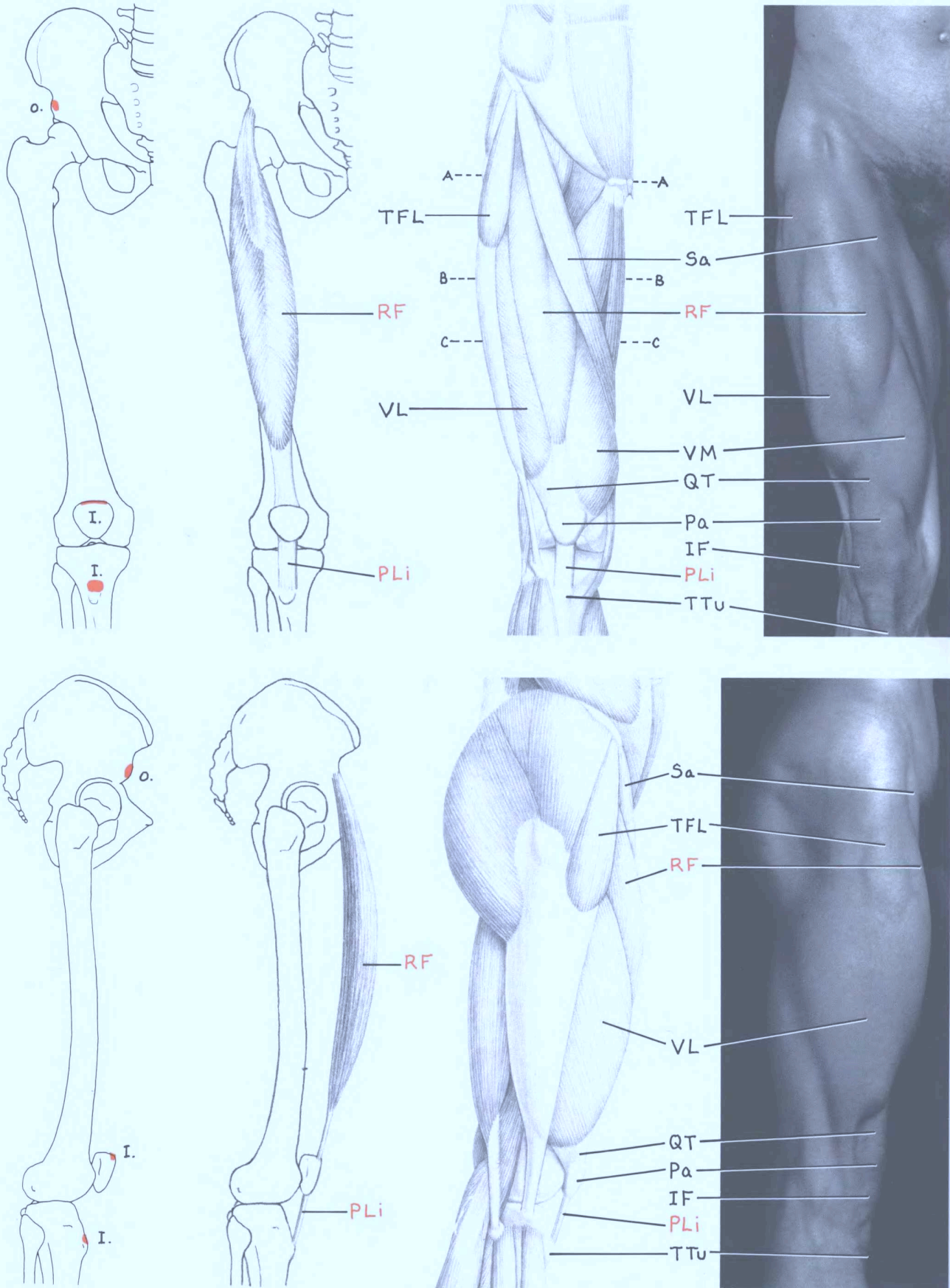
The form of this muscle is thin at the very

top of the shaft of the femur (deep to other muscles) and gets thicker as it descends. When the lower leg is flexed at the knee joint, the medial side of the bent knee appears smooth and rounded, because the fleshy vastus medialis becomes stretched over and blankets the medial condyle of the femur. The muscle, however, does not completely cover the medial condyle, regardless of knee position. In the flexed knee position, a hollow may appear posterior to the vastus medialis, located between the vastus and sartorius. A portion of the vastus medialis lying adjacent and parallel to the rectus femoris occasionally shows up as a separate, elongated, thin form and is sometimes confused with the rectus femoris.

The **band of Richer** is a thickening of the deep fascia of the leg into a nonelastic narrow band. It descends obliquely from the outside to the inside of the leg across the front of the lower portion of the thigh and produces an oblique furrow across the soft muscular forms deep to it. The band technically begins at the iliotibial tract on the outside of the leg, three-fourths of the way down the thigh, and ends on the inside of the knee, inserting as far down as the medial surface of the shaft of the tibia. Most noticeable in the straight leg across the lower end of the vastus medialis and sometimes across the vastus lateralis (it does not affect the rectus femoris), the furrow becomes pronounced when the quadriceps is relaxed, and usually, but not always, disappears when it is tensed. The relaxed vastus medialis can bulge considerably below the band. On the inside of the knee (in front of the sartorius), the band of Richer can sometimes produce a fine, vertical, cordlike raised ridge as its medial end leaves the form of the vastus medialis to insert into the tibia.



The Upper Leg Muscles • RECTUS FEMORIS



Fe Femur IF Infrapatellar fat pad Ip Iliopsoas Pa Patella PLi Patellar ligament
 QT Quadriceps tendon RF Rectus femoris Sa Sartorius TFL Tensor fascia lata TTu Tibial tuberosity
 VI Vastus intermedius VL Vastus lateralis VM Vastus medialis

The Upper Leg Muscles • RECTUS FEMORIS

Rectus Femoris

ORIGIN Anterior inferior iliac spine. (This is the origin of the *straight tendon*. The *reflected tendon*, arising from the top of the acetabulum, is small and deep, with no effect on surface form.)

INSERTION Top of the patella; therefore, it ultimately inserts into the tibial tuberosity via the patellar ligament.

ACTION Extends the leg at the knee joint; flexes the thigh at the hip joint.

STRUCTURE The rectus femoris is one of the four bellies of the quadriceps muscle group. It is the only two-joint muscle in this group, crossing both knee and hip joints. Its belly is long, flattened, and fusiform, sometimes showing a furrow down the middle of its upper half in well-developed individuals. The furrow is caused by the bipennate arrangement of the muscle fibers inserting into its median tendon and therefore divides the belly into lateral and medial forms. The lateral form is larger, higher, and more prominent than the medial form. The lower lateral edge of the belly can be either convex or concave (looking at in front view).

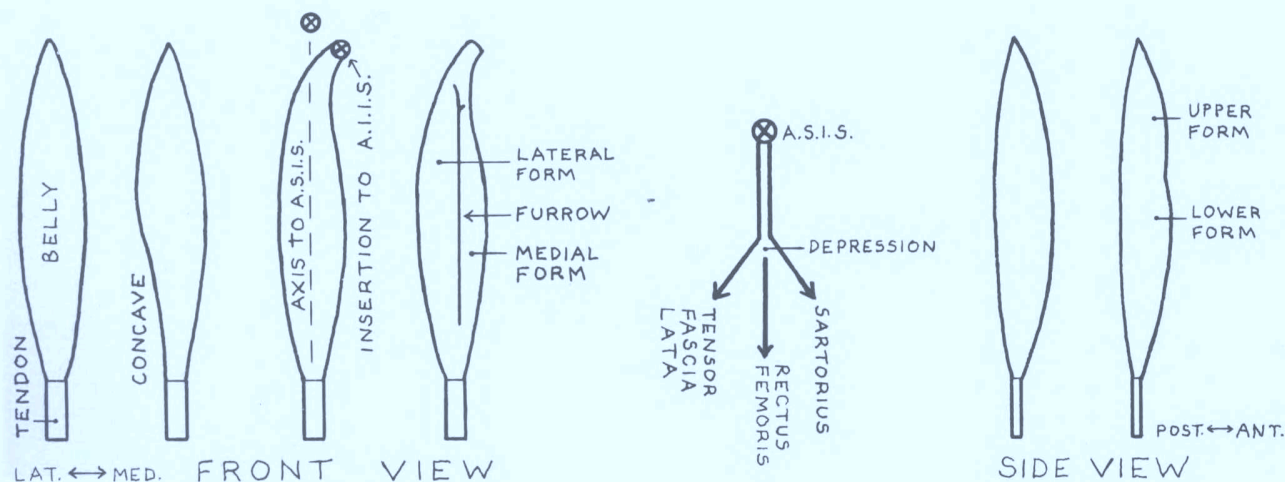
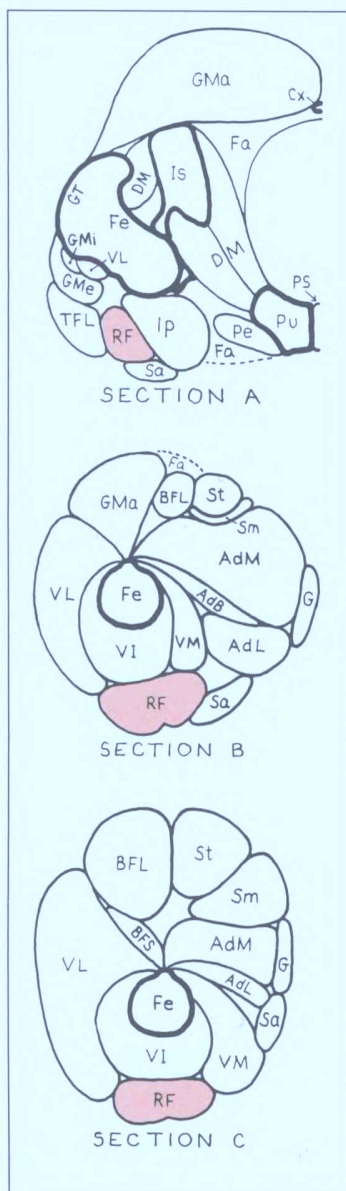
The inferior end of the belly can be quite tapered and pointed, and also slightly depressed, as the vasti muscles bulge on either

side of it. The ribbonlike tendon of insertion attaches to the top of the patella. It lies on, yet is independent of, the quadriceps tendon, and may be seen during partial knee flexion when the quadriceps is contracted.

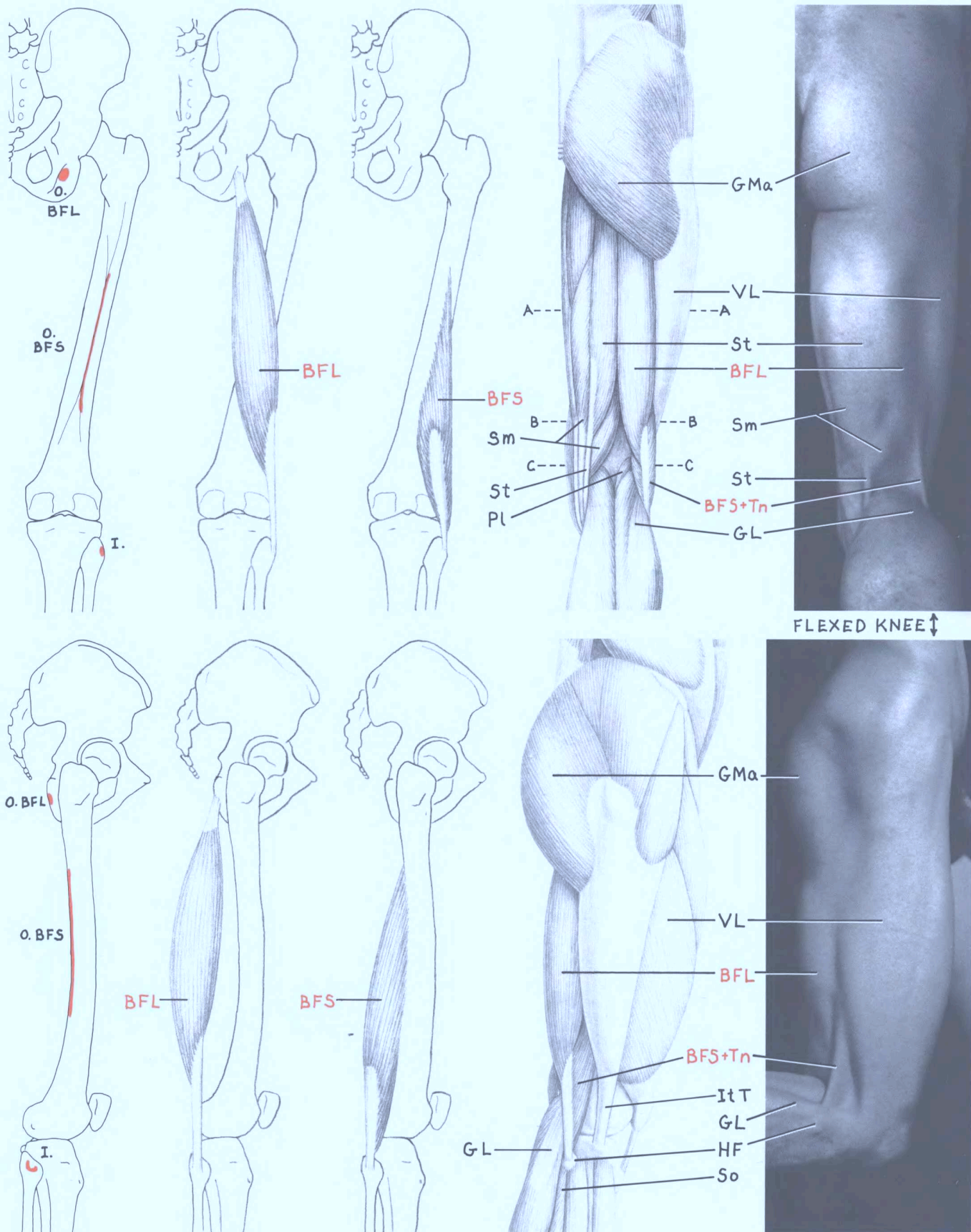
The lower end of the muscular belly of the rectus femoris ends approximately a hand's breadth above the top of the patella. It ends highest of all the quadriceps bellies; the vastus medialis ends the lowest, and the vastus lateralis ends at a level between them.

A depression is present three finger widths below the anterior superior iliac spine of the pelvis; it is especially evident when the thigh is flexed at the hip joint. This depression marks the point where the rectus femoris dives deep between the sartorius and tensor fascia lata, toward its insertion on the anterior inferior iliac spine. The upper end of the rectus femoris is covered by the sartorius. When looking at the figure from the side view with the thigh flexed (as in the sitting position), the top (anterior) surface of the thigh is directed toward the anterior *inferior* iliac spine, the origin of the rectus femoris, not the anterior *superior* iliac spine.

The rectus femoris sits in a muscular groove on the front of the thigh. The vastus intermedius creates the floor of the groove, and the vasti medialis and lateralis form the sides (see cross section).



The Upper Leg Muscles • BICEPS FEMORIS



AdM Adductor magnus BFL Biceps femoris—long head BFS Biceps femoris—short head Fa Fat
 Fe Femur GL Gastrocnemius—lateral head GMa Gluteus maximus HF Head of fibula
 ItT Iliotibial tract PL Plantaris Sm Semimembranosus So Soleus St Semitendinosus T Tibia
 Tn Tendon VL Vastus lateralis

Biceps Femoris

ORIGIN *Long head*: Ischial tuberosity of the pelvis and the adjacent lower part of the sacrotuberous ligament. *Short head*: A line on the middle third of the back of the femur.

INSERTION Outer surface of the head of the fibula (with a tendinous slip to the lateral condyle of the tibia).

ACTION Both heads flex the lower leg at the knee joint and then rotate the tibia laterally; the long head also extends and assists in lateral rotation of the thigh at the hip joint. The long head is a two-joint muscle, while the short head is a one-joint muscle.

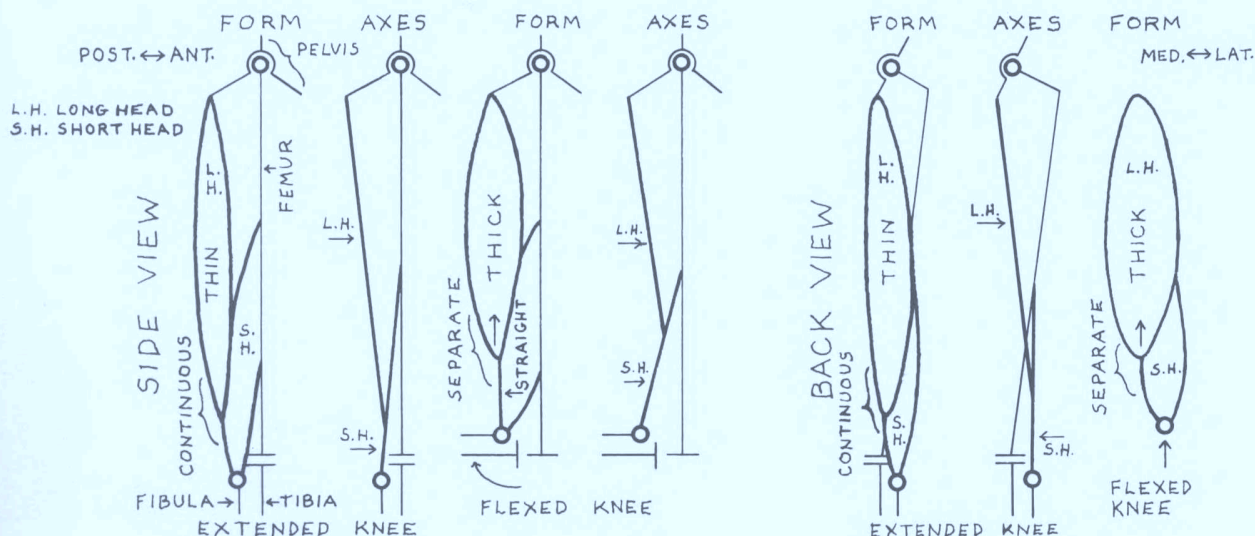
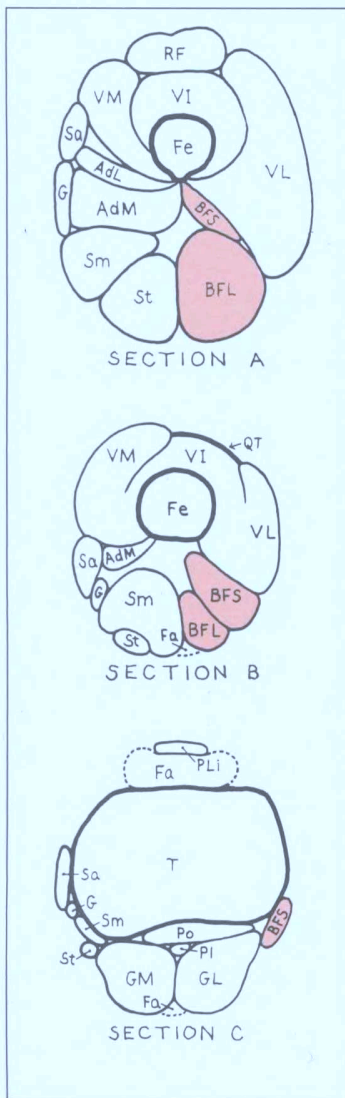
STRUCTURE The biceps femoris is comprised of two heads, a long and a short, and their single tendon of insertion. This **common tendon**, located on the outer back corner of the knee and shared by both heads, begins aponeurotically on the lower posterior surface of the belly of the long head, leaves the belly, and then tapers into a strong, wide, flat tendon. The tendon descends over the posterior portion of the short head. The fibers of the short head insert into the deep aspect of this tendon all the way down to the head of the fibula.

In the straight leg, the two heads generally produce a single elongated fusiform shape (barely separable from the semitendinosus, but very distinct from the vastus lateralis), and the tendon is not seen. The two heads may, however, be discernible in the straight leg. The fleshy muscular form of the short head eventu-

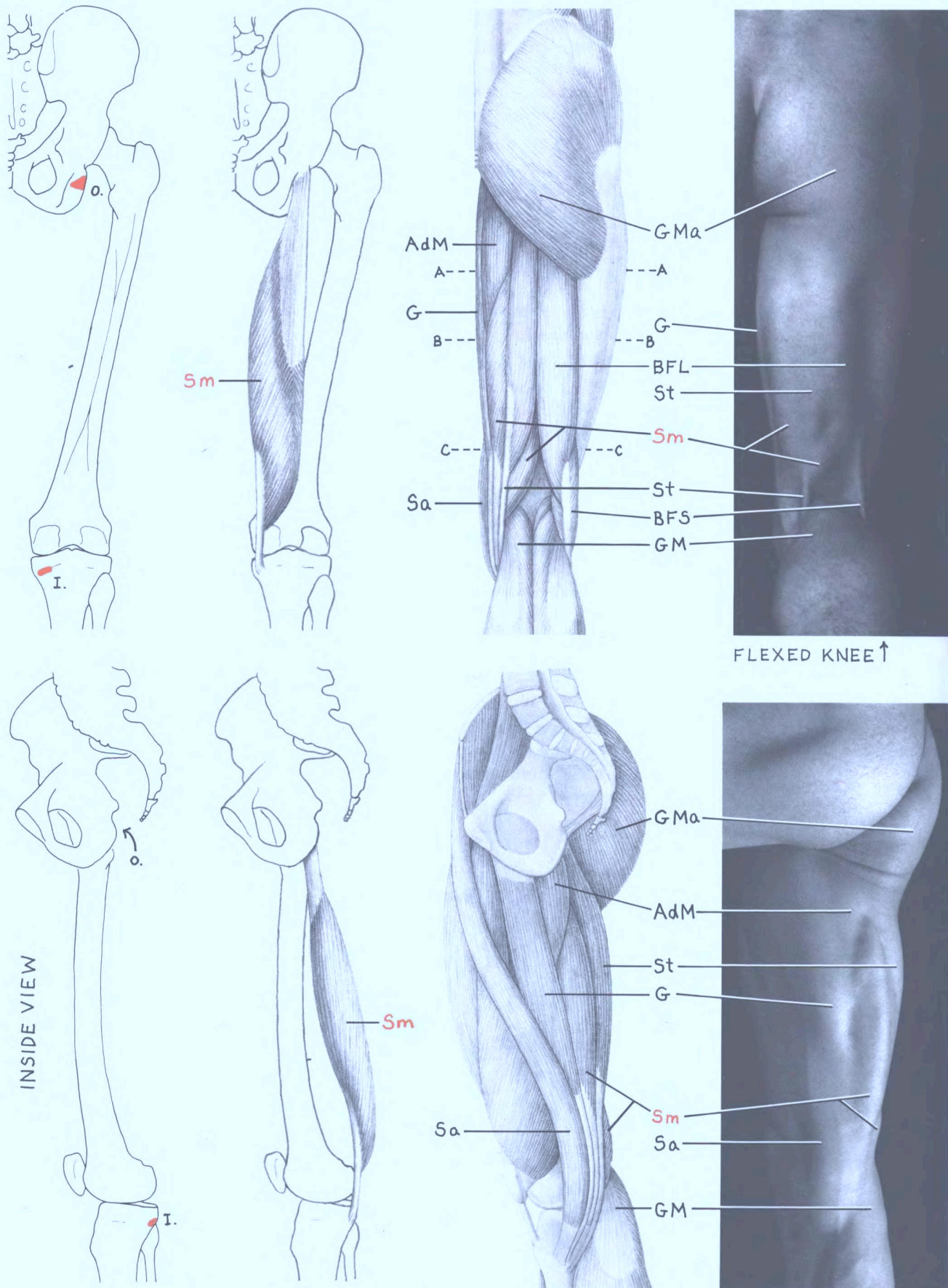
ally passes downward on the *outside* of the knee to the head of the fibula, sometimes appearing quite wide and bulging prominently. Its form may end a short distance above the head of the fibula.

In the extended knee, the medial (posterior) edge of the common tendon often produces a vertical furrow on the lateral side of the back of the knee, defining the lateral limit of the popliteal bulge.

The lower end of the belly of the long head ends approximately three-fourths of the way down the thigh. Its fibers continue inserting for a distance down the medial edge of the common tendon. When the biceps femoris contracts during flexion of the knee, the long head becomes shorter, wider, rounder, conspicuous, and *separate* from the form of the short head. The form of the long head, especially its lower end, now lies medial to the now prominent short head, whose posterior edge (and overlying tendon) has been raised into a ridge. The overlying tendon now curves around the short head's posterior surface, and the lower end of the long head appears to insert into the *medial side of the form of the short head*. The axes of the forms of the long and short heads are no longer in line with each other in the flexed knee—the long head is oblique, while the short head is vertical (seen from the back view). In this position, the lower half of the short head pulls away from the femur, and a depression forms between this portion of the short head and the vastus lateralis (seen in side view).



The Upper Leg Muscles • SEMIMEMBRANOSUS



AdM Adductor magnus BFL Biceps femoris—long head BFS Biceps femoris—short head Fa Fat
 Fe Femur G Gracilis GM Gastrocnemius—medial head GMa Gluteus maximus Sa Sartorius
 Sm Semimembranosus St Semitendinosus

Semimembranosus

ORIGIN Upper lateral facet of the ischial tuberosity of the pelvis (under and lateral to the origin of the long head of the biceps femoris).

INSERTION A horizontal groove on the posteromedial surface of the medial condyle of the tibia (not onto the shaft).

ACTION Flexes the lower leg at the knee joint and then medially rotates it; extends the thigh at the hip joint.

STRUCTURE The semimembranosus consists of a fleshy muscle belly with a tendon at each end. It begins superiorly as a wide “membranous” tendon that is curved side to side to form a longitudinal channel. The channel extends down into its fleshy muscle belly, and the belly of the semitendinosus lies in this gully. The semimembranosus ends in a strong, flattened tendon that arises from the medial side of its muscle belly. This tendon is located between the tendons of the semitendinosus and gracilis on the inner back corner of the knee, but is never visible on the surface. The muscle fibers of the fleshy belly extend downward to the level of the middle of the medial condyle of the femur, which brings these fleshy fibers in contact with the fleshy fibers of the medial head of the gastrocnemius.

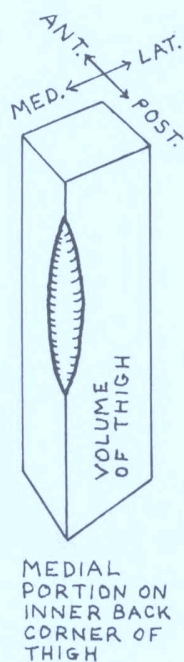
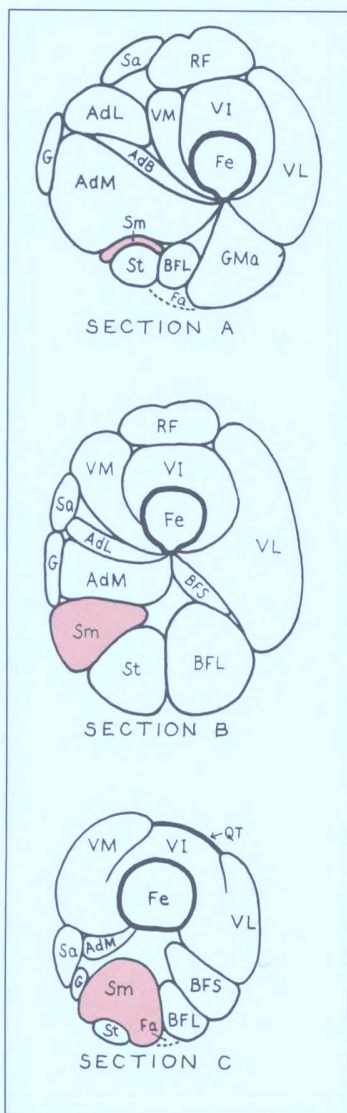
The muscle belly of the semimembranosus is partly superficial on either side of the semitendinosus—*medial* to it as an elongated form on almost the entire length of the inner back corner of the thigh and *lateral* to the lower portion of its belly and tendon. The lower lateral portion lies just above the back of the knee, where it fills most of the popliteal space and butts up against the biceps femoris. This portion can be thought of as a downward extension of the elongated form of the semitendinosus belly situated immediately superior to it; the combined

form lies just medial to the midline of the back of the thigh. The lower lateral portion bulges during full knee extension, although it is partially or completely covered by the popliteal fat pad. When the fat is thin, this portion of the semimembranosus contributes directly to the popliteal bulge that develops lateral to the furrow caused by the semitendinosus tendon (only in the extended knee).

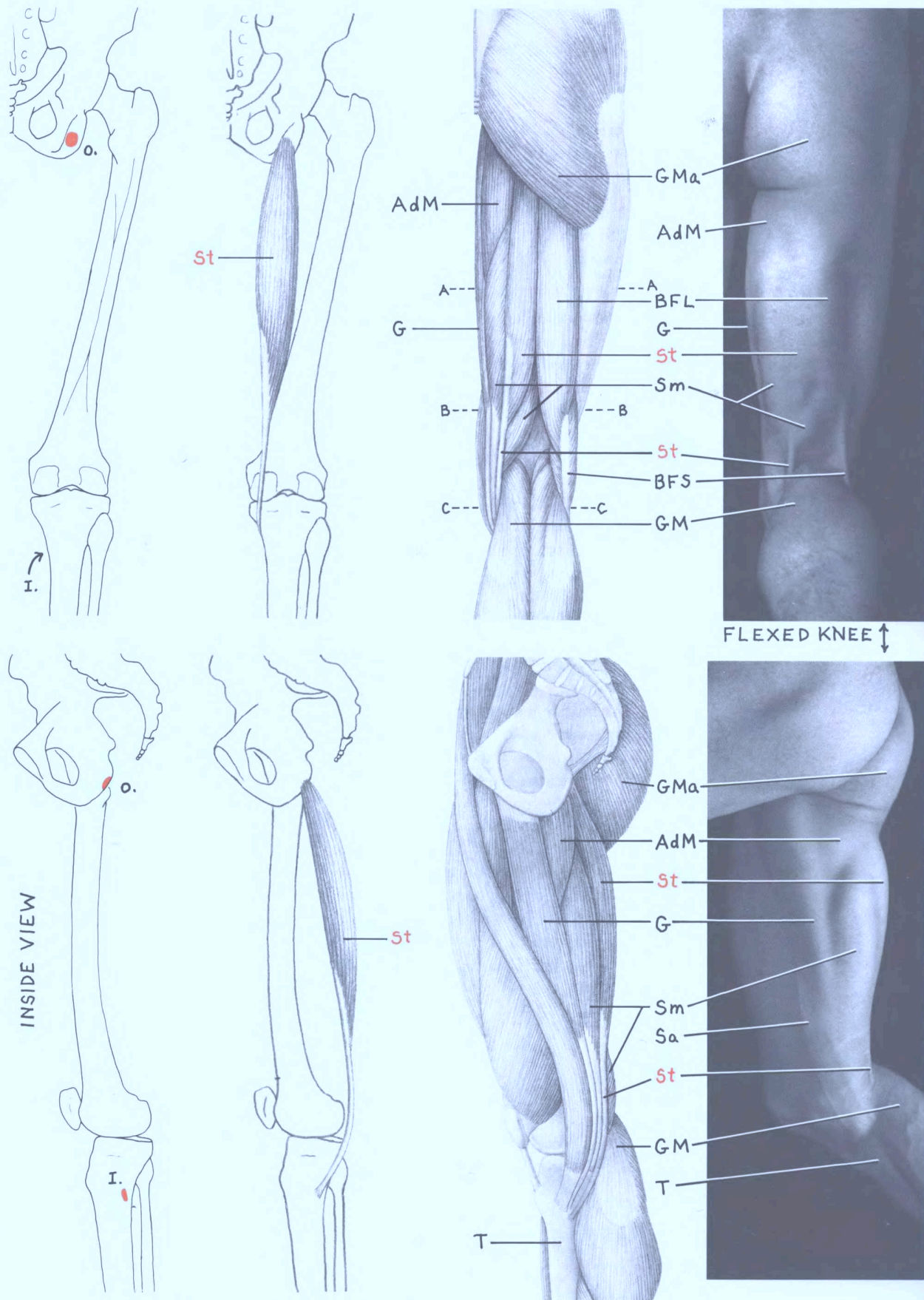
The medial portion of the semimembranosus does not extend all the way up to the gluteus maximus, but ends in a point where the semitendinosus and adductor magnus bellies meet. An oblique **tendinous intersection**, directed downward and medially and parallel to the medial edge of the adductor magnus, is located across the upper part of this medial form. It sometimes separates the portion of the semimembranosus above it into an independent form.

When the thigh is completely flexed at the hip joint and the knee is extended, the semimembranosus is stretched tight. It becomes thinner and the width of the medial portion of its belly forms a wide, depressed furrow between the bellies of the semitendinosus laterally and adductor magnus and gracilis medially.

As the knee joint is fully flexed, more of the belly of the semimembranosus is revealed on the back of the thigh as the semitendinosus belly shortens and slides upward. Much of the belly of the semimembranosus now lies against the belly of the biceps femoris on the lower two-thirds of the back of the thigh. The upper portion of the semitendinosus tendon forms a furrow in the now-exposed upper portion of the belly of the semimembranosus. At the back of the flexed knee, the semitendinosus tendon moves posteriorly away from the knee, pulling the skin with it. The lower end of the belly of the semimembranosus is then no longer seen on the surface.



The Upper Leg Muscles • SEMITENDINOSUS



AdM Adductor magnus BFL Biceps femoris—long head BFS Biceps femoris—short head Fa Fat
 Fe Femur G Gracilis GM Gastrocnemius—medial head GMa Gluteus maximus Sa Sartorius
 Sm Semimembranosus St Semitendinosus T Tibia

Semitendinosus

ORIGIN Ischial tuberosity of the pelvis (in common with the long head of the biceps femoris).

INSERTION Upper part of the medial surface of the shaft of the tibia, below the medial condyle, in common with the sartorius and gracilis.

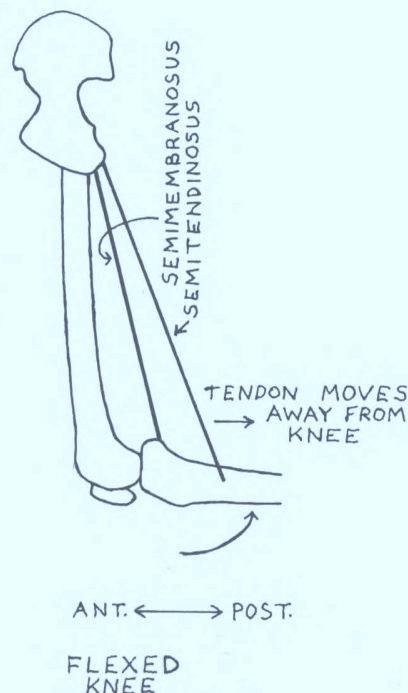

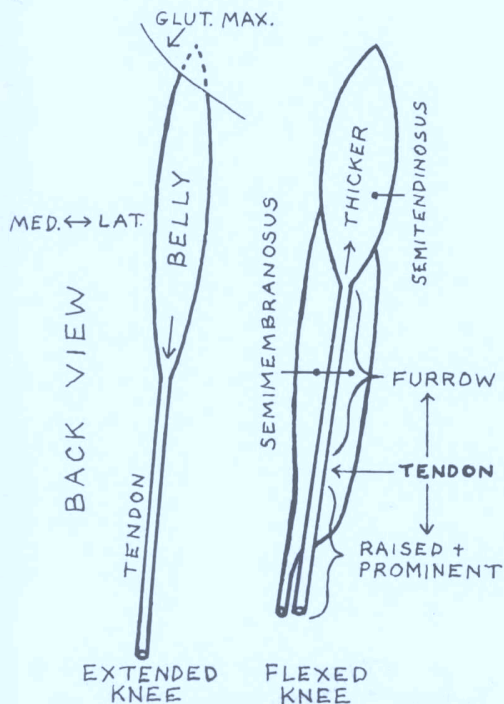
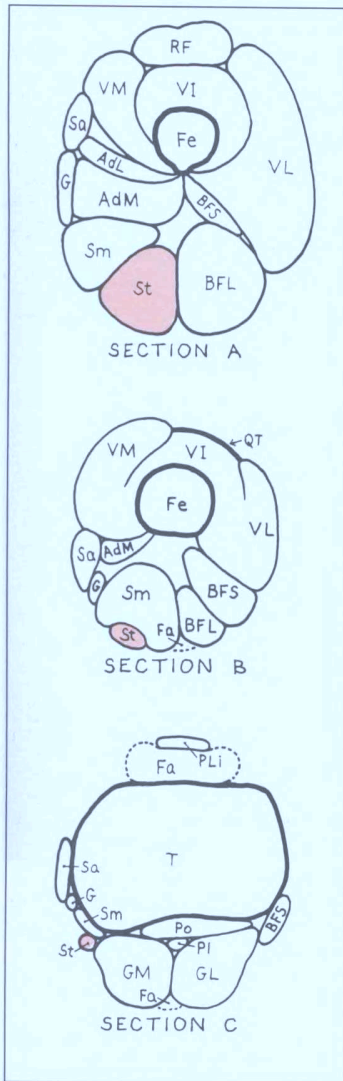
ACTION Flexes the lower leg and then medially rotates it; extends the thigh at the hip joint.

STRUCTURE The long, narrow, fleshy belly of the semitendinosus ends two-thirds of the way down the thigh at its tendon and sits in the shallow, longitudinal muscular groove formed in the semimembranosus muscle. It is located just medial to the midline of the back of the thigh. Its long, cordlike tendon of insertion begins on the *medial* side of its belly, passes down on the middle of the lower half of the belly of the semimembranosus, continues behind the medial condyles of the femur and tibia, and finally curves forward (lying against the medial head of the gastrocnemius) to reach its insertion. This tendon becomes very prominent during knee flexion as it moves away from the back of the upper leg (it also moves away from the semimembranosus). When the knee joint is extended, the tendon is pulled tight, producing

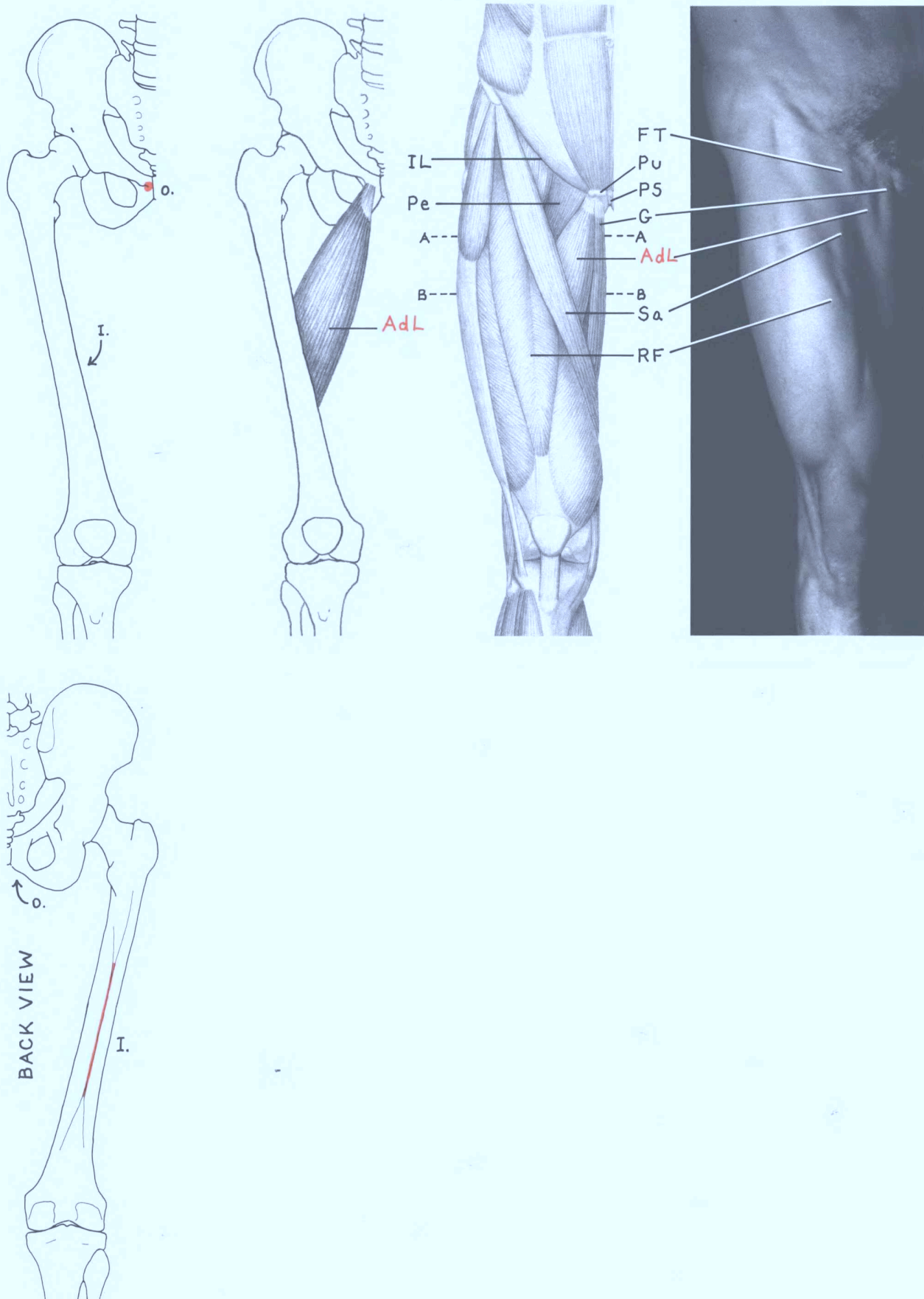
a narrow vertical furrow on the back of the knee, medial to the popliteal bulge (made up of the bulging popliteal fat and the underlying part of the semimembranosus). The furrow is more pronounced in the female.

When the knee is extended and the pelvis is flexed forward at the hip joint, stretching the hamstring muscles, the muscle belly of the semitendinosus and the lower lateral portion of the semimembranosus immediately below it together produce an elongated raised form down the back of the thigh just medial to the midline. When the knee is flexed, the inferior end of the belly of the semitendinosus rises considerably (exposing more of the belly of the semimembranosus). The upper portion of its long tendon of insertion then becomes a furrow, and the lower portion of the tendon becomes a very prominent raised ridge. In this position, the semitendinosus tendon on the medial side of the back of the knee projects further posteriorly than does the biceps femoris tendon on the lateral side of the back of the knee.

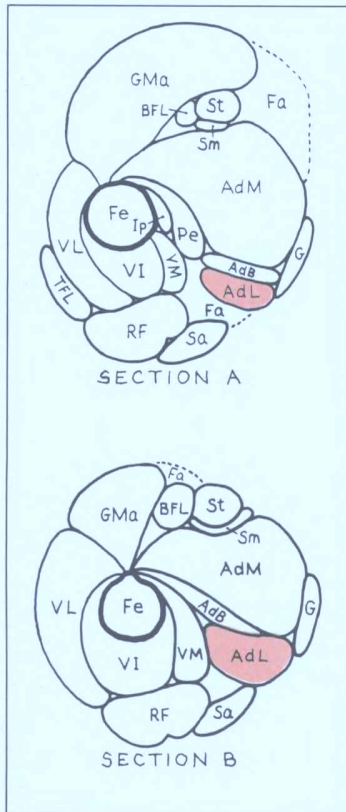
The superior end of the belly of the semitendinosus maintains its width as it passes under the lower edge of the gluteus maximus. At this point, it is in contact with the adductor magnus medially, not the semimembranosus.



The Upper Leg Muscles • ADDUCTOR LONGUS



AdB Adductor brevis AdL Adductor longus Fa Fat Fe Femur FT Femoral triangle fat G Gracilis
 IL Inguinal ligament Pe Pectineus PS Pubic symphysis Pu Pubis RF Rectus femoris Sa Sartorius
 VM Vastus medialis



Adductor Longus

ORIGIN Small round area on the outer surface of the anterior portion of the pubic bone of the pelvis, just below the pubic tubercle and just lateral to the pubic symphysis.

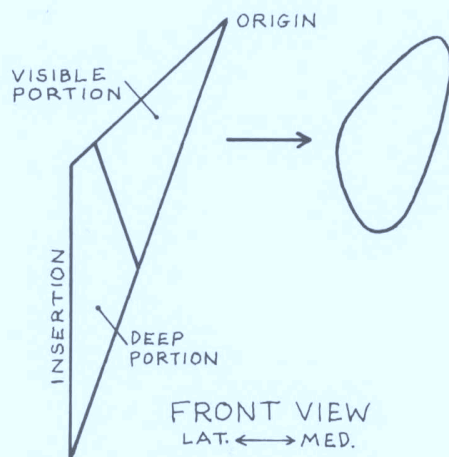
INSERTION A vertical line on the middle third of the back of the femur (on the medial lip of the linea aspera).

ACTION Adducts, flexes, and medially rotates the thigh.

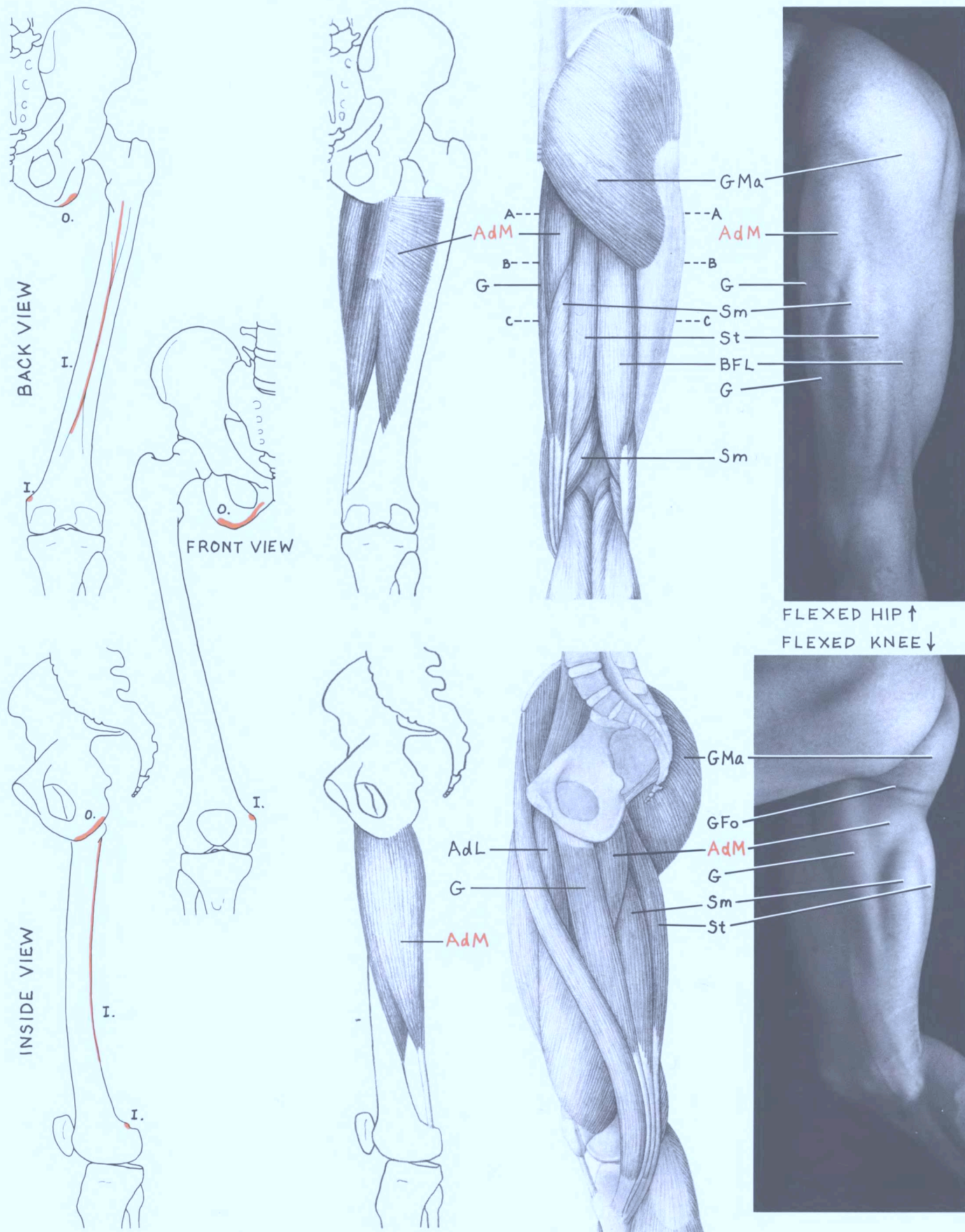
STRUCTURE The adductor longus is a long, triangular muscle, originating with both fleshy fibers and a strong tendon. The tendinous portion is often conspicuous in the groin when the legs are apart. Distally, the fleshy belly thins into a wide, flat tendon where it inserts into the femur between the vastus medialis and adductor

magnus. The adductor longus passes from the *front* of the pelvis to the *back* of the femur. It lies on the front of the mass of the adductor group, medial to the fat and neurovascular bundle of the femoral triangle. Inferiorly, it disappears under the sartorius. It is usually not defined on the surface since the adductor muscles usually appear as a single mass rather than as individual muscles. However, when it does show up, it is seen as an oval or triangular swelling on the medial portion of the front of the upper half of the thigh. This form narrows as it nears its origin on the pelvis.

When both tendons of origin of the adductor longus and gracilis are seen in the groin, the rounder (more cylindrical) adductor longus tendon is located anterior and lateral to the flat gracilis tendon.



The Upper Leg Muscles • ADDUCTOR MAGNUS



AdB Adductor brevis AdL Adductor longus AdM Adductor magnus BFL Biceps femoris—long head
 BFS Biceps femoris—short head Fa Fat Fe Femur G Gracilis GFo Gluteal fold
 GMa Gluteus maximus Pe Pectineus Sm Semimembranosus St Semitendinosus

Adductor Magnus

ORIGIN A line beginning on the lower lateral portion of the ischial tuberosity, extending along the inferior edge of the lateral surface of the ramus of the ischium, and then continuing forward along the posterior part of the ramus of the pubis (just above its inferior edge).

INSERTION A line down the middle of the back of the femur, beginning at the level of the lesser trochanter, leading to and passing down the linea aspera, and the adductor tubercle of the femur, just above the medial condyle.

ACTION Powerfully adducts the thigh. Gravity, however, usually adducts the thigh in the standing position, with the adductor magnus remaining relaxed. The oblique anterior fibers (upper or obturator portion) assist in flexion of the thigh, while the long, vertical, posterior portion (lower portion or ischial head) assists in extension of the thigh, especially if the hip joint has already been flexed (it functions like a hamstring hip joint extensor).

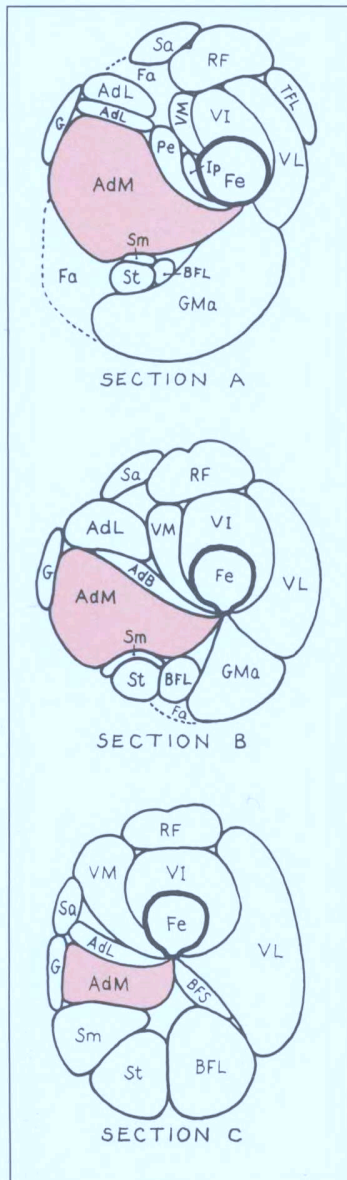
STRUCTURE The adductor magnus is a large powerful muscle located on the inside of the thigh. Its inferiorly pointed, somewhat conical form contributes substantially to the mass of the adductor group, which in turn blends with the hamstring group to create the large oblique form on the back of the thigh (directed upward, medially, and forward). The long internal edge of the adductor magnus passes between the masses of the hamstring and quadriceps groups

to attach to its long line of insertion on the back of the femur. Two-thirds of the way down the thigh, the inverted conical form of the adductor magnus differentiates into a rounded tendon (not visible), which inserts into the adductor tubercle on the top of the medial condyle of the femur.

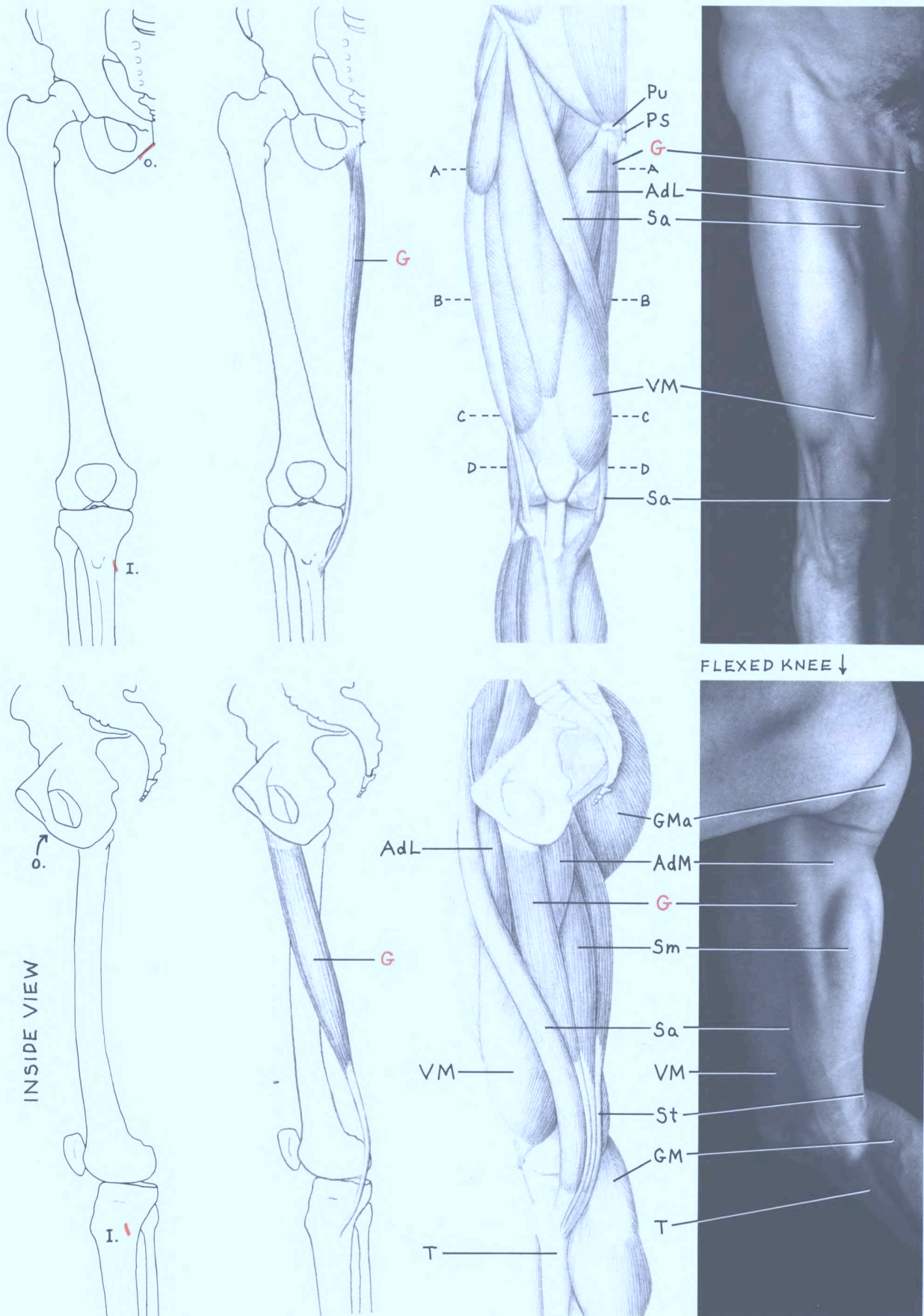
Only a small triangular area of the muscle is actually superficial. In low-fat individuals, its superficial part can be distinctly seen on the inner back corner of the upper end of the thigh when the pelvis is completely flexed forward at the hip joint and the knee remains extended. In this position the separation between the adductor magnus and the adjacent semitendinosus and semimembranosus is clearly seen. It is only occasionally distinguishable from the overlying gracilis. In this same position of full hip flexion, the adductor magnus is clearly seen emerging from under cover of the gluteus maximus. It disappears from view almost halfway down the thigh between the gracilis and semimembranosus.

When the thigh is first completely flexed at the hip joint and the knee is then extended as far as possible, the semimembranosus is stretched tight and creates a wide, depressed furrow; the soft form of the adductor magnus bulges medial to this furrow.

The small uppermost portion of the adductor magnus is called the **adductor minimus**. It is not visible on the surface.



The Upper Leg Muscles • GRACILIS



AdB Adductor brevis AdL Adductor longus AdM Adductor magnus Fe Femur G Gracilis
 GM Gastrocnemius—medial head GMa Gluteus maximus PS Pubic symphysis Pu Pubis
 Sa Sartorius Sm Semimembranosus St Semitendinosus T Tibia VM Vastus medialis

The Upper Leg Muscles • GRACILIS

Gracilis

ORIGIN Inferior edge of the midsection of the pubic arch between the pubic symphysis and ischial tuberosity.

INSERTION Superior part of the medial surface of the shaft of the tibia, below the medial condyle, in common with the insertions of the sartorius and semitendinosus.

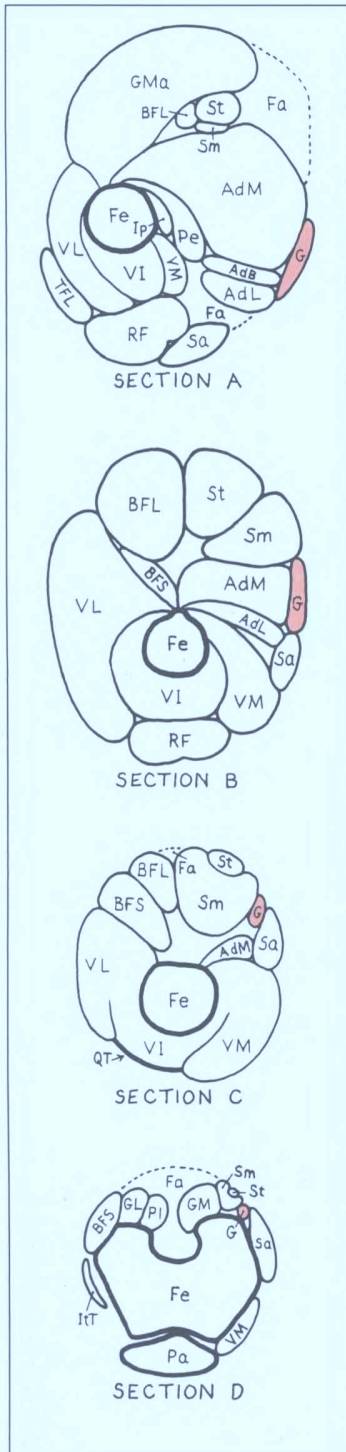
ACTION Adducts the thigh at the hip joint; flexes the lower leg at the knee joint and then assists in medial rotation of the lower leg.

STRUCTURE The gracilis is a thin, wide, bandlike muscle. Its flattened belly is wider above and tapers inferiorly. Sitting on the inside of the thigh, this muscle is the most superficial and medial of the adductors. Beginning from its thin, tendinous upper end (approximately two inches wide), its belly passes down the inner surface of the thigh and develops into a rounded tendon two-thirds of the way down the thigh. The lower tendon is never seen in the

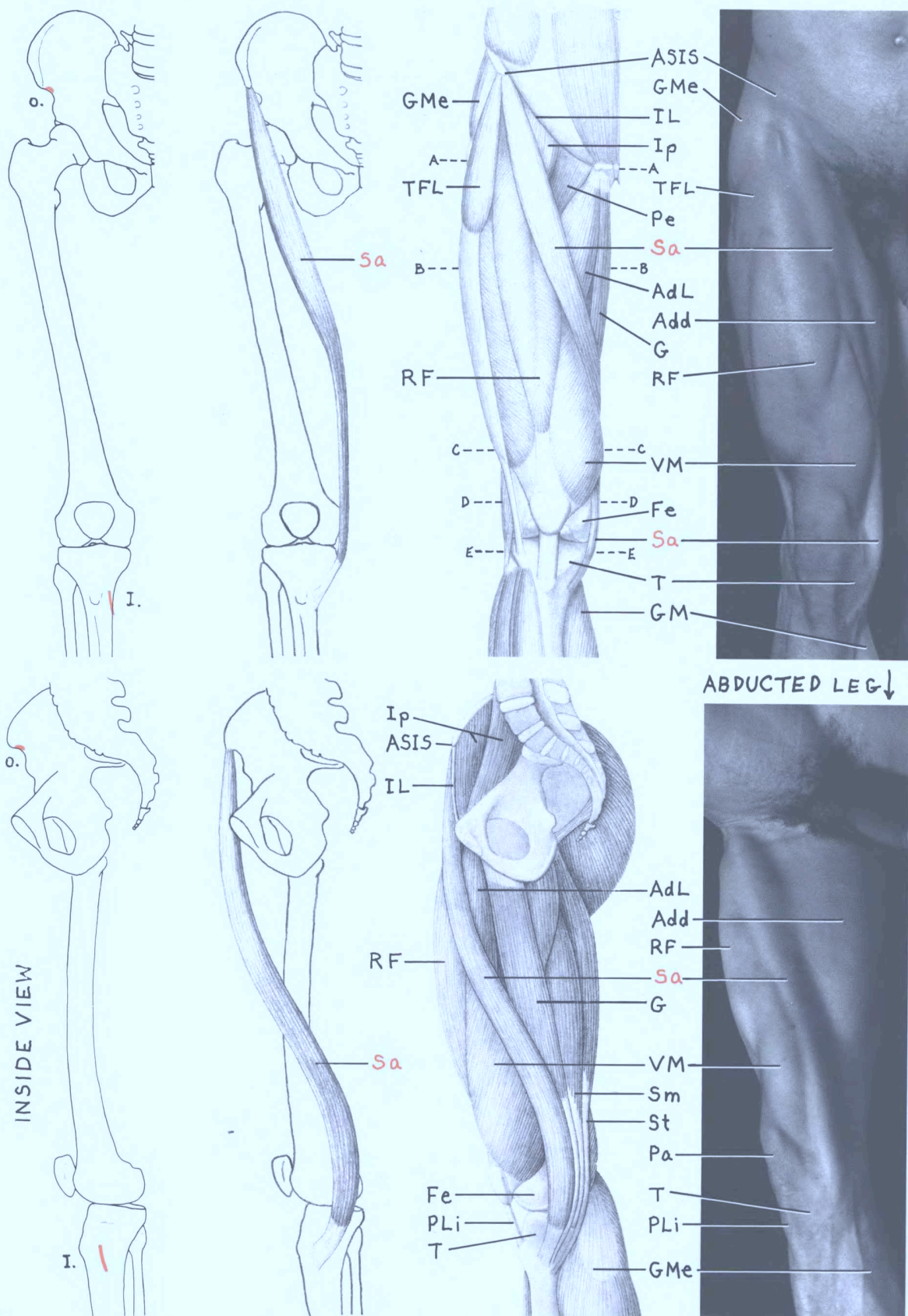
straight leg. Only rarely is it seen on the inside back corner of the knee when the lower leg is flexed at the knee and medially rotated. When visible in this position, the gracilis tendon is directed along the inside of the thigh toward the midline of the base of the pelvis, whereas the more prominent semitendinosus tendon is directed obliquely toward the ischial tuberosity of the pelvis and is situated more laterally. Both tendons are easily palpated in the flexed knee when the muscles are tensed.

Although the thin muscular form of the gracilis for the most part blends with the mass of the other adductor muscles, it can often be seen prominently at its tendinous origin at the pelvis when the legs are apart, just posterior and medial to the rounded tendon of origin of the adductor longus. The belly of the gracilis may occasionally become defined on the surface.

In the front view, the gracilis disappears behind the vastus medialis two-thirds of the way down the thigh.



The Upper Leg Muscles • SARTORIUS



Add Adductors AdL Adductor longus AdM Adductor magnus ASIS Anterior superior iliac spine
 Fa Fat Fe Femur G Gracilis GM Gastrocnemius—medial head GMe Gluteus medius
 IL Inguinal ligament Ip Iliopsoas Pa Patella Pe Pectineus PLi Patellar ligament
 RF Rectus femoris Sa Sartorius Sm Semimembranosus St Semitendinosus T Tibia
 TFL Tensor fascia lata VM Vastus medialis

The Upper Leg Muscles • SARTORIUS

Sartorius

ORIGIN Just below the tip of the anterior superior iliac spine ("front point of the pelvis"), in the upper half of the notch between the anterior superior and anterior inferior iliac spines.

INSERTION Superior part of the medial surface of the shaft of the tibia, below the medial condyle, in common with the insertions of the gracilis and semitendinosus.

ACTION Strongly flexes, weakly abducts, and laterally rotates the thigh at the hip joint; flexes the lower leg and then minimally rotates it medially. It is a powerful flexor of the thigh, even though it is narrow, because it lies some distance in front of the hip joint.

STRUCTURE The sartorius is a long, narrow, thick, ribbonlike muscle that spirals down the thigh. It begins on the front of the hip and ends on the inside of the knee region. It usually sits inconspicuously between the masses of the quadriceps and adductors when the leg is at rest. When the thigh is flexed and laterally rotated at the hip joint, and the knee is also extended, the sartorius becomes prominent as it lifts out of the valley between these bordering muscle masses. Its upper portion lies on the belly of the rectus femoris and is in contact laterally with the tensor fascia lata for a short distance below its origin. The very superior extremity of the sartorius tapers slightly before attaching to the pelvis.

From its origin on the front point of the pelvis, the sartorius passes downward and inward to the medial surface of the thigh. It then descends vertically, hooking behind the vastus medialis. The fleshy fibers end *just below the knee*

joint on the surface of the medial condyle of the tibia, and the muscle continues via its flat tendon to its insertion on the shaft of the tibia.

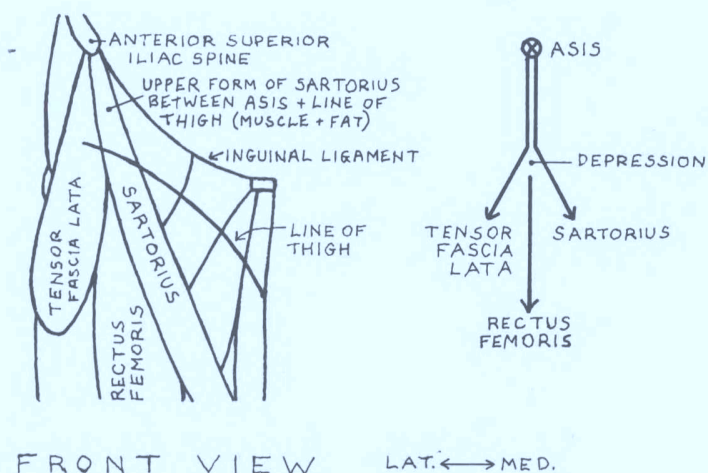
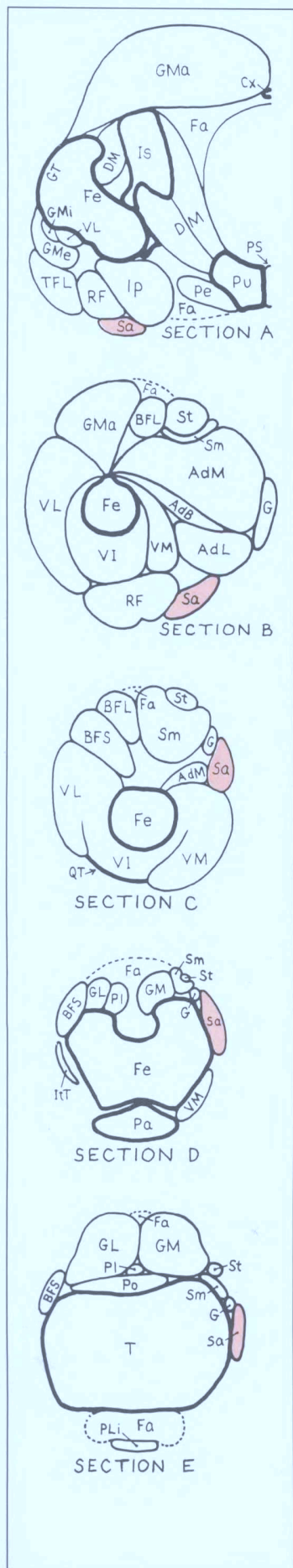
This tendon is not visible. The distal fleshy portion of the sartorius adds a muscular fullness to the inside of the knee. From the front view of the thigh, the sartorius is usually not visible as it hooks behind the vastus medialis, but reappears below it on the inside of the knee.

When looking at the inside (medial) view of the knee, the anterior edge of the sartorius is on or just posterior to the midline (from the front profile to the back profile of the knee).

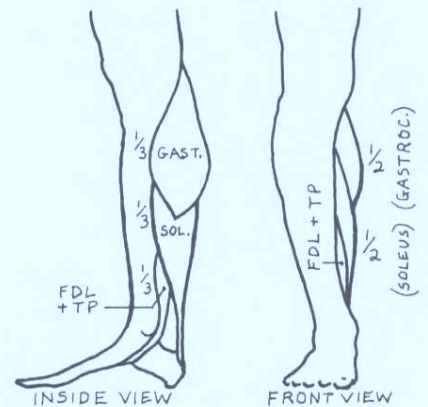
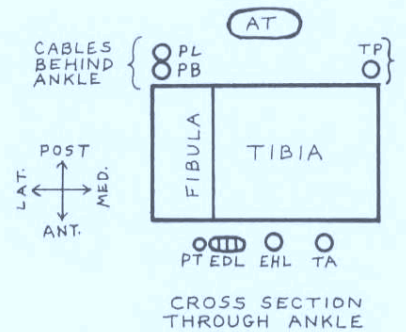
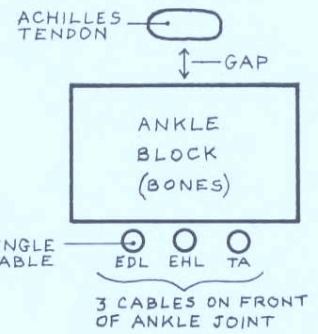
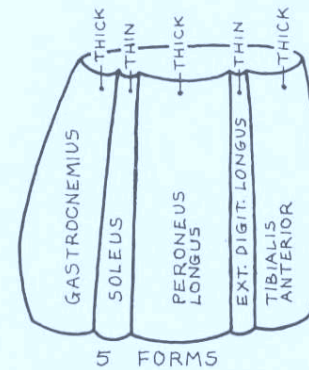
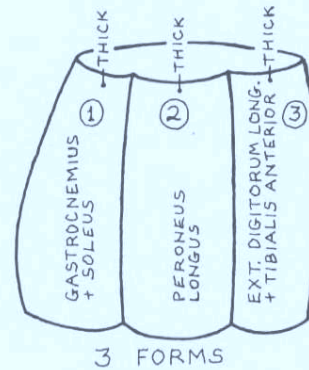
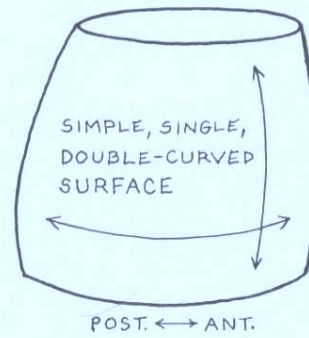
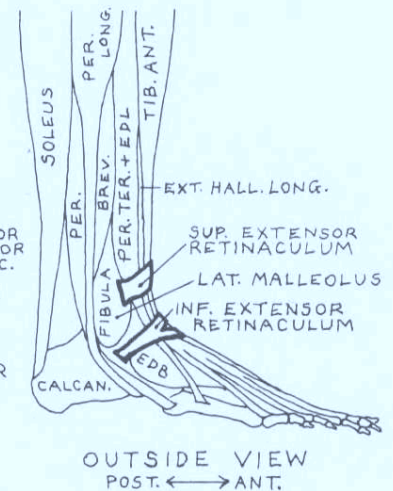
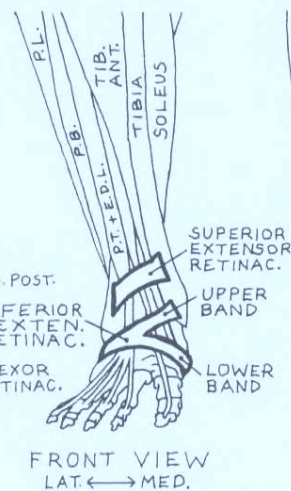
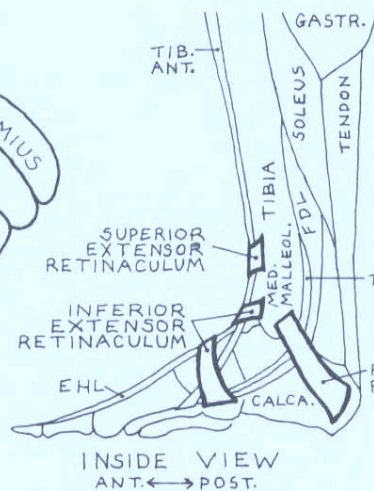
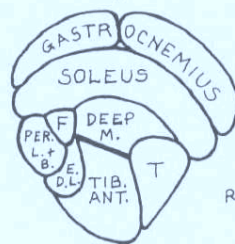
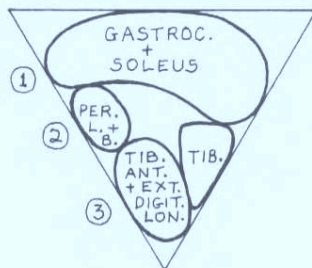
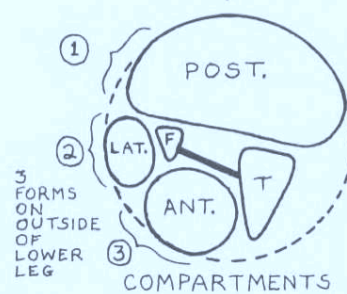
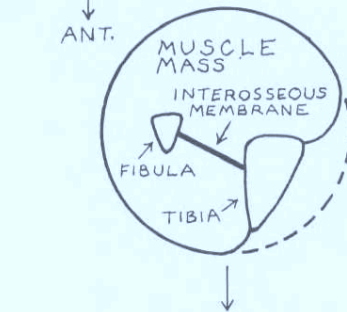
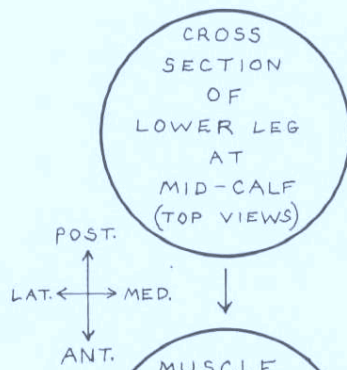
As the knee joint is flexed, the sartorius gets shorter and thicker. When the knee is completely flexed, it either merges with the bulging form of the adductor muscles or creates its own wide form on the medial surface of the thigh. In this position, a skin flexion fold develops on the back of the knee and cuts across the distal end of the sartorius. Also during knee flexion, the lower portion of the belly of the sartorius moves posteriorly and away from the distal end of the vastus medialis, and a slight depression forms between the two muscles on the inside surface of the knee region.

The upper end of the sartorius, located between the anterior superior iliac spine and the line of the thigh (genital fold), joins with the fat of this region to form a short, narrow, independent form in the extended hip joint.

The **pes anserinus** is a flattened aponeurosis made up of the combined inserting distal ends of the tendons of the sartorius, semitendinosus, and gracilis. It does not create any form on the surface, and the form of the tibia predominates.

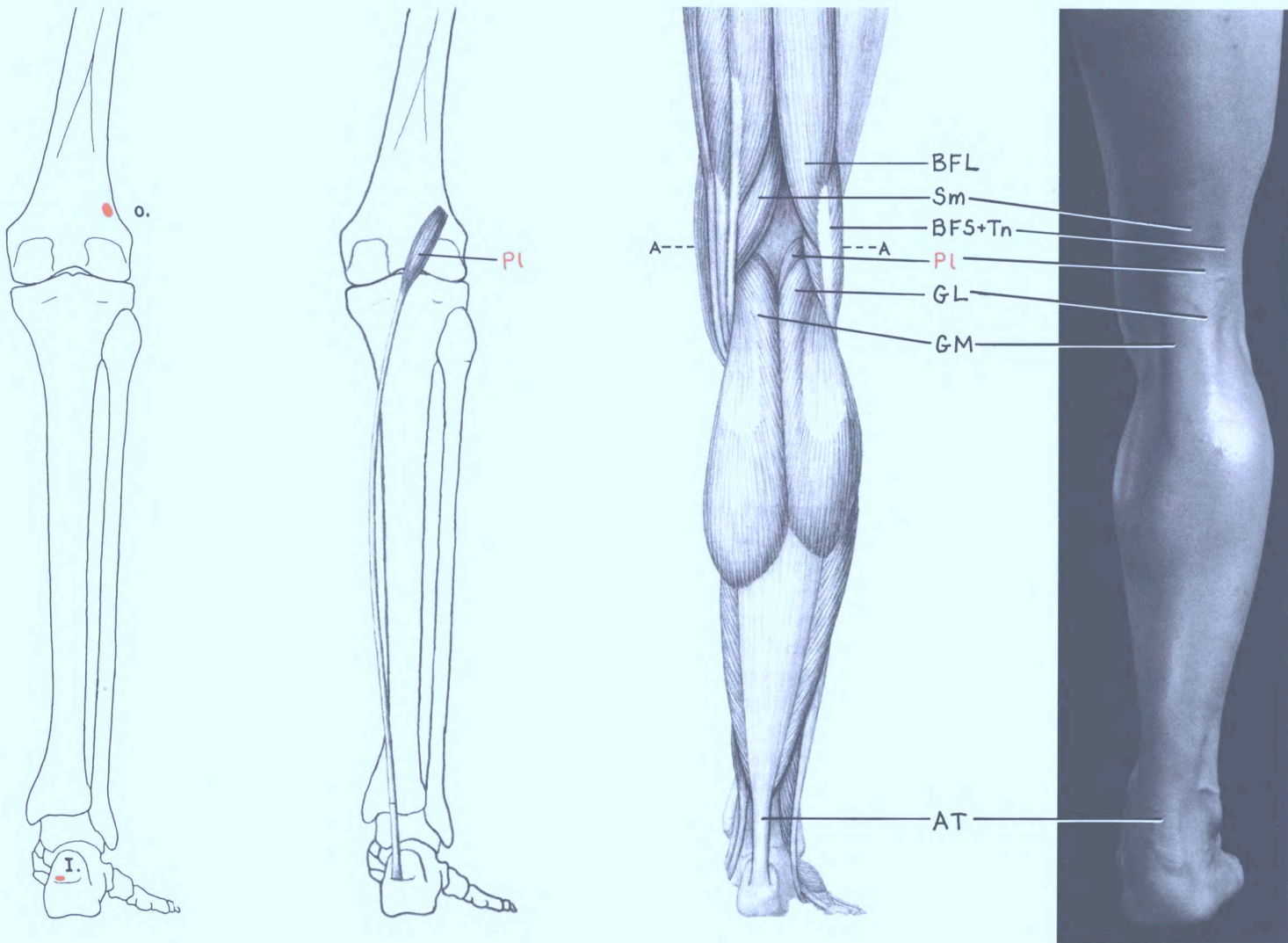


The Lower Leg Muscles



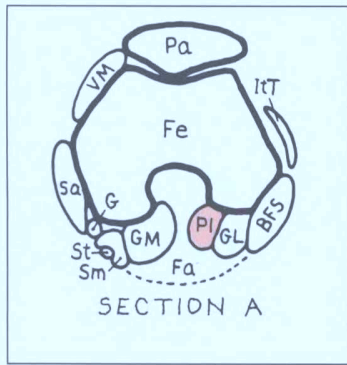
AT Achilles tendon EDB Extensor digitorum brevis EDL Extensor digitorum longus
 EHL Extensor hallucis longus F Fibula FDL Flexor digitorum longus PB Peroneus brevis
 PL Peroneus longus PT Peroneus tertius T Tibia TA Tibialis anterior TP Tibialis posterior

The Lower Leg Muscles • PLANTARIS



AT Achilles tendon BFL Biceps femoris—long head BFS Biceps femoris—short head Fa Fat
 Fe Femur GL Gastrocnemius—lateral head GM Gastrocnemius—medial head Pl Plantaris
 Sm Semimembranosus Tn Tendon

The Lower Leg Muscles • PLANTARIS



Plantaris

ORIGIN Lower end of the lateral supracondylar ridge of the femur, just above the lateral condyle (immediately above the origin of the lateral head of the gastrocnemius).

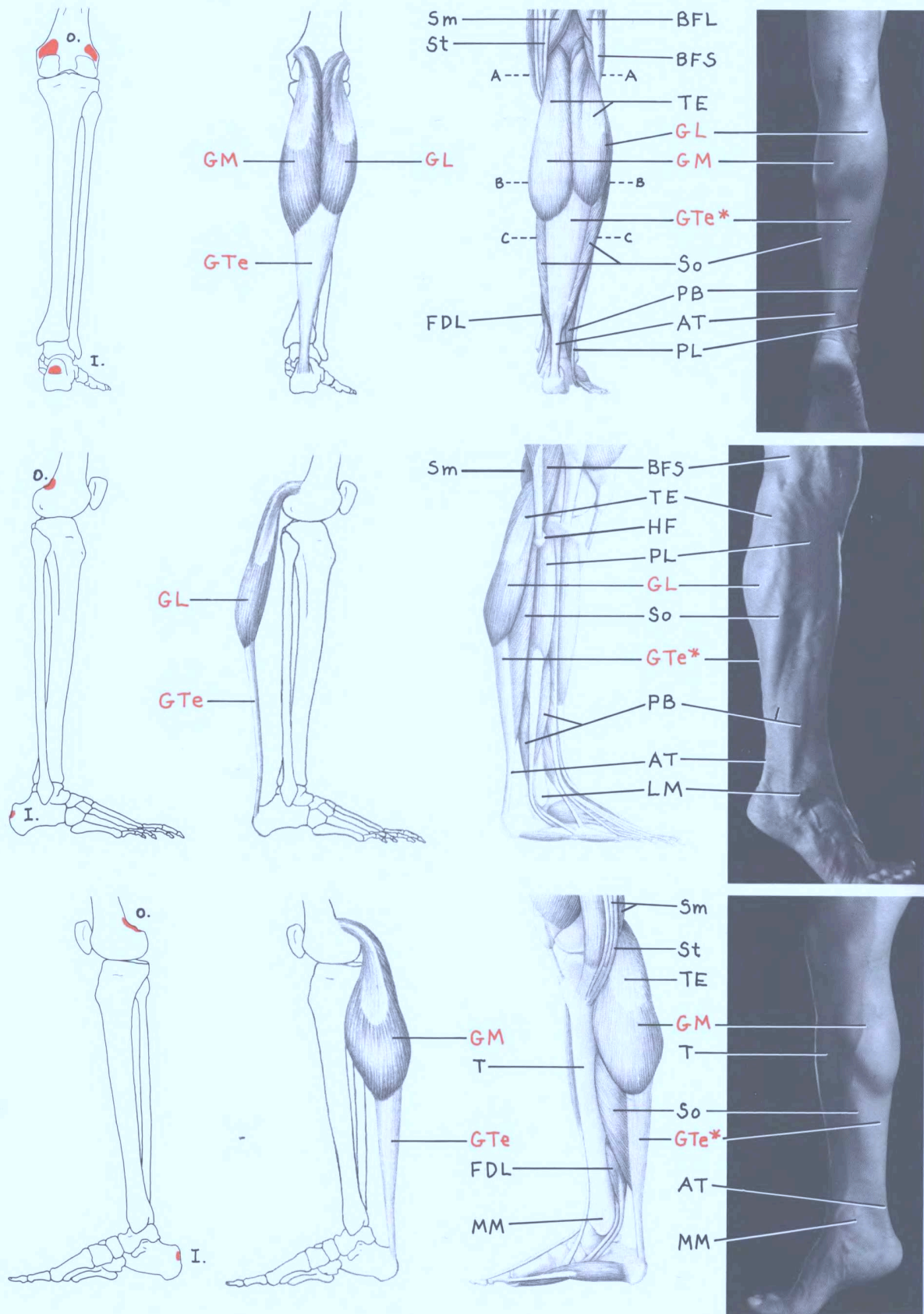
INSERTION Very small area on the posterior surface of the calcaneus, medial to the insertion of the Achilles tendon.

ACTION Weak action of flexion of the knee joint and plantar flexion of the foot.

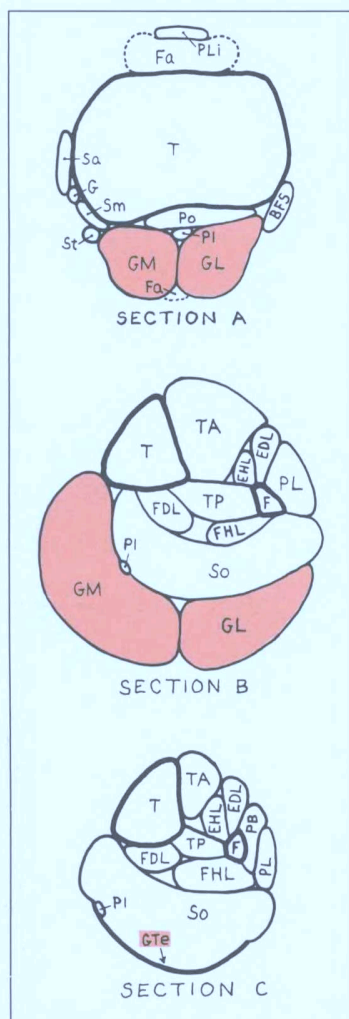
STRUCTURE The belly of the plantaris is slender, short, and fusiform; it contributes only

slightly to the muscular column of the lateral head of the gastrocnemius. Its extremely long, thin tendon at first lies deep between the soleus and gastrocnemius and then emerges on the medial side of the Achilles tendon. This tendon is too thin to be seen on the surface, but when the knee is partly flexed, the foot plantar flexed, and pressure is placed against the heel, part of the muscle belly of the plantaris may be seen on the back of the bent knee, just lateral to the midline.

The Lower Leg Muscles • GASTROCNEMIUS



AT Achilles tendon BFL Biceps femoris—long head BFS Biceps femoris—short head F Fibula
 Fa Fat FDL Flexor digitorum longus GL Gastrocnemius—lateral head
 GM Gastrocnemius—medial head GTe Gastrocnemius tendon HF Head of fibula
 LM Lateral malleolus MM Medial malleolus PB Peroneus brevis PL Peroneus longus PI Plantaris
 Po Popliteus Sm Semimembranosus So Soleus St Semitendinosus T Tibia
 TE Tendinous expansion * On soleus



Gastrocnemius

ORIGIN *Lateral head:* A facet on the lateral side of the lateral condyle of the femur and the posterior surface of the shaft immediately above this area. *Medial head:* A facet on the upper part of the medial condyle of the femur and the adjacent roughened area above it.

INSERTION Middle part of the posterior surface of the calcaneus, in common with the soleus (the insertion of the Achilles tendon).

ACTION *Foot free:* Plantar flexes the foot (points the foot). *Foot on ground:* Raises the heel, which lifts the body. The gastrocnemius may assist minimally in flexing the knee joint. It will *not* plantar flex the foot when the knee is completely flexed (because it is then actively insufficient).

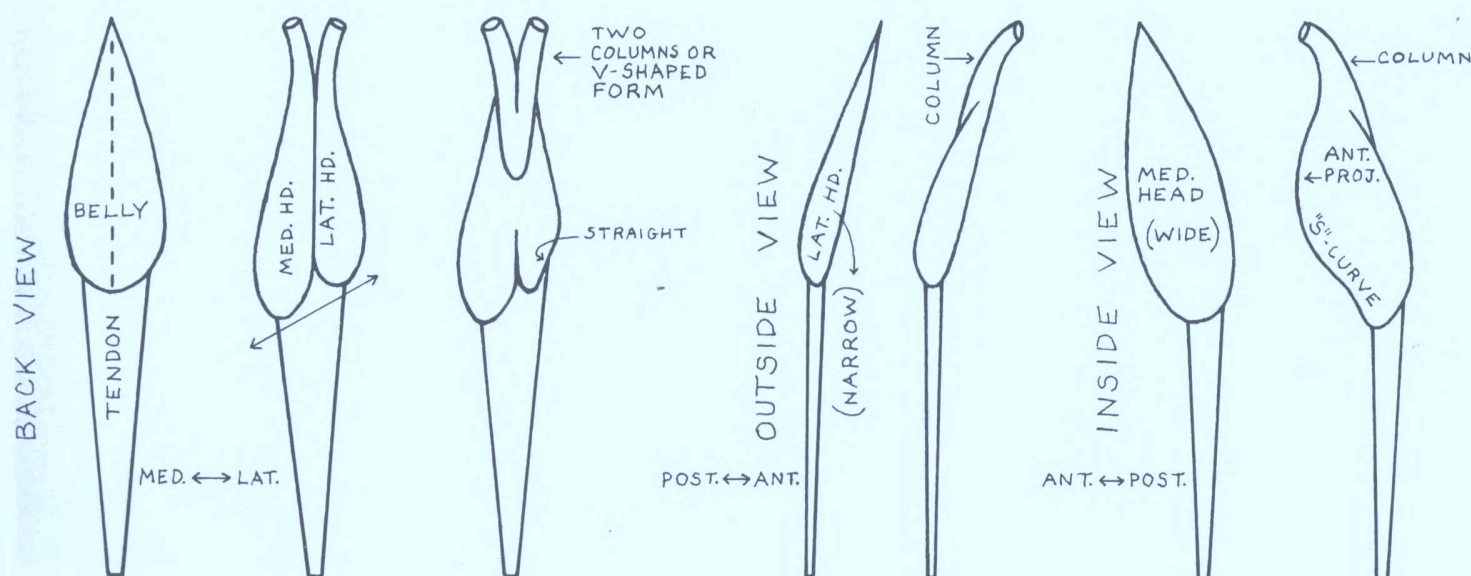
STRUCTURE The gastrocnemius is made up of a lateral head, a medial head, and their single tendon of insertion. The medial head is larger, descends lower, and wraps around the leg more toward the front than does the lateral head. The lower lateral edge of the lateral head may be an oblique straight line, rather than a rounded teardrop. The muscular heads end at, or slightly above, the middle of the leg, where they attach to their tendon. The tendon is wide and thin at its upper end and becomes narrower and thicker as it descends. It fuses with the tendon of the soleus lying immediately deep to it, forming the *Achilles tendon* (see Soleus).

From its origin, each head begins as a thick,

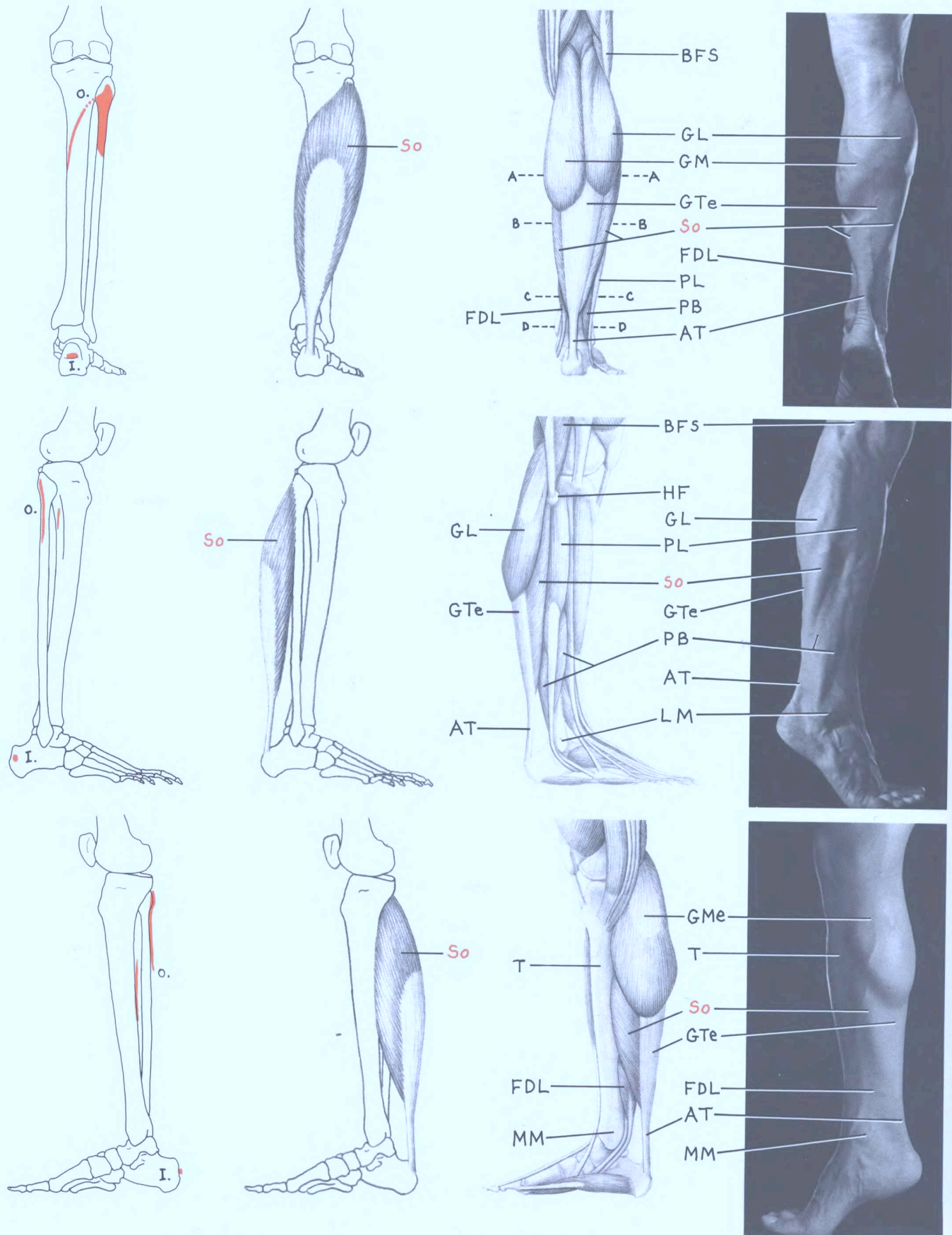
rounded, muscular column, separated from its fellow at the back of the knee. They soon come together, with a cleft between them that usually disappears at the middle of the belly. When the muscle is tensed, the columns separate from the rest of the head. Together they form a raised, thick, fleshy V on the back of the calf. The medial column is more vertical, the lateral more oblique and sometimes larger.

The separation of the muscular column from the rest of the head is caused by an aponeurotic sheet of tendon that begins at the origin of each head at the femur and expands downward onto the posterior surface of the upper portion of each head. This nonelastic tendinous sheet does not cover the column, and when the gastrocnemius contracts, it prevents the fleshy muscle mass immediately deep to it from expanding, but allows the exposed muscular column to bulge. The area of muscle restricted by the aponeurosis appears flat and planar in the contracted muscle. A sharp furrow may separate the column from the flat, tendon-covered area.

From the side view (medial or lateral), the posterior profile of the gastrocnemius is seen as a convex double curve—the muscular columns bulging above, the remainder of the heads below. In front view, the inside profile of the medial head is directed toward the center of the patella. From the inside view, the lower edge of the medial head ranges from a simple downward curve or a straight line to an S curve.



The Lower Leg Muscles • SOLEUS



AT Achilles tendon BFS Biceps femoris—short head F Fibula Fa Fat FDL Flexor digitorum longus
 FHL Flexor hallucis longus GL Gastrocnemius—lateral head GM Gastrocnemius—medial head
 GTe Gastrocnemius tendon on soleus HF Head of fibula LM Lateral malleolus MM Medial malleolus
 PB Peroneus brevis PL Peroneus longus PI Plantaris So Soleus T Tibia

Soleus

ORIGIN Posterior surfaces of the head and upper third of the shaft of the fibula; from a tendinous arch connecting the head of the fibula to the tibia; and from the raised *soleal line* on the back of the tibia. The tendinous arch is continuous with the soleal line.

INSERTION Middle part of the posterior surface of the calcaneus, in common with the gastrocnemius (the insertion of the Achilles tendon).

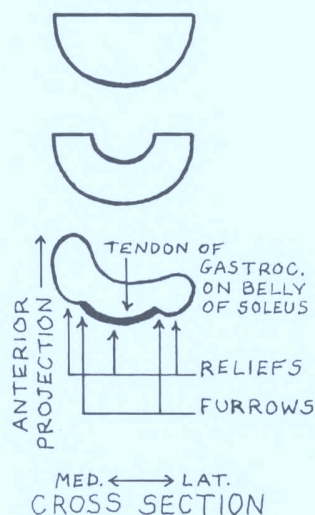
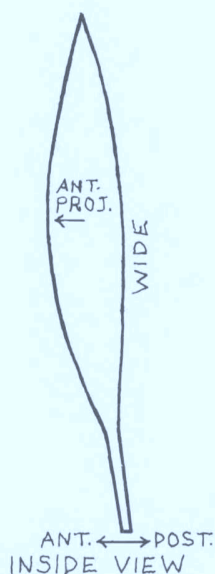
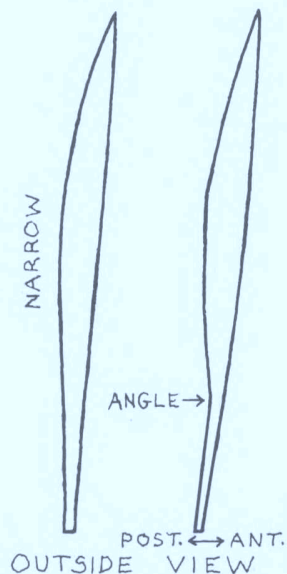
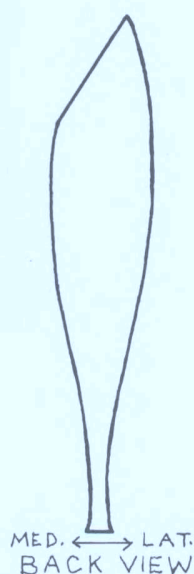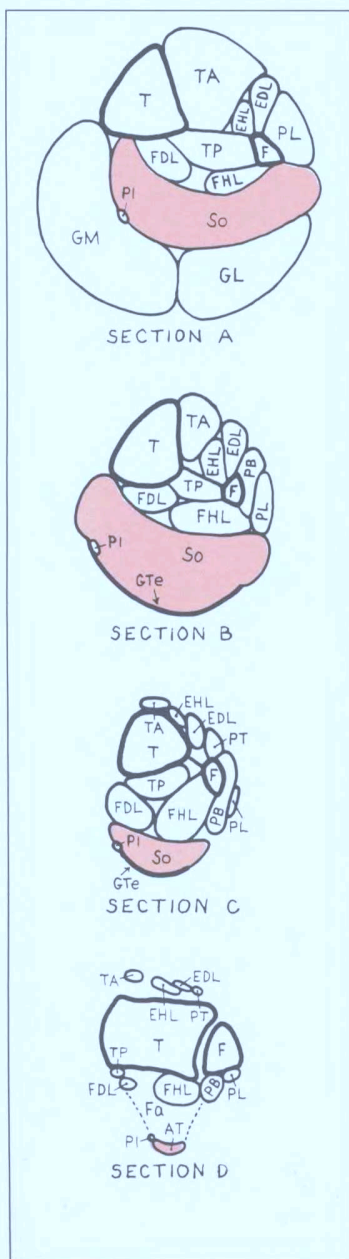
ACTION *Foot free*: Plantar flexes the foot (points the foot). *Foot on the ground*: Raises the heel, which lifts the body, and by continuous contraction, prevents the body from falling forward in the standing position.

STRUCTURE The soleus is a thick muscle located on the back of the lower leg; it joins the gastrocnemius to form the calf muscle group. It is thickest at its middle, where its flattened form curves around the deep flexor muscles of the foot and toes. The medial side of the belly projects more anteriorly (on the inside of the lower leg) than does the lateral side. Its upper portion is covered by the heads of the gastrocnemius.

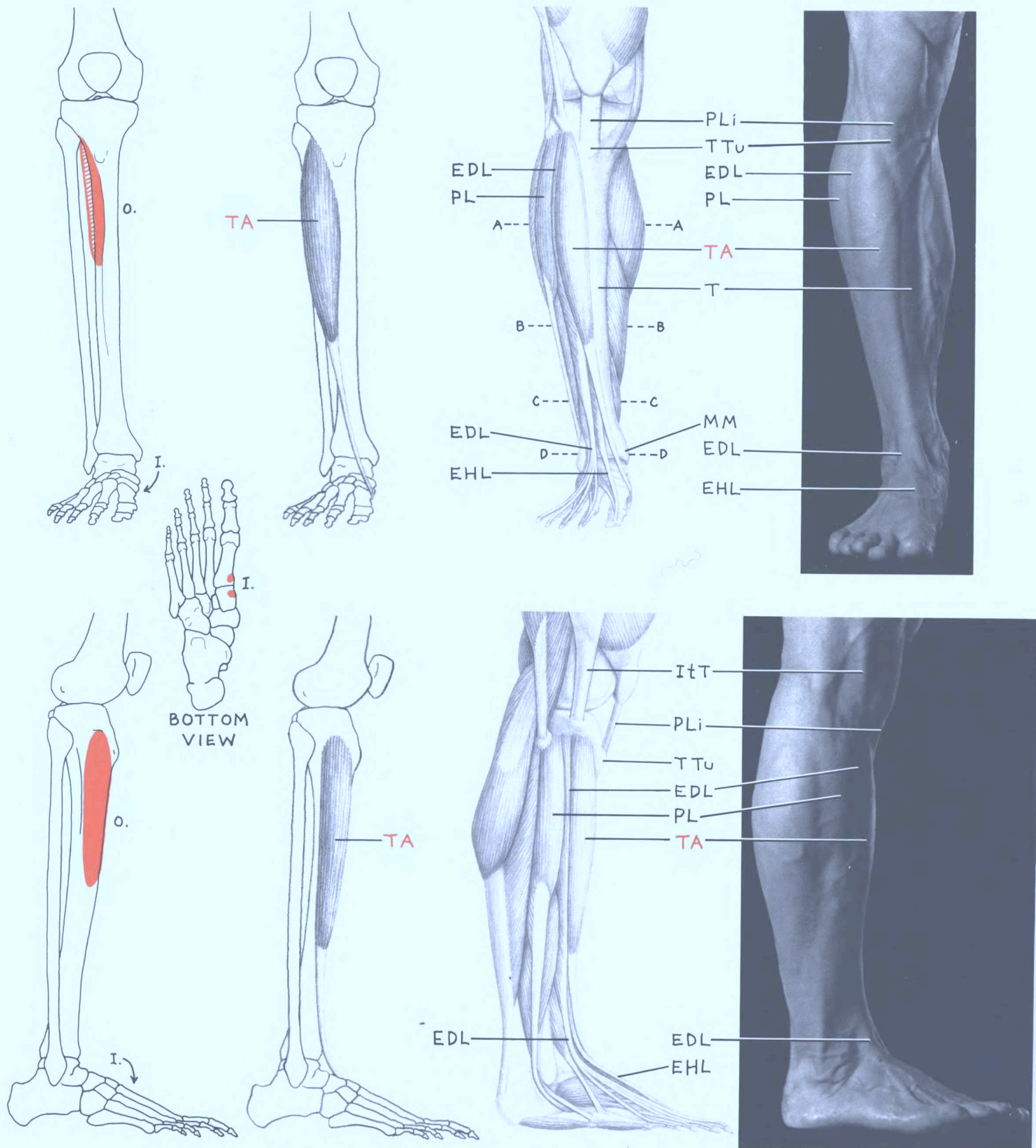
The muscle mass of the soleus tapers inferiorly and descends quite low, reaching a level just above the ankles. Its tendon, which continues on to its insertion on the heel, begins quite high on the posterior surface of the belly. It soon fuses with the overlying gastrocnemius tendon, and this combined tendon from mid-leg

downward is called the **Achilles tendon** (tendo calcaneus). This flattened tendon is narrowest (about three-fourths of an inch) and most prominent (most defined) at the level of the lateral malleolus. It widens slightly before it inserts. There is a fat-filled interval between the Achilles tendon and the back of the ankle bones. The medial and lateral edges of the combined tendons of the soleus and gastrocnemius, lying on the belly of the soleus, may compress the soleus and create two vertical furrows when the calf muscles are contracted. The form of the soleus is then divided into three vertical muscular columns: two narrow columns on either side of the edges of the tendon and a wide, raised relief up the middle of the muscle between the edges.

In side view, the back profile of the muscular belly of the soleus is either straight or only slightly convex. It meets the Achilles tendon at a slight angle, and below this angle the profile appears as a straight line when the calf is tensed or as a subtle concave line when relaxed (usually with the foot partly plantar flexed). After the tendon inserts, the bony calcaneus of the heel bulges posteriorly, and a second bulge below the calcaneus is created by the fat pad under the heel. In the front or rear view, the soleus often forms the profile on the outer side of the upper half of the lower leg (the peroneus brevis forms the profile on the lower half). The medial side of the belly can be seen on the middle third of the lower leg from the front view.



The Lower Leg Muscles • TIBIALIS ANTERIOR



EDL Extensor digitorum longus EHL Extensor hallucis longus F Fibula ItT Iliotibial tract
 MM Medial malleolus PL Peroneus longus PLi Patellar ligament T Tibia TA Tibialis anterior
 TP Tibialis posterior TTu Tibial tuberosity

The Lower Leg Muscles • TIBIALIS ANTERIOR

Tibialis Anterior

ORIGIN Lateral condyle of the tibia, lateral surface of the upper half of the shaft of the tibia, adjacent interosseous membrane, and the intermuscular septum between this muscle and the extensor digitorum longus.

INSERTION The bottom of the medial arch of the foot, midway from the front to the back of the foot; specifically, into the medial and bottom surfaces of the medial cuneiform bone and into the base of the first metatarsal bone.

ACTION Dorsiflexes and inverts the foot. During walking, it controls the descent of the foot after the heel strikes the ground.

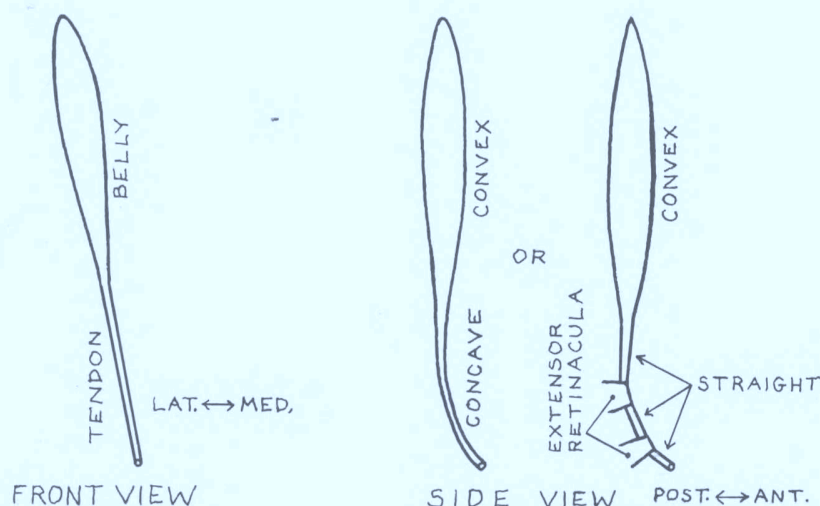
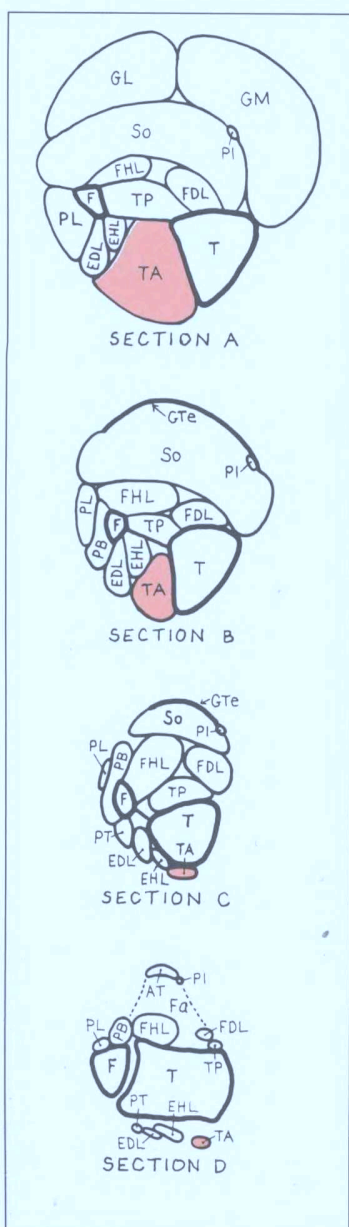
STRUCTURE Thick and fleshy above, the tibialis anterior tapers into its long, prominent tendon two-thirds of the way down the lower leg. The muscle belly is the first form lateral to the tibial tuberosity and anterior edge (the shin) of the tibia. The sharp edge of the shin is *not* covered by this muscle belly. In side view, the muscle belly bulges forward, anterior to the shin, to form the front profile of the top half of the lower leg. It runs down the outside of the shaft of the tibia. Its tendon then crosses diagonally (medially) in front of the ankle joint toward its insertion into the medial arch of the foot. The tibialis anterior therefore subtly spirals down the lower leg, passing from the outside of the knee to the inside of the foot.

The lateral fibers of the upper portion of the belly thin out and partially cover the upper end of the extensor digitorum longus, obscuring the separation between the muscles and creating one wide form (see cross section). The extreme upper ends of these two muscles can at times be seen separately during strong dorsiflexion and

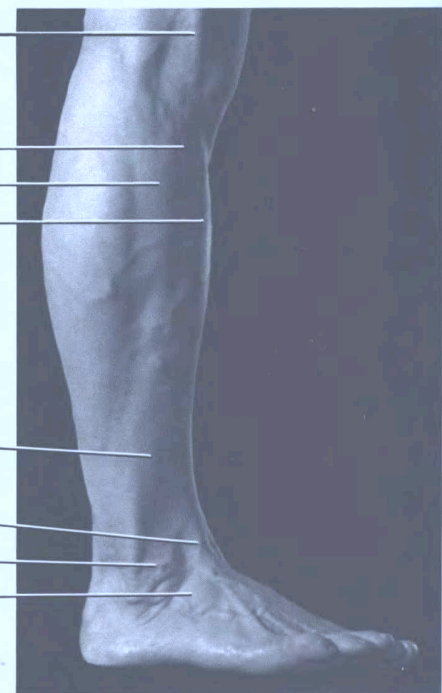
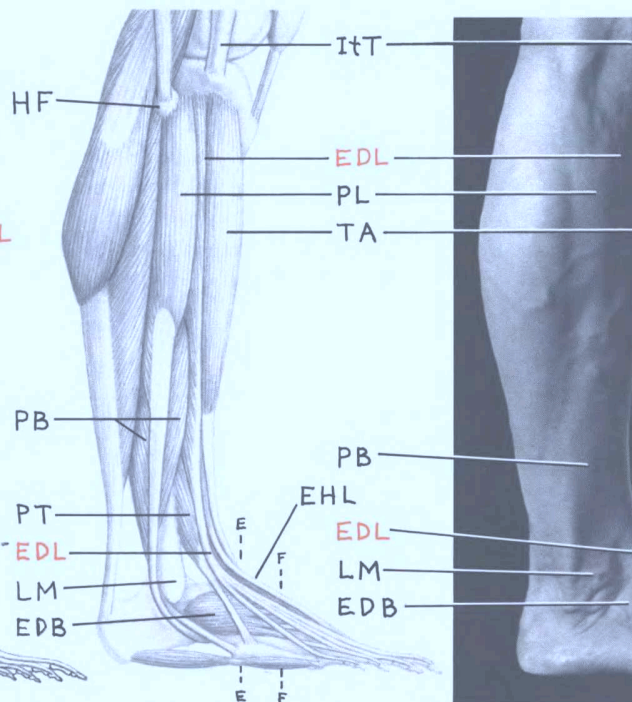
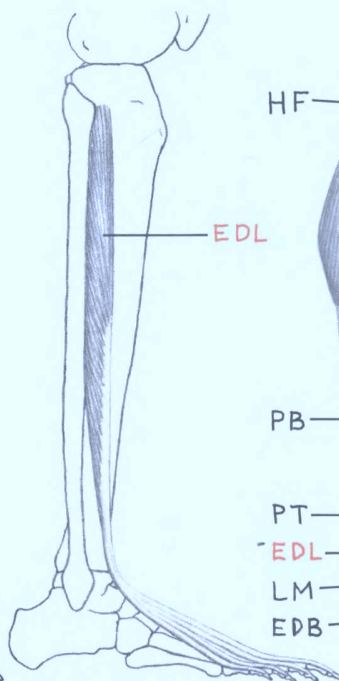
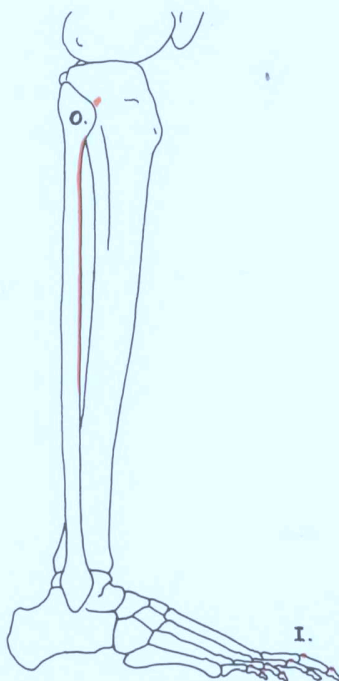
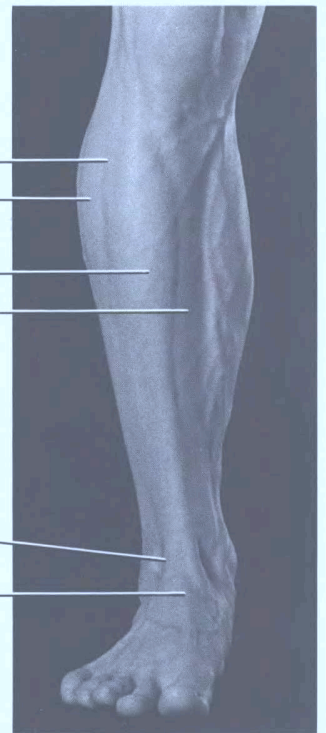
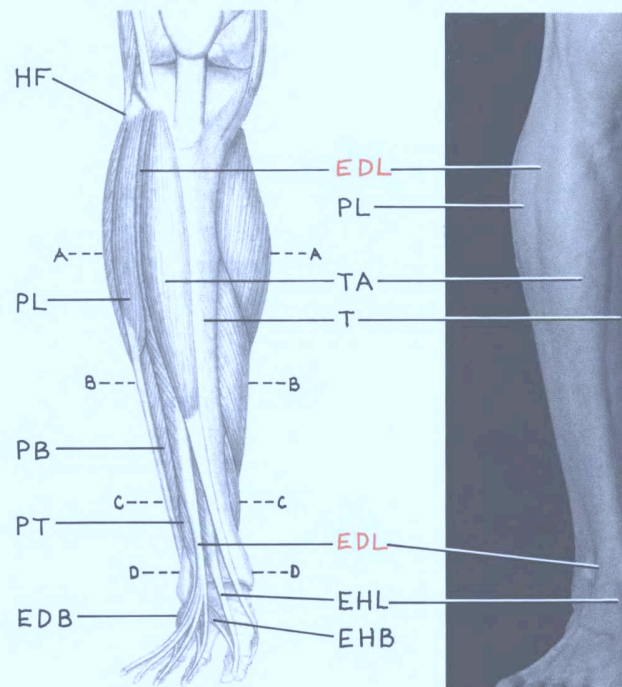
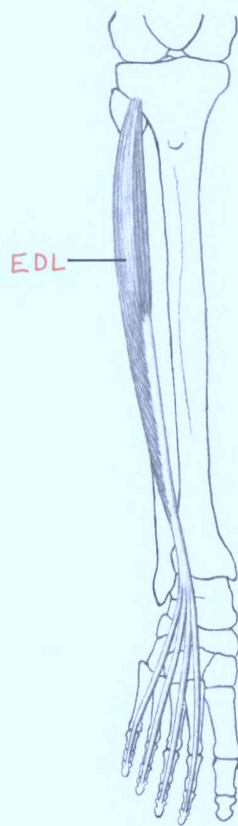
eversion of the foot (as they bulge). During full plantar flexion of the foot, the very top ends of these muscles form a depression just below the lateral condyle of the tibia (because they have been stretched out), while the superior end of the peroneus longus bulges (because it has been shortened, thus becoming thicker).

The muscle fibers of the lower end of the tibialis anterior belly continue inserting for a considerable distance onto the deep aspect of its tendon. This produces the elongated taper at the inferior end of the belly. The tendon is wide and flattened where it begins at the lower end of the belly; it gradually rounds off and becomes quite prominent as it descends. On the front of the ankle, the tendon is located medial to the midline. It widens again just before it inserts. At the ankle joint, it is held in place by the inferior extensor retinaculum, which may occasionally be seen stretched between this tendon and the medial malleolus of the tibia when the foot is inverted.

With the foot and big toe flat on the floor, the tendon of the tibialis anterior is the most anterior tendon at the front of the ankle. It spans the gap between the lower end of the tibia and the foot bones (over the ankle joint). The entire tendon can occasionally form a concave curve along the front profile of the lower half of the lower leg (seen in side view). This concavity is the inferior continuation of the convex profile of the belly above. Careful examination of the lower half of the lower leg will show that the front profile is often made up of a series of straight lines. This is caused by the constriction of the tendon at several points by bands of the extensor retinacula, separating the tendon into short, straight portions.



The Lower Leg Muscles • EXTENSOR DIGITORUM LONGUS



EDB Extensor digitorum brevis EDL Extensor digitorum longus EHB Extensor hallucis brevis
 EHL Extensor hallucis longus F Fibula HF Head of fibula ICu Intermediate cuneiform
 ItT Iliotibial tract LCu Lateral cuneiform LM Lateral malleolus M Metatarsal
 PB Peroneus brevis PL Peroneus longus PT Peroneus tertius T Tibia TA Tibialis anterior

Extensor Digitorum Longus

ORIGIN The outer side of the lateral condyle of the tibia; the upper three-fourths of the anterior surface (or front edge) of the fibula; the adjacent interosseous membrane; and the intermuscular septa between this muscle and the tibialis anterior on one side and the peroneal muscles on the other side.

INSERTION Top surfaces of the middle and distal phalanges of toes two through five (to the lateral four toes; the extensor digitorum longus does *not* go to the big toe).


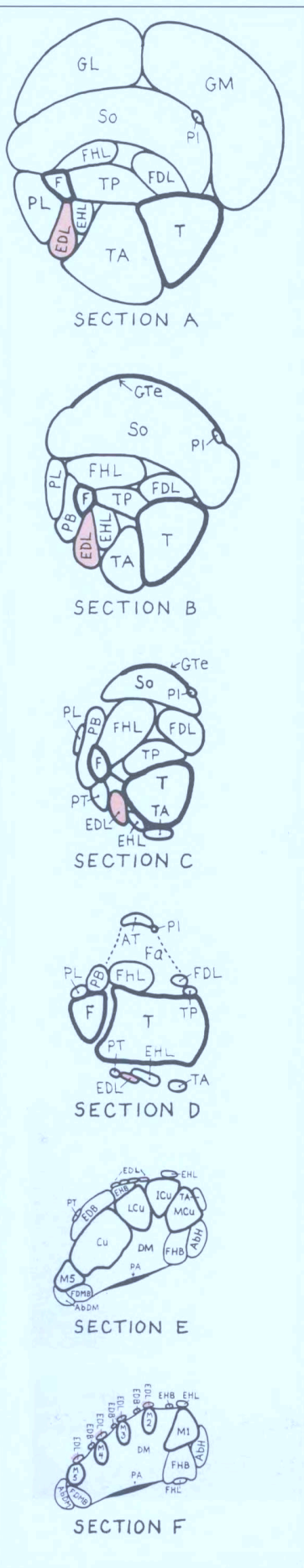
ACTION Extends toes two through five; dorsiflexes the foot at the ankle joint (raises foot) and weakly everts it (faces sole outward). The toes separate when they are extended (they come together when they are flexed).

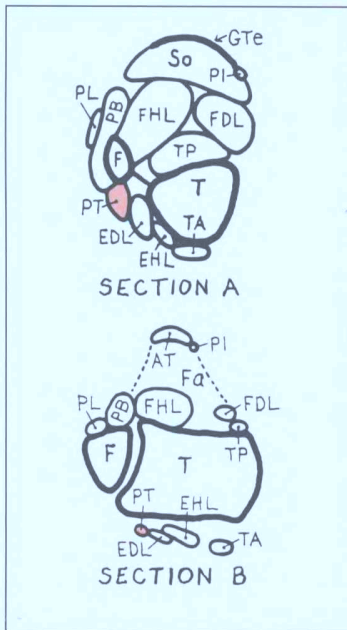
STRUCTURE The long, thin extensor digitorum longus actually consists of four combined bellies and their tendons (one to each of the lateral four toes). The upper portion of the muscle is usually not seen, as it is partly covered by the tibialis anterior, which usually blends with it (dense fascia covering the bellies also obscures their separation). The extensor digitorum longus is unipennate—it develops its tendons along the anterior edge of its belly, beginning just above the midpoint of the lower leg. The belly itself ends approximately three-fourths of the way down the lower leg. Its elongated form is continued inferiorly by the belly

of the peroneus tertius, which although a separate muscle, is somewhat attached.

On the lower portion of the lower leg, the muscle belly narrows, and the four tendons remain close together. They appear to be a single combined tendon, or wide “cable,” as they pass down the front of the ankle, lateral to the midline. This cable becomes most prominent when the foot is everted. When the combined tendon reaches the dorsum of the foot, its four tendons separate and diverge; they may clearly be seen on the top of the foot when the toes are extended. Distally, the tendons disappear from sight on top of the middle of the proximal phalanges, as they widen into a tendinous expansion, the **digital extensor hood**, which continues onward to the insertion. The visible tendon of the little toe is directed toward the head of its metatarsal, not toward the tip of the toe. The others are directed straight toward the ends of the toes.

On occasion, the very superior tip of the fleshy belly of the extensor digitorum longus, at its origin on the lateral condyle of the tibia (between the tibialis anterior and peroneus longus), may be seen. It will appear as a short, raised, linear form when the muscle is contracted to extend the toes (the entire muscle gets shorter and thicker). If the toes are flexed, the extensor digitorum longus will become stretched, and this same area will show up as a narrow, vertical depression.





Peroneus Tertius (Fibularis Tertius)

ORIGIN Lower third of the anterior surface of the shaft of the fibula (not including the lateral malleolus), the adjacent interosseous membrane, and the intermuscular septum between it and the peroneus brevis.

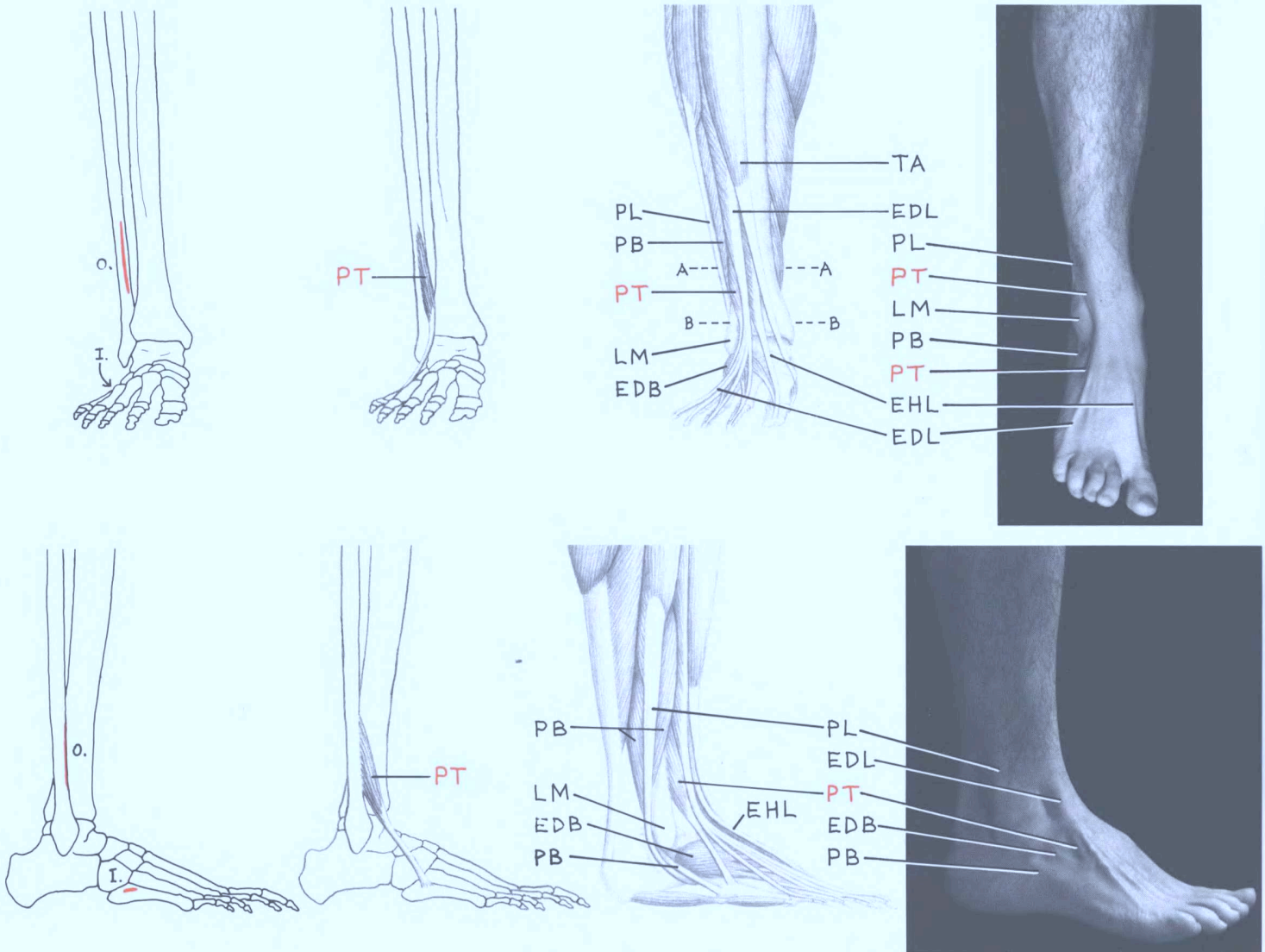
INSERTION Variably into the dorsal surface of the fifth metatarsal bone (of the little toe) at its base or slightly forward of it.

ACTION Dorsiflexes (lifts) and everts the foot.

STRUCTURE The belly of the peroneus tertius can be visualized as a downward continuation of the form of the belly of the extensor digitorum longus. Its fleshy belly descends as low as the lateral malleolus. Its tendon begins on the front edge of its belly and passes down-

ward alongside the tendons of the extensor digitorum longus. These tendons all pass down the front of the ankle together (lateral to the midline) and then separate on the dorsum of the foot. The flattened tendon of the peroneus tertius then passes over the belly of the extensor digitorum brevis and widens just before it finally inserts. This subtle tendon is seen only occasionally, either as a raised tendon or as a furrow on the belly of the extensor digitorum brevis.

Superiorly, the peroneus tertius lies against the peroneus brevis, but the forms of these two muscles usually blend together. The peroneus tertius then passes downward and slightly forward, separating from the peroneus brevis and exposing the lower portion of the shaft of the fibula.



DM Deep muscle EDB Extensor digitorum brevis EDL Extensor digitorum longus
EHL Extensor hallucis brevis EHL Extensor hallucis longus F Fibula LM Lateral malleolus

The Lower Leg Muscles • EXTENSOR HALLUCIS LONGUS

Extensor Hallucis Longus

ORIGIN Middle half of the medial surface of the fibula (medial to the origin of the extensor digitorum longus) and the adjacent interosseous membrane.

INSERTION The top of the base of the distal phalanx of the big toe.

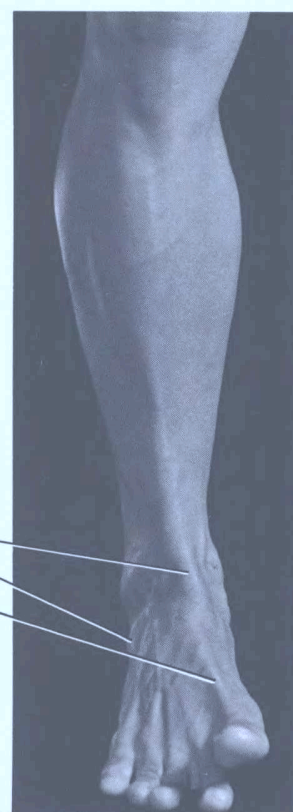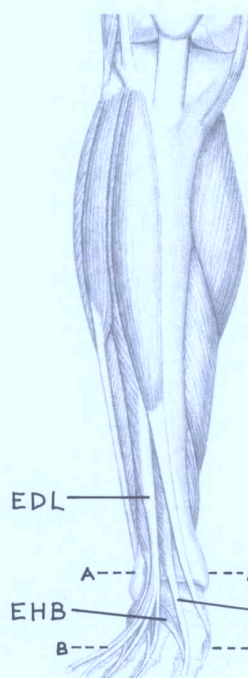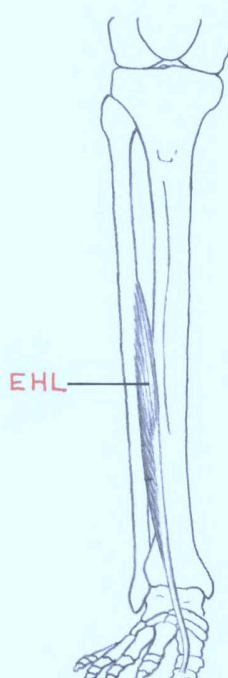
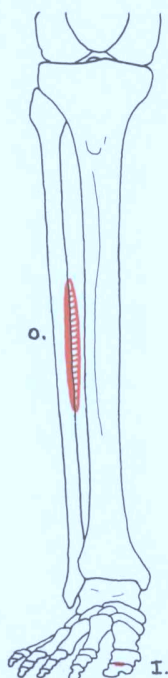
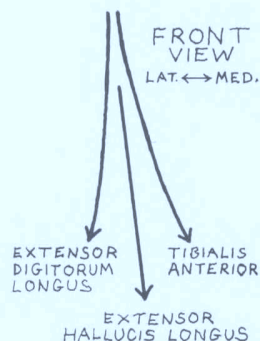
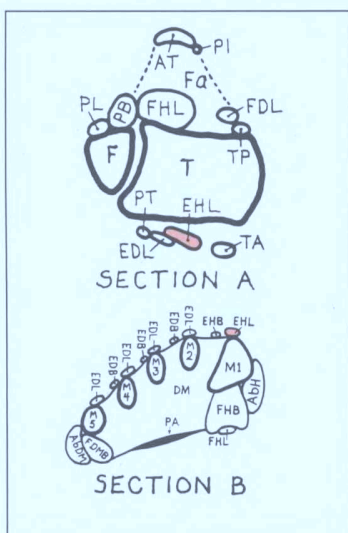
ACTION Extends the big toe; assists in dorsiflexion of the foot.

STRUCTURE The belly of the extensor hallucis longus for the most part lies deep in the lower leg. Its tendon, beginning on the anterior border of its muscle belly, emerges from between the extensor digitorum longus and tibialis anterior roughly two-thirds of the way down the lower leg, but is usually not clearly seen at this point. When the big toe is extended, the tendon becomes visible as it passes down the midline of the front of the ankle and shows up

quite prominently as it descends along the upper surface of the foot on top of the metatarsal of the big toe. It finally disappears just before reaching the interphalangeal joint of the big toe.

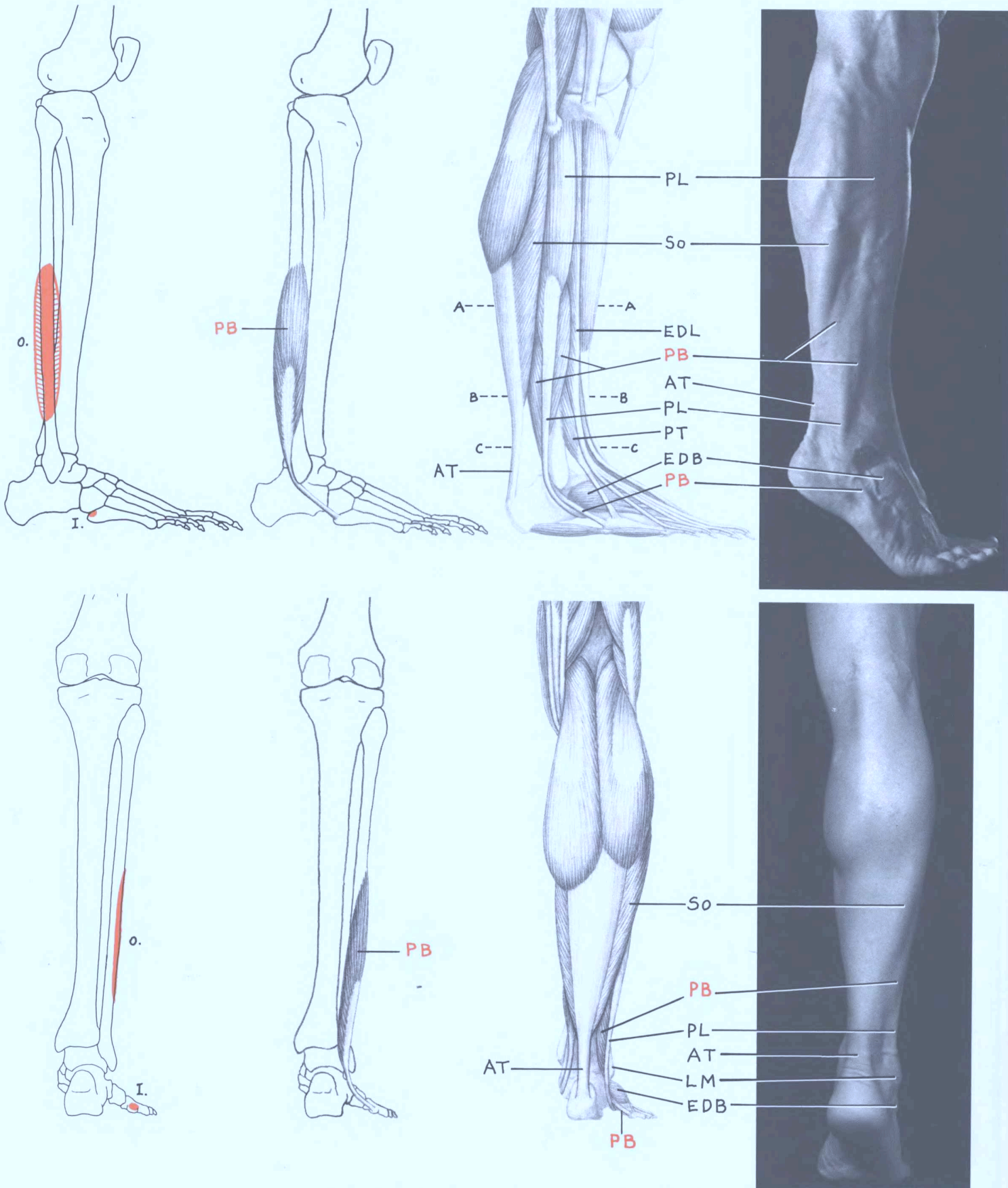
In the side profile view of the ankle, with the foot standing flat on the floor, the most anterior tendon is that of the tibialis anterior. When the big toe is raised (extended), the tendon of the extensor hallucis longus becomes the most anterior tendon.

With the foot dorsiflexed and the big toe alternately flexing and extending, the lower end of the belly of the extensor hallucis longus can be seen sliding up and down at the point where it emerges on the front of the lower leg—it appears as a depression when the toe is extended (the belly shortens and its lower end slides up and disappears) and as a small, elongated bulge when the toe is flexed (the tendon pulls the belly down, exposing it).



M Metatarsal PB Peroneus brevis PL Peroneus longus PT Peroneus tertius T Tibia
TA Tibialis anterior

The Lower Leg Muscles • PERONEUS BREVIS



AT Achilles tendon EDB Extensor digitorum brevis EDL Extensor digitorum longus F Fibula
 Fa Fat FHL Flexor hallucis longus LM Lateral malleolus PB Peroneus brevis PL Peroneus longus
 PT Peroneus tertius So Soleus T Tibia

The Lower Leg Muscles • PERONEUS BREVIS

Peroneus Brevis

ORIGIN Lower two-thirds of the lateral surface of the shaft of the fibula (except the very distal end of the shaft) and the intermuscular septa on both the anterior and posterior sides of its belly.

INSERTION Enlarged base of the metatarsal bone of the little (fifth) toe, on its dorsolateral surface.

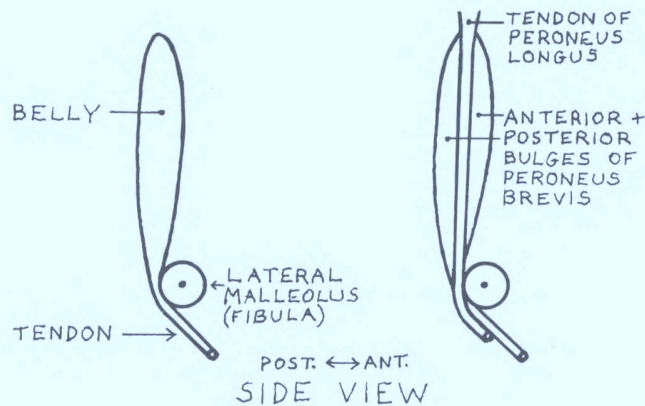
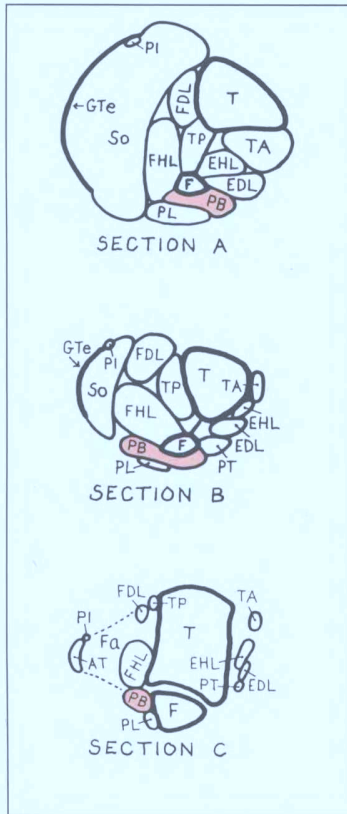
ACTION Everts and plantar flexes the foot.

STRUCTURE The peroneus brevis is an elongated, flattened muscle located on the outside of the lower half of the lower leg. The belly of the larger peroneus longus covers the upper portion of the belly of the peroneus brevis, while the tendon of the former lies on the outer surface of the latter. When the peroneus longus and brevis muscles are relaxed, they create a single elongated form on the outside of the lower leg. When they are tensed, the tendon of the longus presses into the belly of the brevis, dividing it into vertical anterior and posterior forms. The anterior form is often more prominent. The

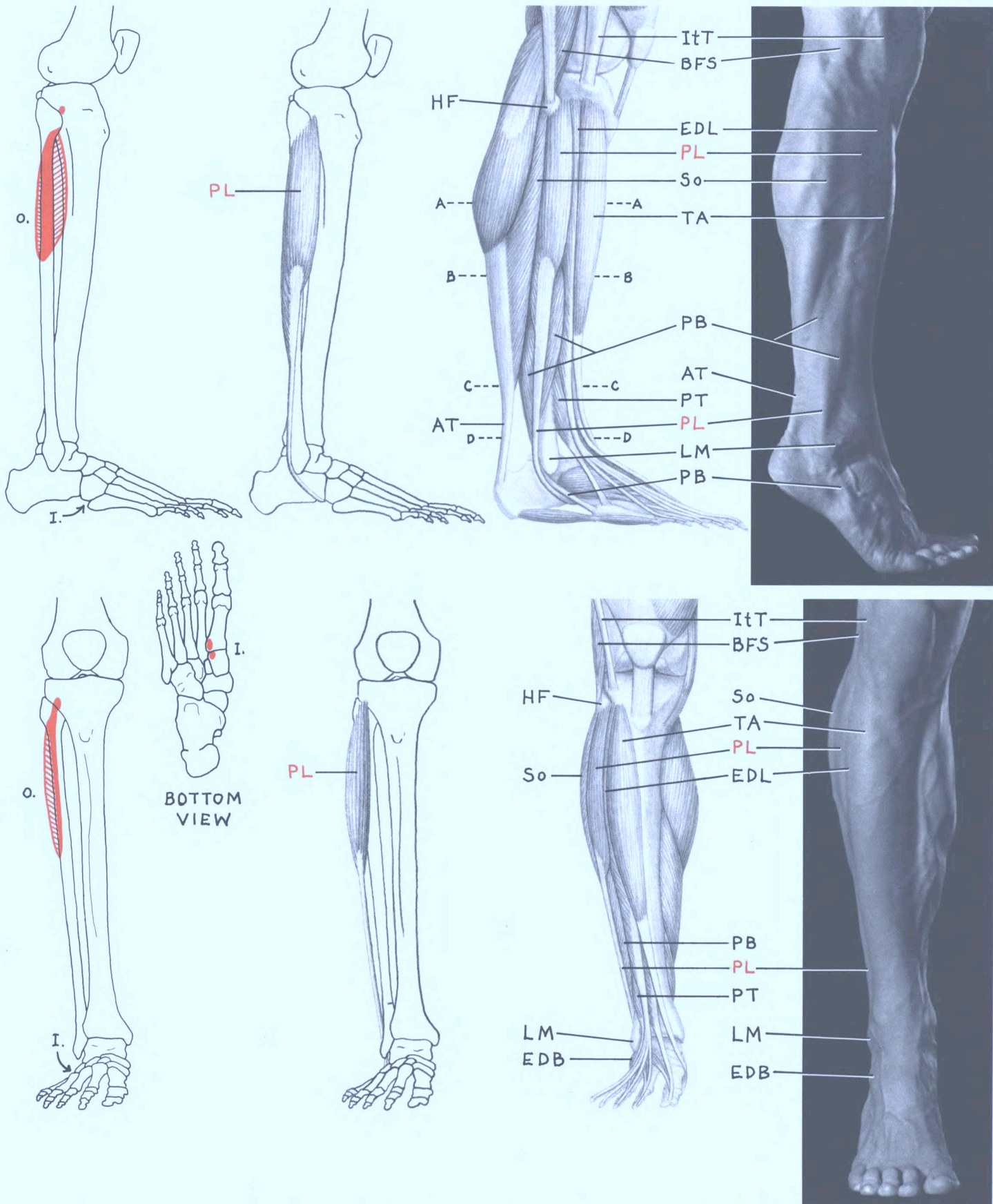
posterior form is sometimes joined by those fibers of the peroneus longus that travel down the back edge of its tendon. The fleshy fibers of the peroneus brevis continue all the way down to the bottom of the back of the lateral malleolus. After its tendon passes down the groove on the back of the lateral malleolus, deep to (anterior to) the tendon of the peroneus longus, it sharply turns diagonally forward at the bottom of the malleolus and heads toward its insertion on the middle of the outside of the foot. It fans out as it inserts.

The tendon of the peroneus longus is usually more prominent for a short distance immediately below the lateral malleolus, but then the tendon of the brevis often becomes more prominent a little further along on the outside of the foot.

The belly of the peroneus brevis forms the outer profile of the lower half of the lower leg from the front view, up to the point at which the inferior portion of the tendon of the peroneus longus becomes raised and visible (above the ankle).



The Lower Leg Muscles • PERONEUS LONGUS



AT Achilles tendon BFS Biceps femoris—short head EDB Extensor digitorum brevis
 EDL Extensor digitorum longus F Fibula FHL Flexor hallucis longus HF Head of fibula
 ItT Iliotibial tract LM Lateral malleolus PB Peroneus brevis PL Peroneus longus PT Peroneus tertius
 So Soleus T Tibia TA Tibialis anterior

Peroneus Longus

ORIGIN Lateral surfaces of the head and upper two-thirds of the shaft of the fibula, a small area on the lateral condyle of the tibia, and the intermuscular septa on both sides of the muscle.

INSERTION Under the foot into the base of the metatarsal bone of the big toe and into the medial cuneiform (tarsal) bone.

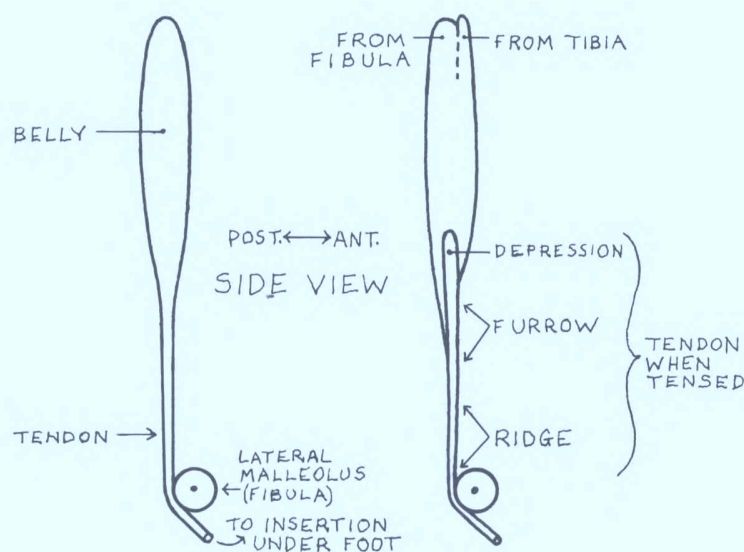
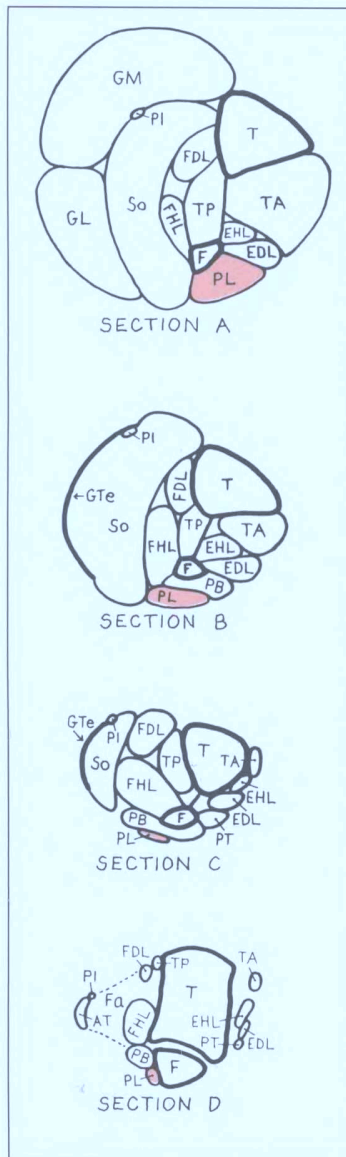
ACTION Everts and plantar flexes the foot. Important in maintaining the arches of the foot.

STRUCTURE The flattened, elongated, ovoid muscle belly of the peroneus longus sits on the upper half of the outside of the lower leg, while its tendon lies on top of the peroneus brevis on the lower half of the leg. The tendon begins approximately at the middle of the outside of the lower leg. The anterior fibers of the belly insert into the tendon's anterior edge for a short distance at the upper end of the tendon, whereas the posterior fibers continue further, inserting into the posterior edge of the tendon at a level two-thirds to three-quarters of the way down the lower leg (sometimes they continue all the way to the lateral malleolus).

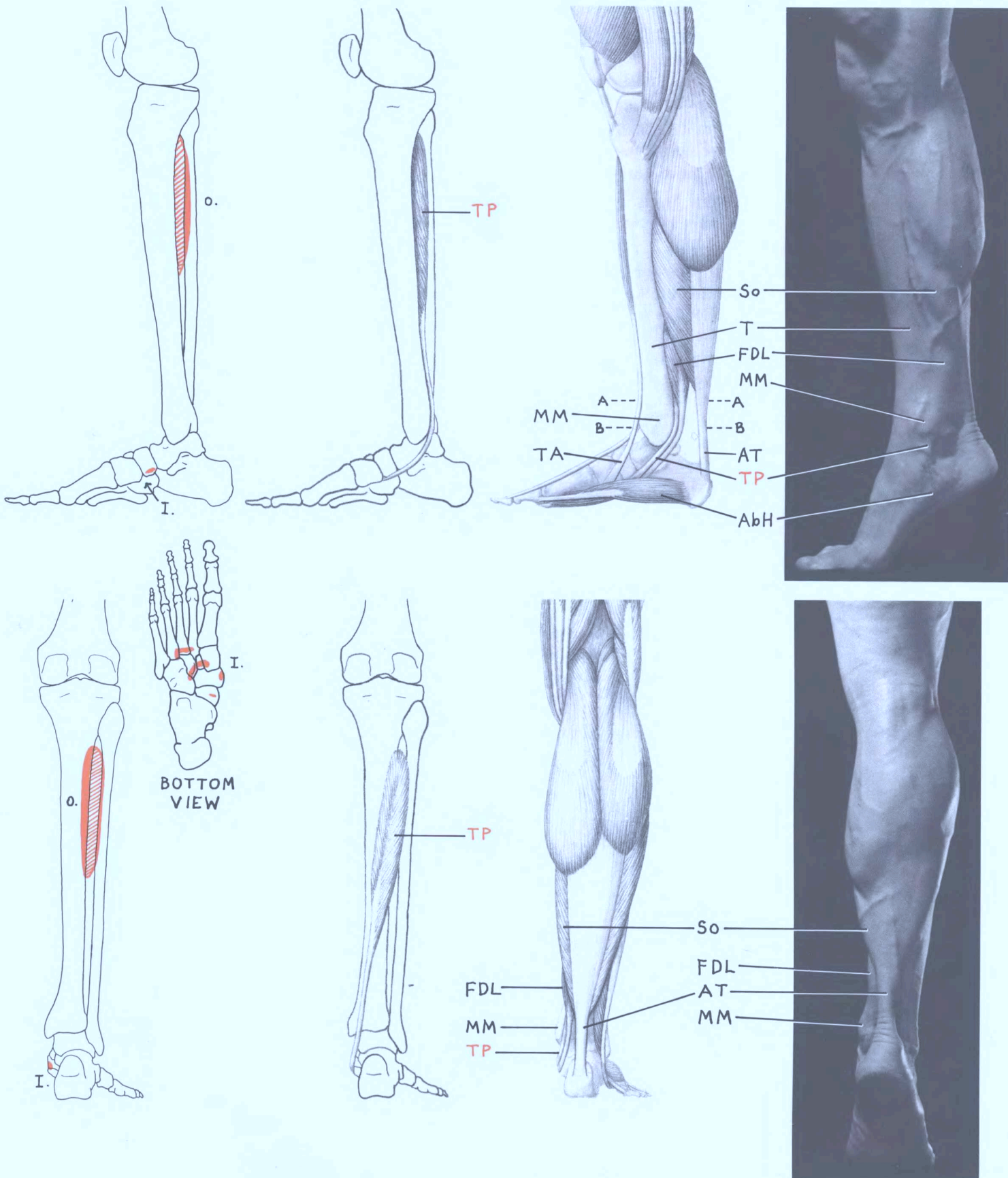
When relaxed, the peroneus longus and brevis combine to create a single elongated form on the outside of the lower leg, directed downward *behind* the lateral malleolus. When tensed, the two muscles differentiate, and the superior end of the *tendon* of the peroneus longus becomes depressed where its muscle fibers

attach into it. The upper portion of the tendon then registers as a vertical furrow separating the belly of the peroneus brevis into narrow anterior (larger) and posterior (smaller) vertical bulges. The lower portion of the peroneus longus tendon becomes a prominent vertical raised ridge passing downward behind the lateral malleolus of the fibula. At the ankle, the tendon remains visible as it passes down the bony groove on the back of the lateral malleolus, posterior and superficial to the tendon of the peroneus brevis. It hooks forward on the outside of the foot below the lateral malleolus, running parallel yet heading deeper than the peroneus brevis tendon. It finally disappears as it curves under the outside of the skeleton of the foot to head toward its insertion. Except for a short distance immediately below the lateral malleolus, the tendon of the peroneus longus is usually less prominent on the outside of the foot than is the tendon of the peroneus brevis.

The outside profile of the upper half of the lower leg (from the front view) is usually caused by the soleus, not the peroneus longus. The small portion of the peroneus longus that attaches to the lateral condyle of the tibia may show up as a distinct thin form when the muscle is contracted. Also, the anterior one-fourth of the muscle belly and its tendon may occasionally separate into what appears to be a distinct, thin muscle.

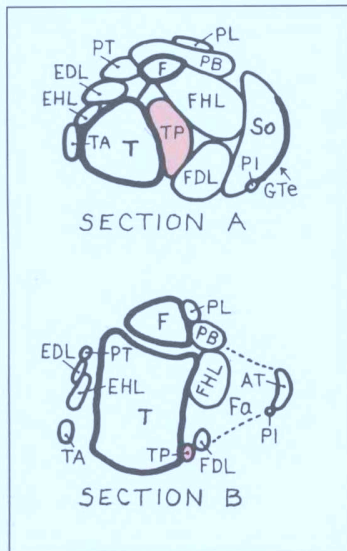


The Lower Leg Muscles • TIBIALIS POSTERIOR



AbH Abductor hallucis AT Achilles tendon F Fibula FDL Flexor digitorum longus
 FHL Flexor hallucis longus MM Medial malleolus So Soleus T Tibia TA Tibialis anterior
 TP Tibialis posterior

The Lower Leg Muscles • TIBIALIS POSTERIOR



Tibialis Posterior

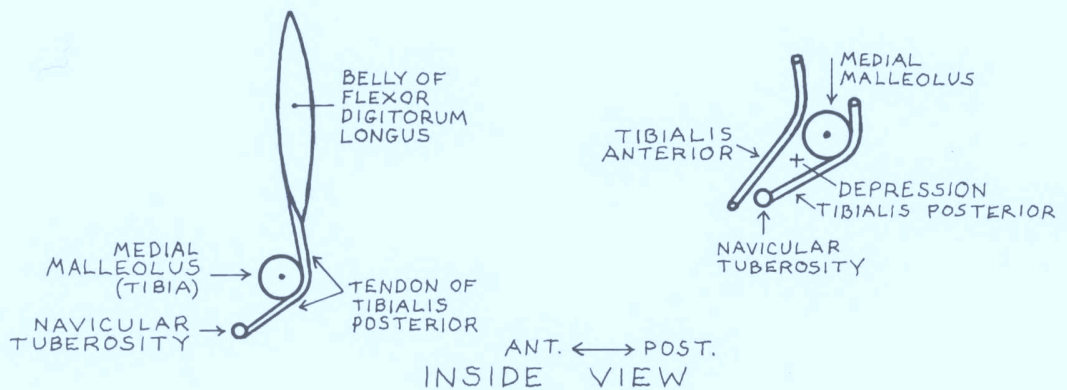
ORIGIN Lateral half of the posterior surface of the tibia, from below the lateral condyle to a point two-thirds of the way down the bone; the upper two-thirds of the medial surface of the fibula; and the interosseous membrane between these two bony origins.

INSERTION Deep, into the bottom (plantar surface) of the middle of the foot skeleton—variously into six tarsal bones (navicular, three cuneiforms, cuboid, and talus) and the bases of the second, third, and fourth metatarsals. The visible tendon, on the inside of the ankle, is seen directed to its insertion on the navicular bone just below the prominent navicular tuberosity. The tendon then continues onward to expand under the foot, out of view.

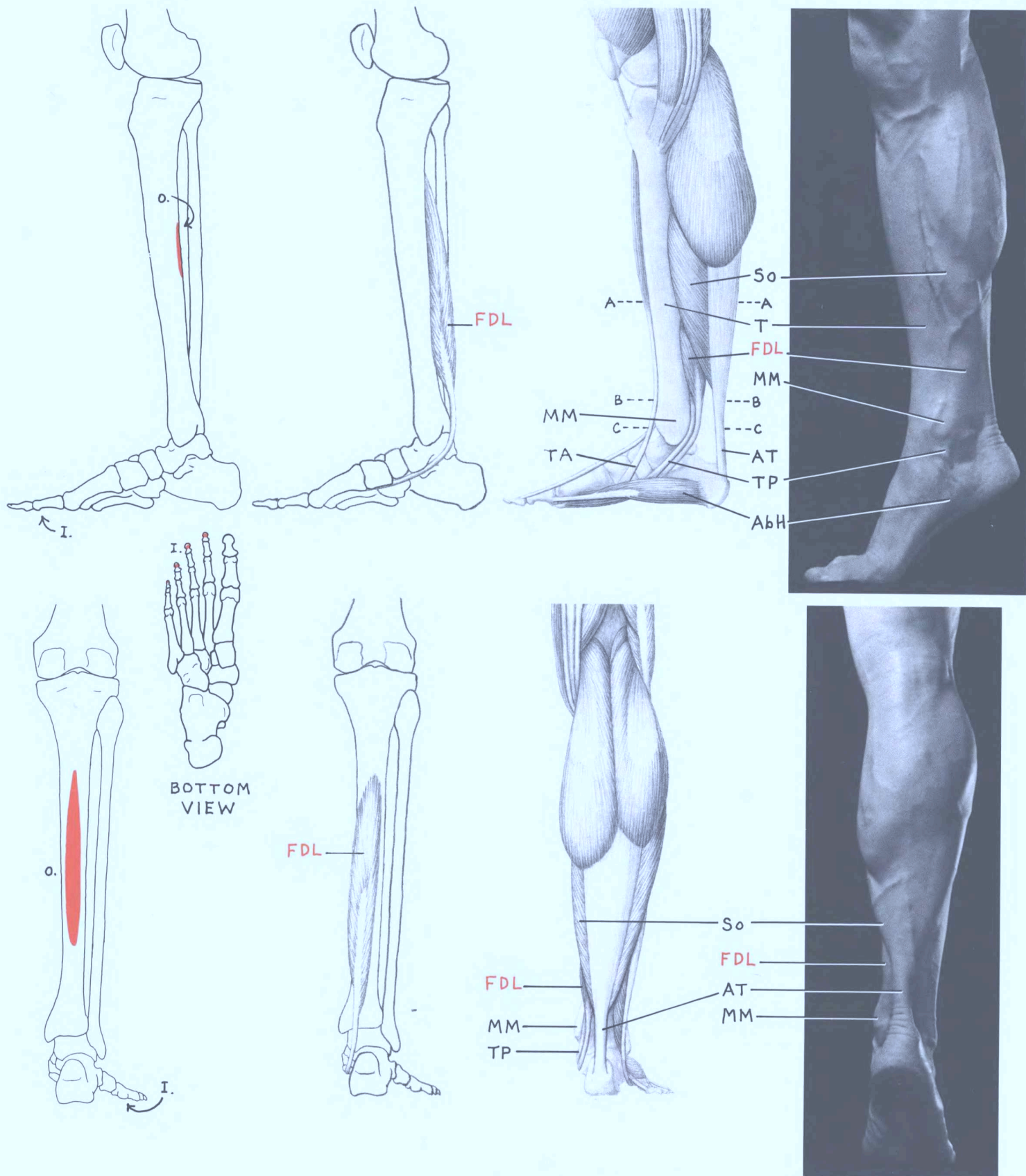ACTION Plantar flexes and inverts the foot. It is the strongest support of the longitudinal arch of the foot.

STRUCTURE Beginning deep at the upper end of the back of the lower leg, only the tendon of the tibialis posterior is superficial and visible for a short distance above, behind (lying in its bony groove), and below the medial malleolus. Its deep muscle belly and tendon run diagonally downward and medially, deep to the more vertical flexor digitorum longus. Just above the ankle, the oblique tendon of the tibialis posterior emerges superficially on the medial side of the vertical flexor digitorum longus. It is most prominent from where it angles forward below the medial malleolus to where it disappears under the prominence of the tuberosity of the navicular bone, on the medial side of the foot. Deep under the foot the tendon fans out as it inserts.

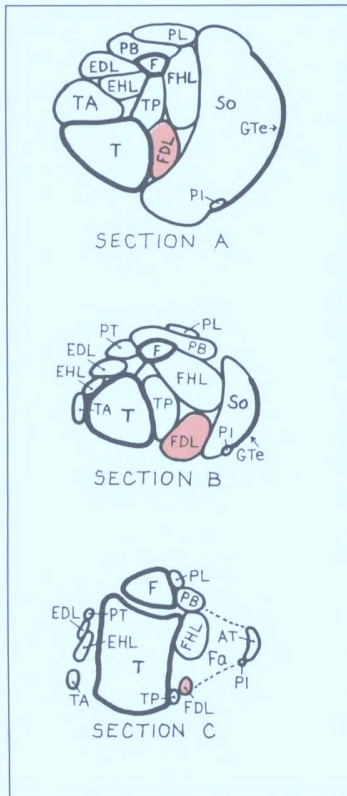
When the foot is inverted, the tendons of the tibialis anterior and posterior can be seen converging distally. A depression forms between them in front of the medial malleolus.



The Lower Leg Muscles • FLEXOR DIGITORUM LONGUS



AbH Abductor hallucis AT Achilles tendon F Fibula Fa Fat FDL Flexor digitorum longus
FHL Flexor hallucis longus MM Medial malleolus So Soleus T Tibia TA Tibialis anterior
TP Tibialis posterior



Flexor Digitorum Longus

ORIGIN Middle half of the back surface of the shaft of the tibia, beginning just below the soleal line.

INSERTION Bases of the distal phalanges of toes two through five on their plantar surfaces (*not* into the big toe).

ACTION Flexes the distal phalanges of the lateral four toes, especially for the final push-off in walking and running. By continued action, it plantar flexes and inverts the foot.

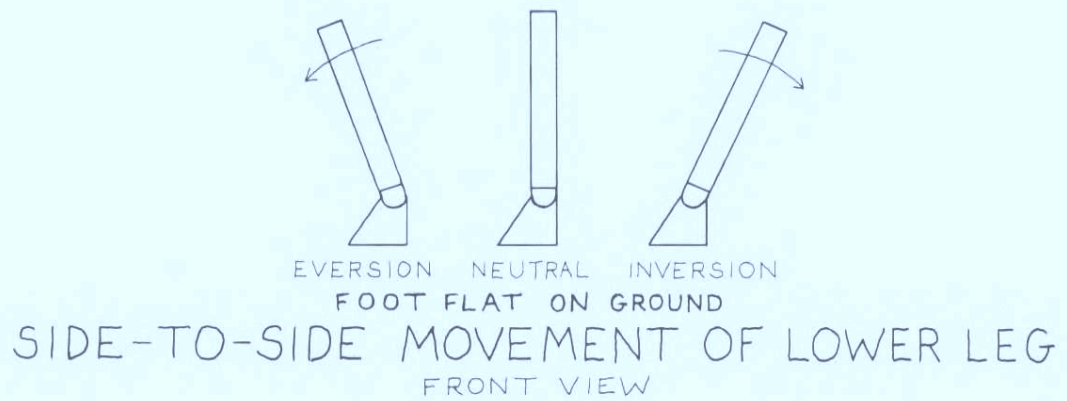
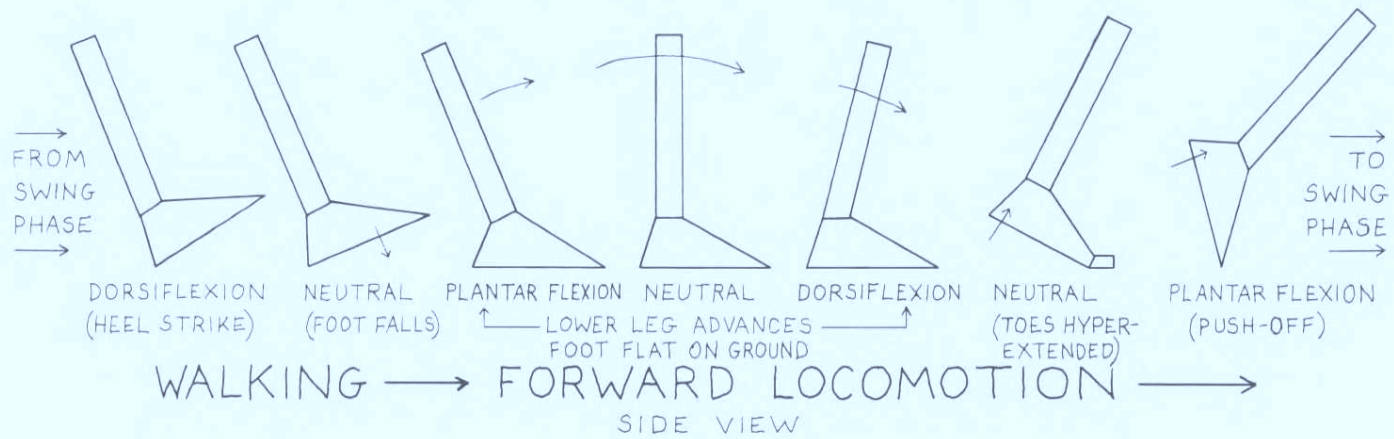
STRUCTURE Beginning deep in the lower leg on the back of the tibia, and ending deep under the foot, only a small portion of the belly of the flexor digitorum longus is subcutaneous on the lower third of the inside of the lower leg, just posterior to the medial surface of the shaft of the tibia. It is not distinct, but rather fills a small area between the tibia and lower anterior edge of the soleus. The exposed muscle fibers taper into a tendon that becomes concealed as it shifts away from the surface, lateral to the tendon of the tibialis posterior, which has now emerged from between the tibia and flexor digitorum longus and become superficial. The ten-

don of the flexor digitorum longus then curves behind the pulley of the medial malleolus (in the same bony compartment as the tibialis posterior tendon) and divides into the four tendons heading to the lateral four toes. Although the tendon of the flexor digitorum longus lies adjacent to but on a slightly deeper plane than the conspicuous tendon of the tibialis posterior, it is not seen.

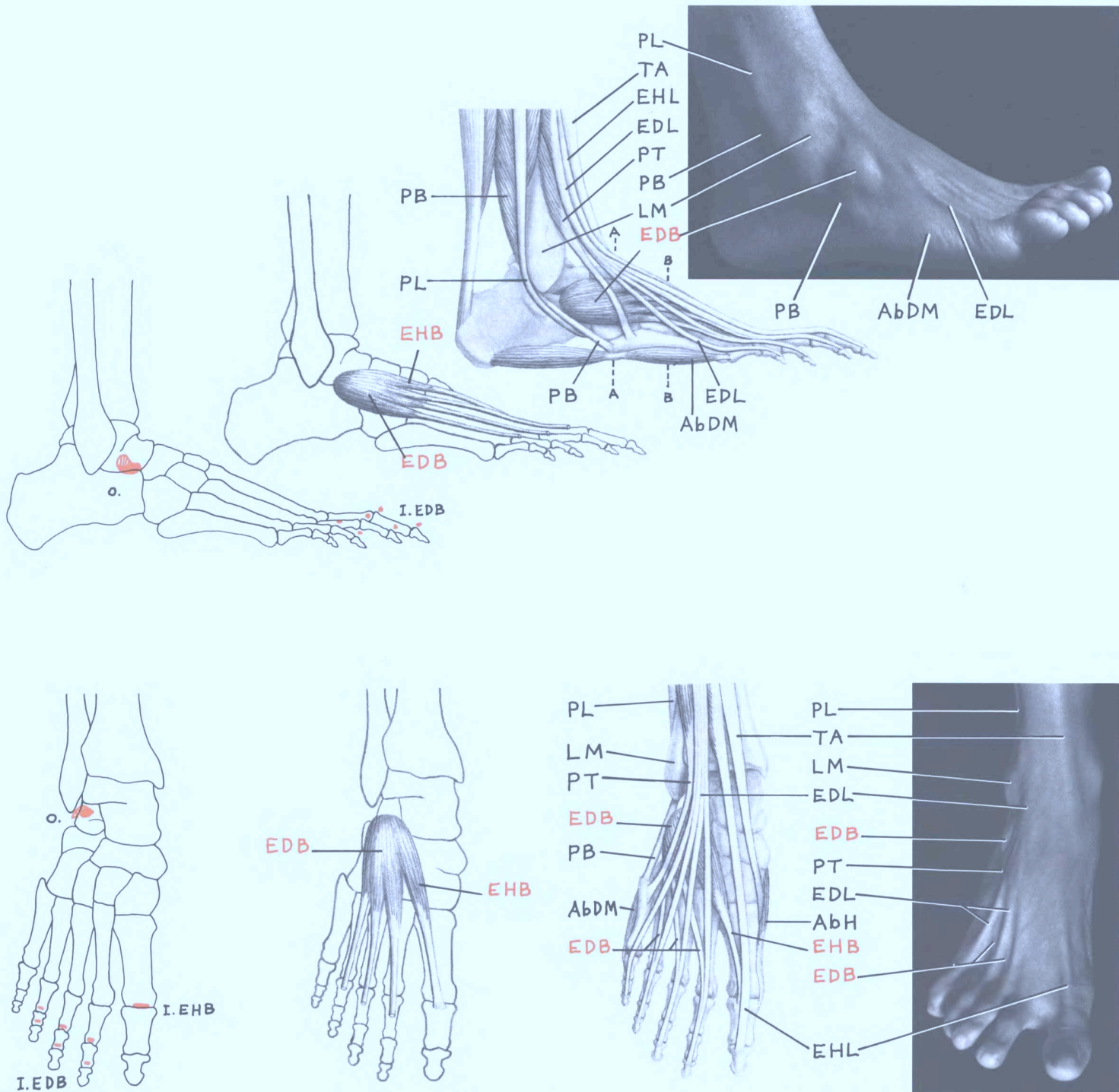
The flexor digitorum longus is attached to the deep **flexor hallucis longus** muscle (flexor of the big toe) under the foot by a tendinous slip. When the toes are alternately flexed and extended together, the inferior ends of the bellies of both these muscles can be seen rising and descending just behind and below the medial malleolus. A noticeable depression is created between the medial malleolus and Achilles tendon when the toes are fully flexed. Even though the flexor hallucis longus is deep, the ascent of the inferior end of its belly affects surface form. Because of the tendinous connection between them, the flexor hallucis longus and flexor digitorum longus must be flexed together to achieve *full* flexion of all the toes.

The Foot Muscles

RELATIONSHIP OF FOOT VOLUME TO LOWER LEG + GROUND

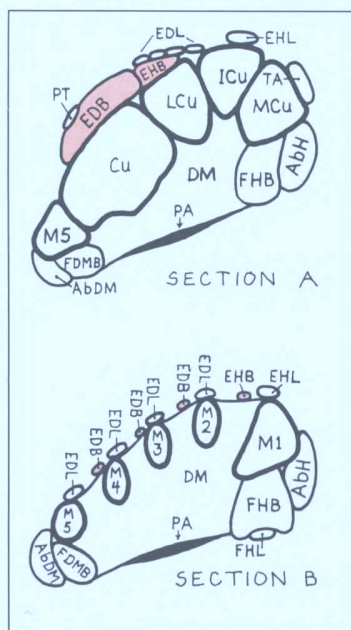


The Foot Muscles • EXTENSOR DIGITORUM BREVIS



AbDM Abductor digiti minimi AbH Abductor hallucis Cu Cuboid DM Deep muscle
 EDB Extensor digitorum brevis EDL Extensor digitorum longus EHB Extensor hallucis brevis
 EHL Extensor hallucis longus LCu Lateral cuneiform LM Lateral malleolus M Metatarsal
 PB Peroneus brevis PL Peroneus longus PT Peroneus tertius TA Tibialis anterior

The Foot Muscles • EXTENSOR DIGITORUM BREVIS



Extensor Digitorum Brevis (including Extensor Hallucis Brevis)

ORIGIN *Entire muscle:* The upper surface of the front end of the calcaneus, the inferior extensor retinaculum, and the lateral talocalcaneal ligament.

INSERTION To the medial four toes as follows: **Extensor hallucis brevis** (to the big toe): *into bone*; it inserts into the upper surface of the base of the proximal phalanx of the big toe. **Extensor digitorum brevis** (to the middle three toes): *into tendon*; its tendons join the lateral sides of the tendons of the extensor digitorum longus heading to the second, third, and fourth toes. It therefore ultimately inserts into the middle and distal phalanges of the middle three toes. These tendon-to-tendon fusions occur on the top of the proximal phalanges.

ACTION **Extensor hallucis brevis:** extends the proximal phalanx of the big toe. **Extensor digitorum brevis:** extends the phalanges of the second, third, and fourth toes at the interphalangeal and metatarsophalangeal joints; pulls these toes laterally at the metatarsophalangeal joints.

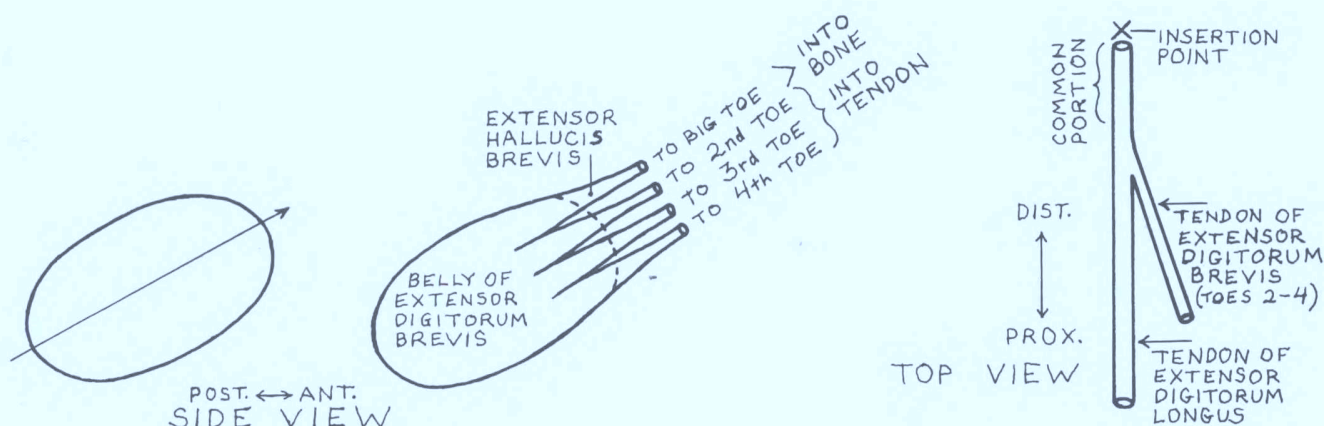
STRUCTURE The overall extensor digitorum brevis muscle is made up of four slender, flat bellies that pass forward and medially over the top of the foot. These bellies develop into tendons distally. The combined bellies create an oval bulge on the outside of the top of the foot, located below and in front of the lateral malleolus. The bulge, directed forward, upward, and

medially, is always present, but the individual bellies and their tendons are only occasionally visible.

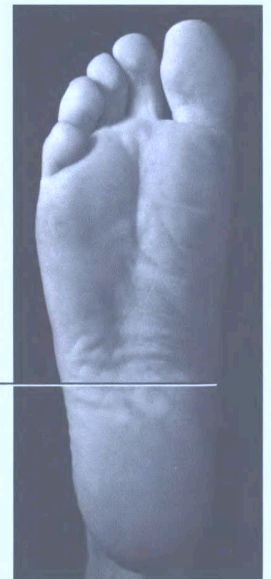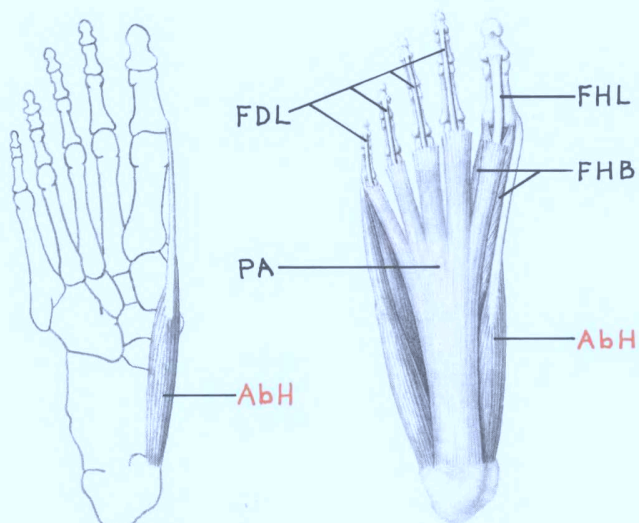
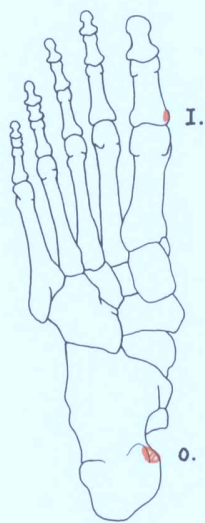
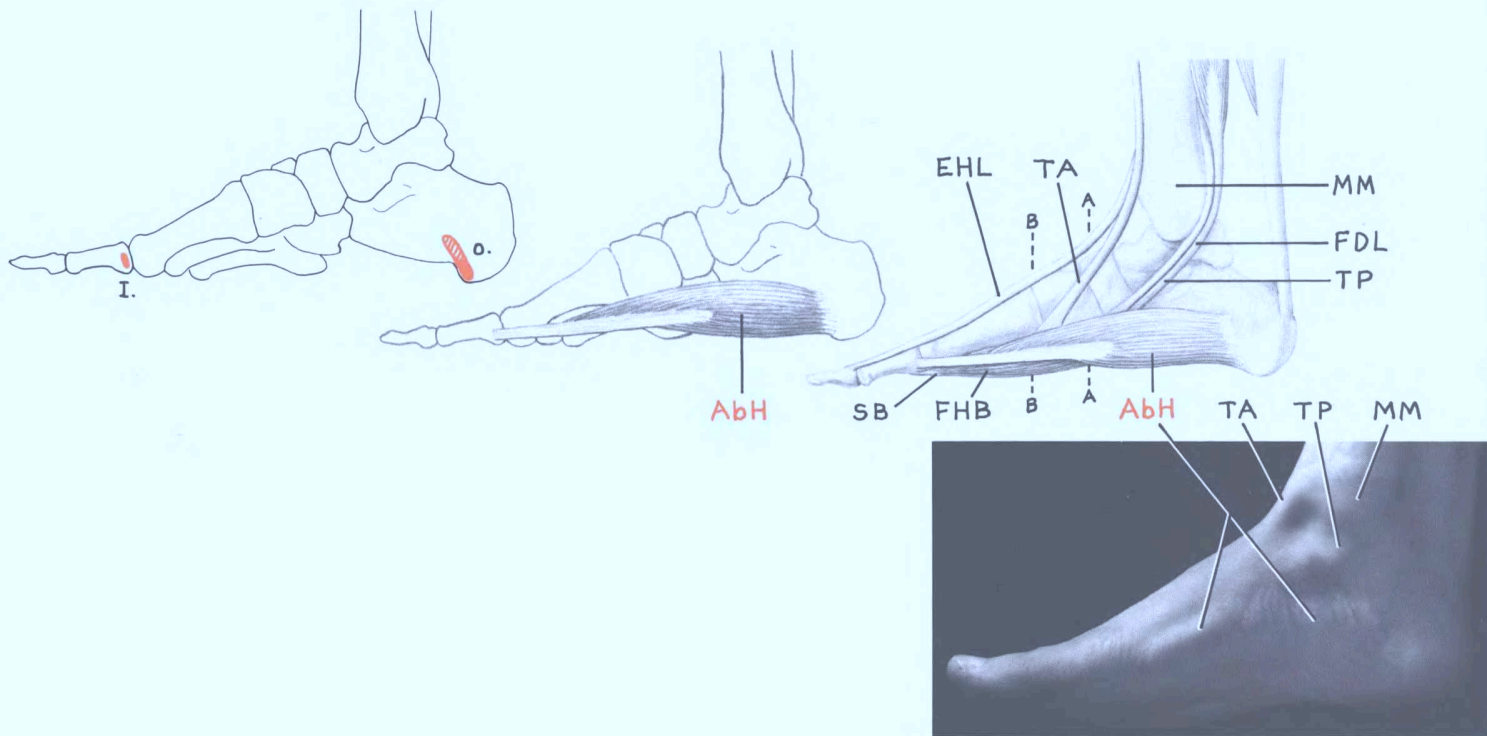
The most medial portion of the extensor digitorum brevis, inserting into the big toe, is also referred to as the **extensor hallucis brevis**. It differs from the other bellies of this muscle by inserting into bone, rather than into the sides of tendons. When the big toe is flexed, the narrow, flat belly of the extensor hallucis brevis may be seen on the dorsum of the foot, between the tendons of the extensor hallucis longus and extensor digitorum longus of the second toe. Although flexing the big toe will stretch the belly of the extensor hallucis brevis and make it thinner, it also pulls the belly distally, so it can be seen in the interval between the tendons that border it on the dorsum of the foot.

The tendons to the middle three toes can occasionally be seen on top of the distal half of the metatarsus, in the three spaces between the four long tendons of the extensor digitorum longus. These tendons of the extensor digitorum brevis are directed posteriorly toward the lateral malleolus, whereas the tendons of the extensor digitorum longus are directed toward the middle of the front of the ankle.

Note: The extensor digitorum brevis (including the extensor hallucis brevis) does not insert into the little toe; it inserts into the medial four toes only.



The Foot Muscles • ABDUCTOR HALLUCIS



AbH Abductor hallucis DM Deep muscle EHL Extensor hallucis longus
 FDL Flexor digitorum longus FHB Flexor hallucis brevis FHL Flexor hallucis longus M Metatarsal
 MCu Medial cuneiform MM Medial malleolus PA Plantar aponeurosis SB Sesamoid bone
 TA Tibialis anterior TP Tibialis posterior

The Foot Muscles • ABDUCTOR HALLUCIS

Abductor Hallucis

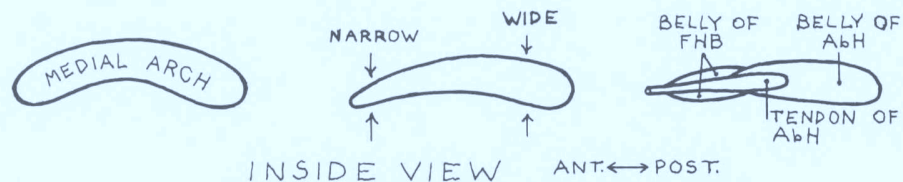
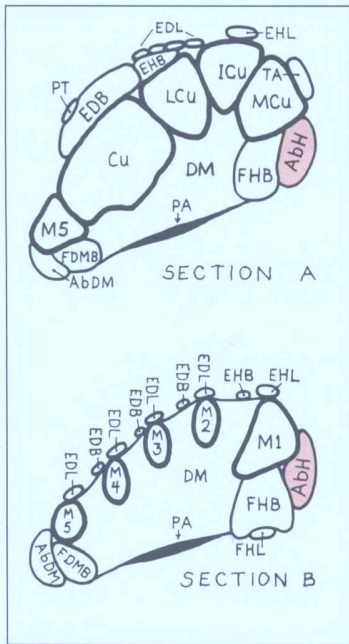
ORIGIN Medial process on the bottom of the calcaneus, the anterior edge of the flexor retinaculum of the ankle (stretching between the heel and medial malleolus), and the plantar aponeurosis.

INSERTION Medial side of the base of the proximal phalanx of the big toe.

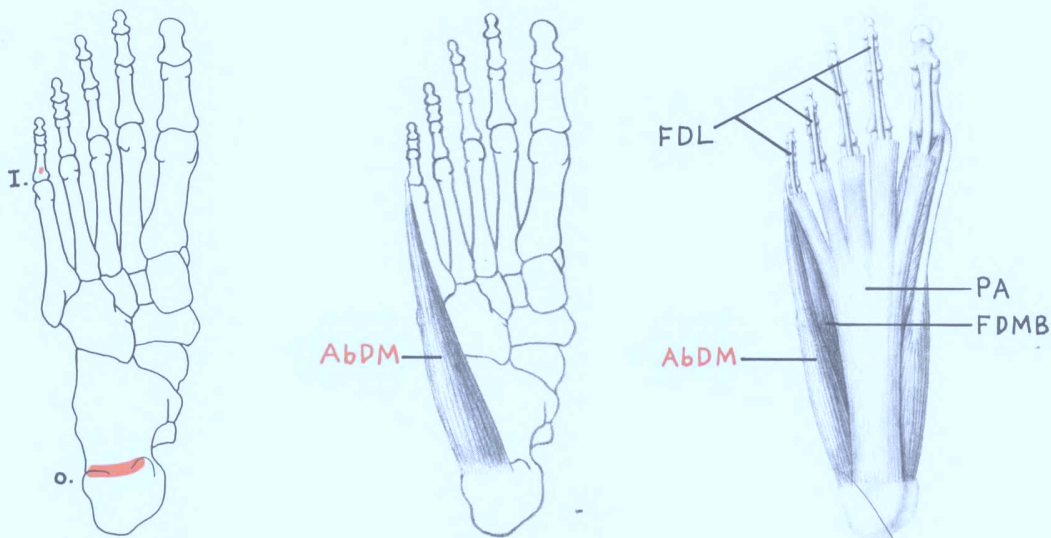
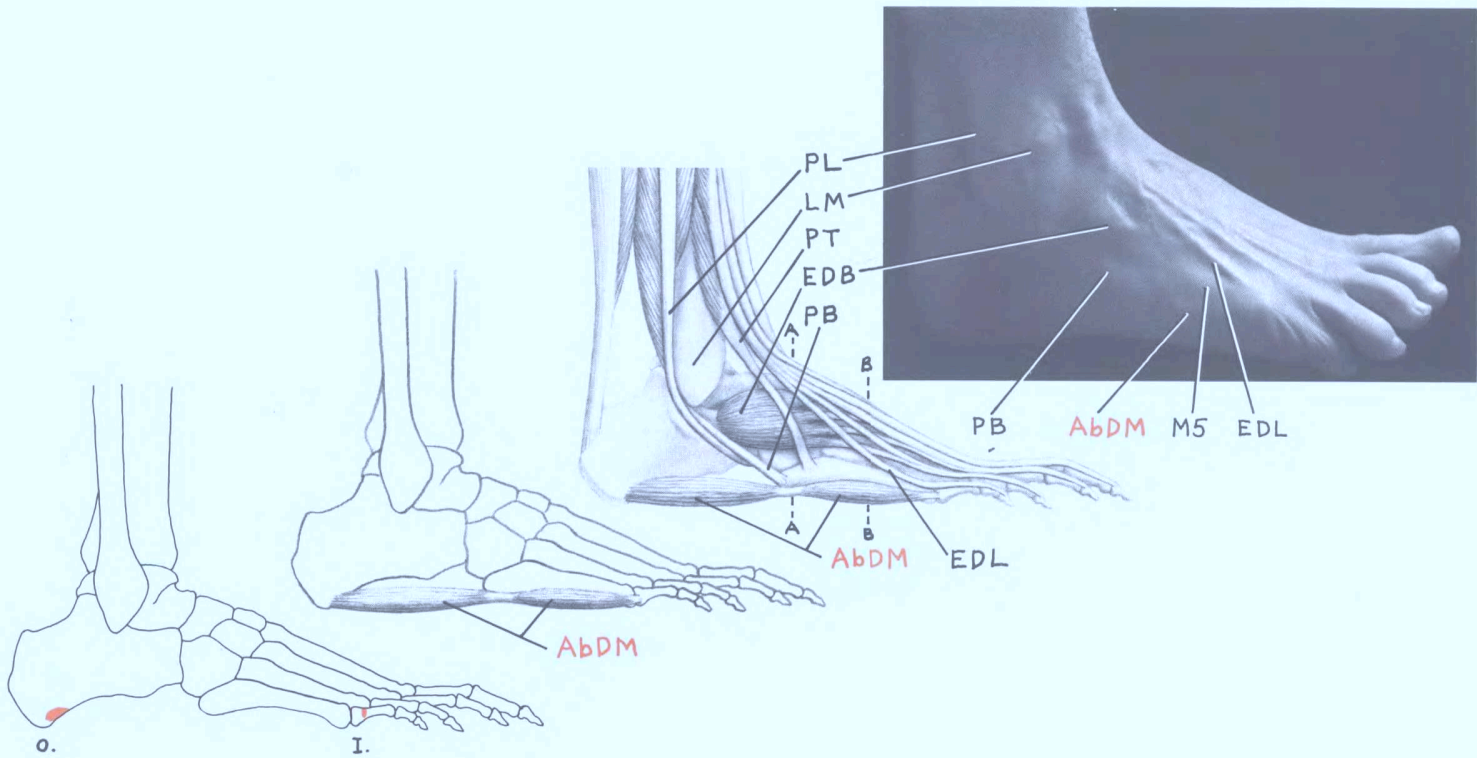
ACTION Flexes more than it actually abducts the metatarsophalangeal joint of the big toe.

STRUCTURE The abductor hallucis begins from a wide origin near the posterior end of the

inside of the foot. Its posterior two-thirds is fleshy muscle belly; the anterior third is tendon. Muscle fibers continue to insert along the top edge of the tendon for a variable distance. The abductor hallucis combines with the flexor hallucis brevis, which is located anteriorly under its tendon, to create a slight raised relief along the medial border of the foot. This form lies on the inner arch of the foot, below the tuberosity of the navicular bone, and curves upward at its center to conform to the rounded medial arch. Its elongated oblong form stretches from the heel to the metatarsophalangeal joint of the big toe.

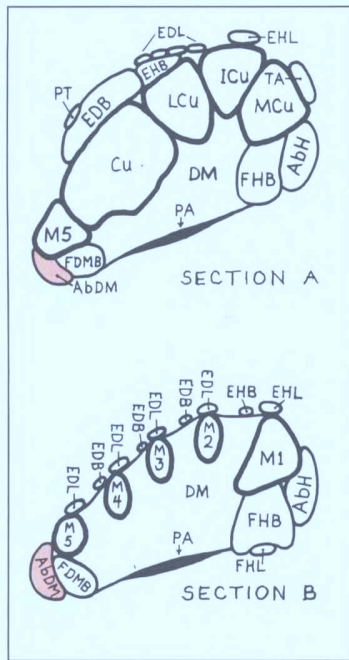


The Foot Muscles • ABDUCTOR DIGITI MINIMI



AbDM Abductor digiti minimi EDB Extensor digitorum brevis EDL Extensor digitorum longus
 FDL Flexor digitorum longus FDMB Flexor digiti minimi brevis LM Lateral malleolus M Metatarsal
 PA Plantar aponeurosis PB Peroneus brevis PL Peroneus longus PT Peroneus tertius

The Foot Muscles • ABDUCTOR DIGITI MINIMI



Abductor Digit Minimi

ORIGIN Both the medial and lateral processes and the intervening bone between these areas, on the bottom of the calcaneus, and from the plantar aponeurosis.

INSERTION Lateral aspect of the base of the proximal phalanx of the little toe.

ACTION Abducts and assists in flexing the little toe.

STRUCTURE This muscle lies under the lateral border of the foot. In side view, it appears to have two bellies, one anterior and one posterior to the expanded base of the fifth metatarsal bone. Its tendon develops on the deep (superior) aspect of the belly before reaching the level of the base of the fifth metatarsal, but its fleshy fibers usually continue anteriorly up to the head

of the fifth metatarsal. At the midpoint of the foot, the tendon glides over the smooth under-surface of the expanded base of the fifth metatarsal.

Passing anteriorly from the origin of the abductor digiti minimi, some fibers insert into the base of the fifth metatarsal, while some new fibers take origin from it.

This muscle is for the most part concealed by the dense, fibrous fat pad of the sole of the foot. However, the anterior portion of the belly located between the base of the fifth metatarsal and the metatarsophalangeal joint can occasionally be seen on the surface lying lateral to the shaft of the fifth metatarsal. Its form is very subtle. The posterior portion is concealed by the plantar fat.

Eye

overhang the lower eyelid slightly. The inner and outer corners usually lie on a horizontal line or else the outer corner sits at a level slightly higher than the inner corner. The inner corner is located more anteriorly, while the outer corner sits more posteriorly toward the *side* of the eyeball; the axis through the corners of the eye therefore passes laterally and posteriorly. A depression is located above the inner corner of the eye.

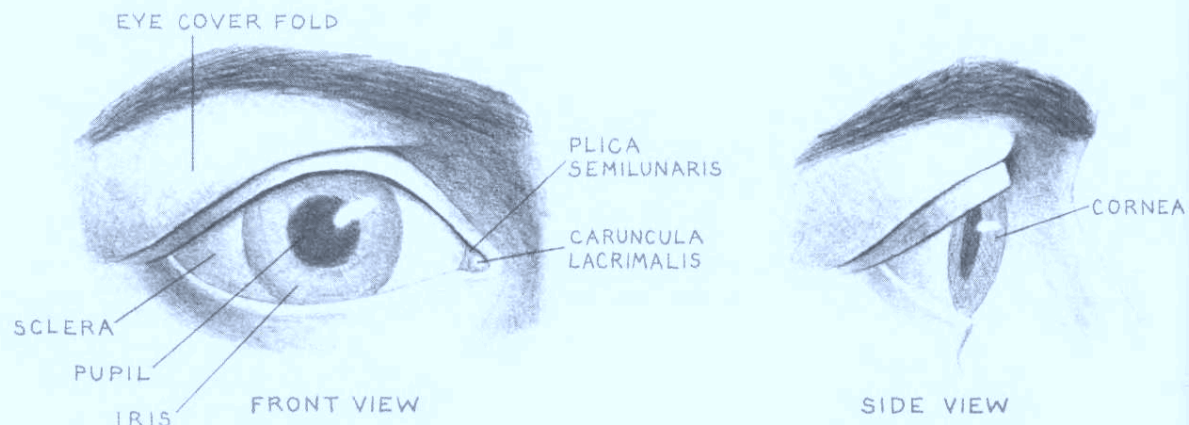
The front surface of the open eye (eyeball and lids) can be simplified into a plane that is curved side to side and directed forward and *downward*. The side-to-side curvature is accounted for by the roundness of the eyeball. The plane faces downward because the edge of the upper eyelid projects more anteriorly (it is near the equator) than the edge of the lower eyelid. In other words, the plane of the front of the eye is created by the lower half of the front of the eyeball and the eyelids.

When the eye is focused at infinity, the axes of both eyeballs are parallel. As the eyes focus

on nearer and nearer objects, the axes converge, ultimately assuming a cross-eyed position at their greatest convergence. The axes never diverge (become "wall-eyed") in normal eyes.

The **eye cover fold** is the skin flap below the lateral portion of the eyebrow and above the lateral portion of the upper eyelid. It is seen as a bulging, oblique skin form (somewhat tear-drop-shaped) when the eye is in the normal open position. It conceals the upper and outer edges of the bony orbit. Laterally, the wide end of this form ends past the outer corner of the eye. It is sometimes more flat than round, and creates a down plane under the eyebrow. When the eyebrows are raised, this form disappears as the skin is stretched, revealing the shape of the bony orbit.

The lower border of the lower eyelid meets the upper portion of the front of the cheek at a definite line, or change of plane. The crescent-shaped **tear bag** is located below this line. It becomes more prominent as a person ages.



Nose

The *NOSE* is made up of bone, cartilage, and fatty tissue. It is pyramidal in shape, consisting of a long narrow plane on its front edge, two inclined side planes, and a triangular bottom plane.

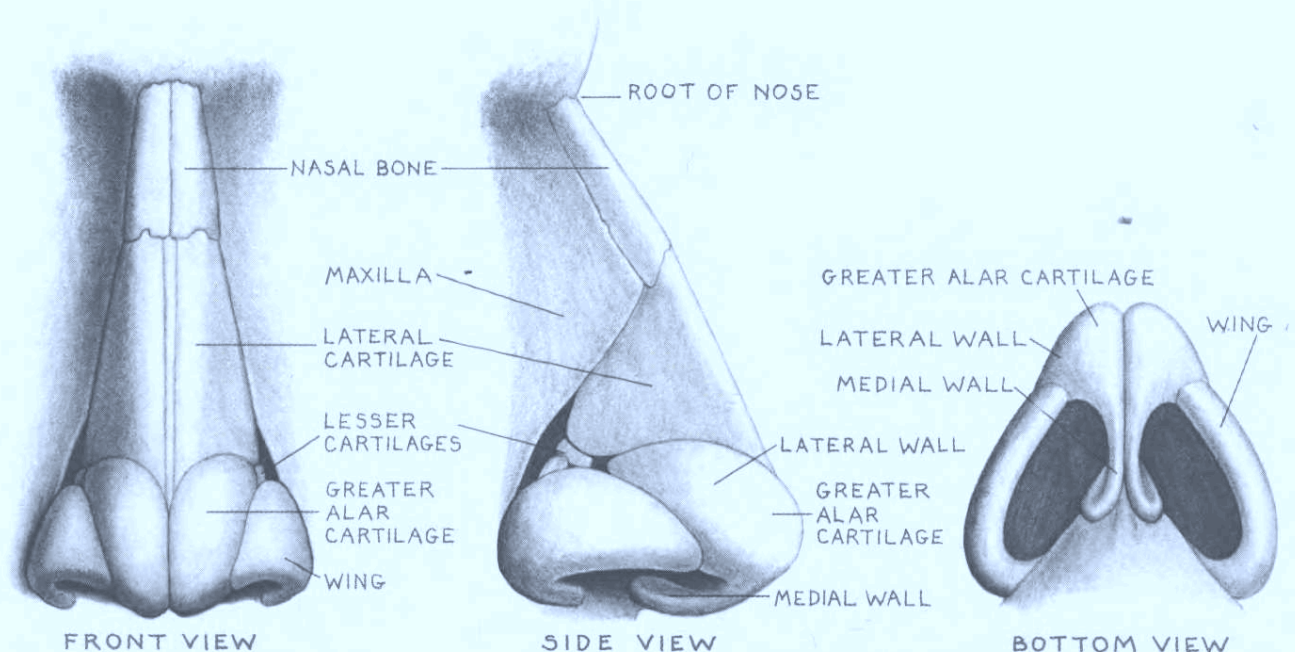
The **bridge of the nose** is formed by the two nasal bones. The junction of these bones with the frontal bone at the **nasion** is called the **root of the nose**. The middle section of the nose is made up of the flat, paired **lateral cartilages** (upper cartilages), each triangular in shape. The junction on the front edge of the nose between the nasal bones and lateral cartilages is the widest part of the bridge. In side view, the nasal bones meet the lateral cartilages at an angle, forming the "bump" of the nose. The maxilla bone, located posterior to the nasal bone and nasal cartilages, contributes to the formation of the side plane of the nose.

The **tip** or **apex** of the nose is made up of the paired **greater alar cartilages** (lower or tip cartilages). Each greater alar cartilage is somewhat U-shaped, but is better visualized as having a larger, flattened, ovoid portion, the **lateral wall** (lateral crus), and an inferior extension or tail, the **medial wall** (medial crus). The lateral wall forms the tip of the nose and then extends to the side of the nose between the lateral cartilage and wing of the nose. The greater alar cartilages may inconspicuously blend into the rest of the nose, or they may be clearly defined all around and separated by a vertical groove or notch where the two meet in front. They also range from being rounded to exceedingly

pointed at the tip of the nose (a short distance on either side of the midline). The bottom of the ovoid lateral wall may develop a distinct, narrow, sharp plane. The medial wall forms the **movable nasal septum**, located at the midline on the bottom of the nose between the nostrils. This septum is visible from the side view because it descends lower than the wing of the nose. The **plane** of the opening of each nostril is therefore directed downward and slightly outward, permitting the opening of the nostril to be seen partially from the side view. From below, the entire greater alar cartilage (both lateral and medial walls) is seen bordering the anterior half of the nostril.

Two to four **lesser alar cartilages** (small, or sesamoid, cartilages) are found on each side of the nose at the posterior end of the lateral wall of the greater alar cartilage. They are not seen in life. The rounded **wing of the nose**, or **alae nasi**, made up of dense, fibrous, fatty connective tissue, surrounds the **nostrils**, or **nares**. These oval apertures taper anteriorly and are directed anteriorly and medially when seen from below. The rigid, vertical **septal cartilage** lies inconspicuously between the paired cartilages, on the midline of the nose. It does not participate in the formation of the movable nasal septum.

The nasal bones are completely rigid, the lateral cartilages semirigid, the greater alar cartilages slightly flexible, and the fatty wings soft and flexible. The nose is therefore harder and strongly attached superiorly and softer and more movable inferiorly.



Mouth

The **MOUTH** consists of the muscular, highly movable upper and lower **lips**, or **labia**. The mouth region includes more than just the red portion of the lips; it technically extends from the base of the nose down to the fleshy prominence of the chin (to the mentolabial sulcus). The red color of the lips is caused by blood capillaries lying close to the surface. The lips are normally dry. They curve around the cylinder of the teeth.

The **upper lip** is made up of three forms: a small rounded form located on the midline, the **tubercle**, and two elongated forms on either side. The upper lip is flatter overall (more planar) than the lower lip, and because it is a "down" plane, it usually appears darker. Its upper edge forms a continuous, upwardly curving arch, interrupted in the middle by a wide V- or U-shaped notch where the base of the philtrum meets the tubercle. The tubercle is nonmuscular, whereas the rest of the lips is made up of the orbicularis oris muscle. The edge of the upper lip where the red part meets the skin may develop into a ridge, and a narrow top plane may develop across the upper surface of this ridge. Because this top plane may catch direct light rays, it is often conspicuous.

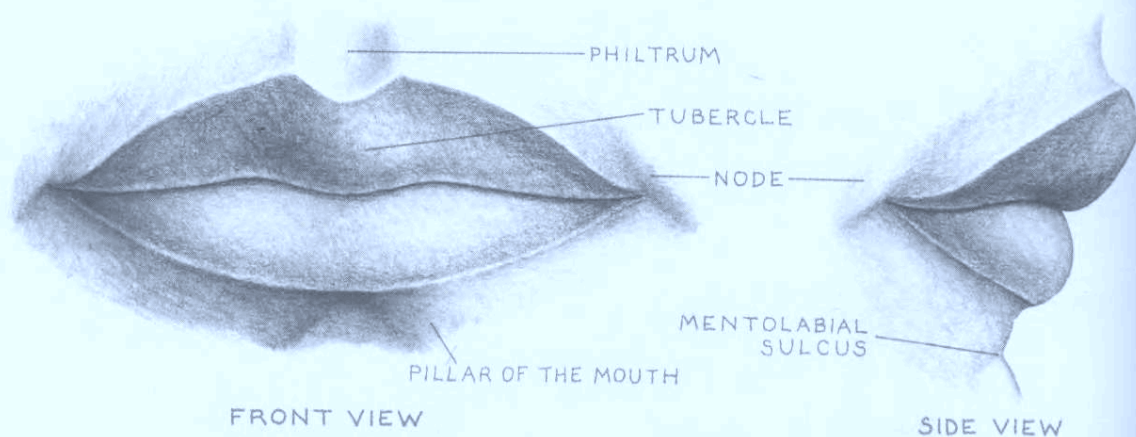
The **nasolabial furrow** or **sulcus**, passing downward and outward from the top of the wing of the nose to the outside of the angle of the mouth, technically delineates the upper lip region from the cheek. The vertical, wide, median furrow or depression located between the upper lip and base of the nose is called the **philtrum**. It is bordered by a vertical ridge on either side. The oblique, oval muscular form located immediately lateral to the angle of the mouth is called the **node** or **modiolus** (see Facial Muscles).

The **lower lip** is made up of two elongated, horizontal forms that meet at the midline. It is heavier and fuller than the upper lip, and its lower edge is more squared-off. It has a raised edge along its border where the red part meets the skin. This border may not appear at the middle of the lower lip, but it does develop laterally. It is especially prominent at the angle of the mouth, where there is a strong separation between this ridge and the large form of the red part of the lower lip. The surface of the lower lip may be continuous with the skin below (no edge), and the lip proper is distinguished by color change alone. Averaged out, the red part of the lower lip is an "up" plane, and usually receives direct light, making it appear lighter than the upper lip.

The lower lip region is separated from the chin by the horizontal **mentolabial sulcus**. Columnar forms passing downward and outward from below each half of the red part of the lower lip are referred to as the **pillars of the mouth**.

When the mouth is closed, the forms of both lips touch at the **mouth line**, with the convexities of one lip lodging in the hollows of the other. The mouth line is therefore multiply curved—from the midline outward, this line inclines upward for a short distance, downward for a longer distance, and then upward again for a very short distance. It lies at the level of the *middle* of the upper front teeth.

In the front view, the angle of the mouth approximately aligns with a line dropped from the pupil of the eye. In side view, the angle aligns with a line dropped from the front of the eyeball.



Ear

The external *EAR* consists of the auricle and external auditory meatus. The **auricle**, or **pinna** (the outer ear proper), is a complex, ovoid, cartilaginous funnel, larger above, that directs sound into the **ear hole**, or **external auditory (acoustic) meatus**. The auricle is made up of a single complex cartilage, as well as fatty skin.

The **concha** is the deep, bowl-shaped part of the cartilage that attaches directly to the side of the head at the front of the mastoid process of the skull. The ear hole is located in the lower front corner of the concha. The **helix** rings the uppermost portion of the ear. It begins deep on the floor of the concha as the **crus of the helix**, dividing the concha into a smaller upper portion and a larger lower one. It passes forward, outward, and upward and then curves down the posterior edge of the ear, to finally end when it reaches (blends into) the earlobe. For the most part, the helix is cartilaginous, but its lower back portion is formed by skin. Its inner edge on the upper half of the ear is sharp. An anteriorly pointing **tubercle** is often seen on the inner edge of the upper back corner of the helix.

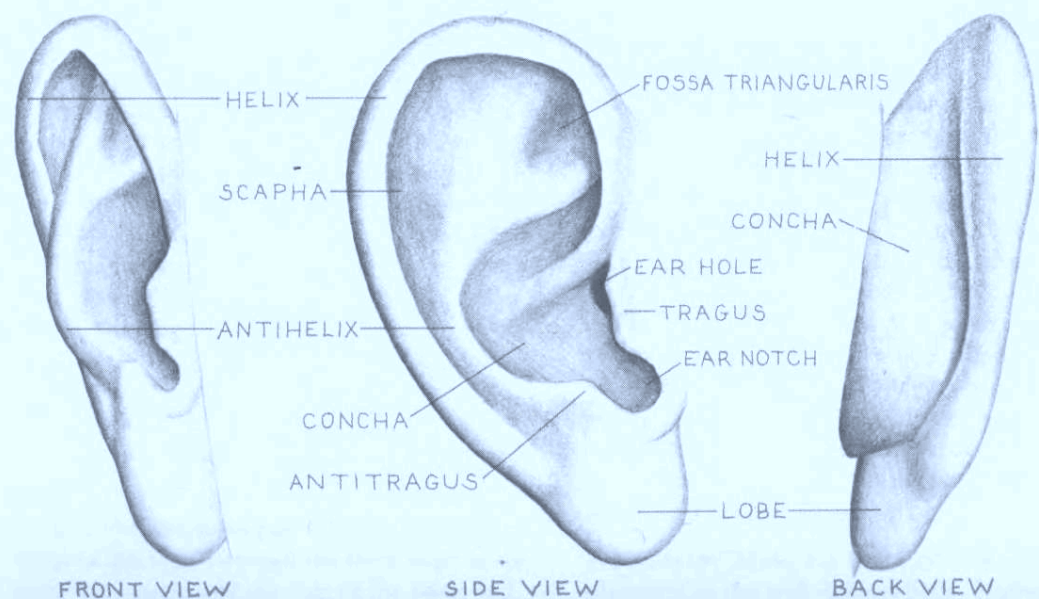The **antihelix** roughly parallels the helix, lying internal to it. It also borders the back and top of the concha. It splits superiorly (anteriorly) into a U-shaped fork having a rounded and large upper leg and a narrow and sharp lower leg. The legs are separated by a depression called the **fossa triangularis**. The antihelix ends inferiorly just before reaching the earlobe and antitragus. The elongated, curving furrow between the helix and antihelix is the **scapha**.

The oblique **ear notch**, or **intertragic notch**, is located on the front edge of the ear just above the earlobe. It is bordered by cartilage. The

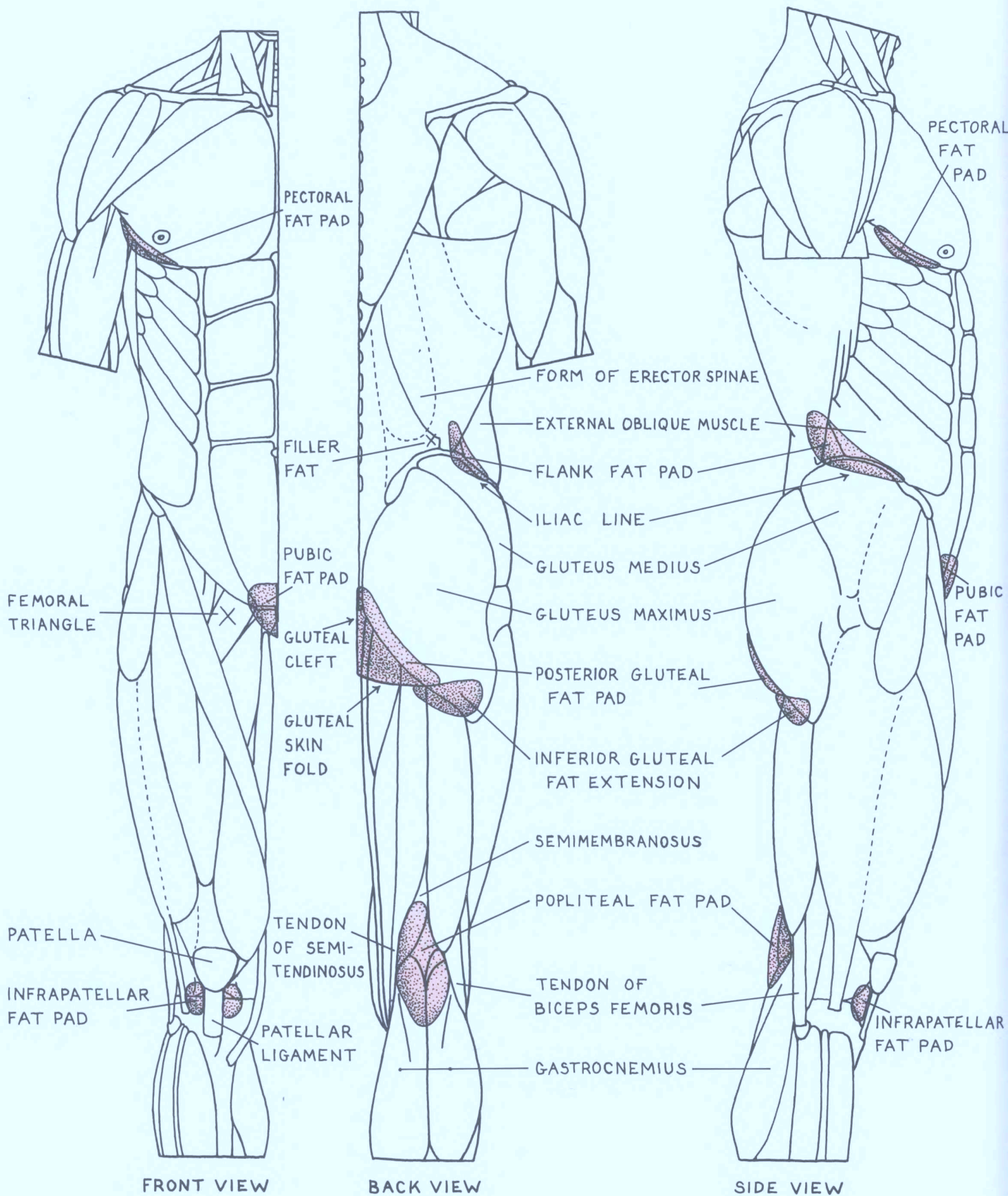
tragus is a double-pointed cartilaginous projection located above the ear notch. It lies just posterior to the condyle of the mandible at the posterior end of the zygomatic arch. The **antitragus**—projecting opposite the tragus—is located above the lobe. The tragus and antitragus partially project over the openings of the concha and ear hole. The tragus is separated from the helix by a notch. The **earlobe**, or **lobule**, is a softy, fatty skin form that hangs off the bottom of the ear. It is usually independent of the side of the jaw, but is sometimes attached.

From the front view, the ear is widest at the top (at the helix). The antihelix projects laterally at its midpoint, receding inward toward the head both superiorly and inferiorly. From the side view, the ear appears oblique, its long axis directed downward and forward. This axis, as well as the front edge of the ear, is roughly parallel to both the back of the ramus of the lower jaw and the profile of the nose. From the back view, the outer edge of the helix makes an S curve, while the bowl-shaped concha attaches to the side of the head. The concavities seen in the side (outer) view of the ear become convexities on the cranial (medial) side.

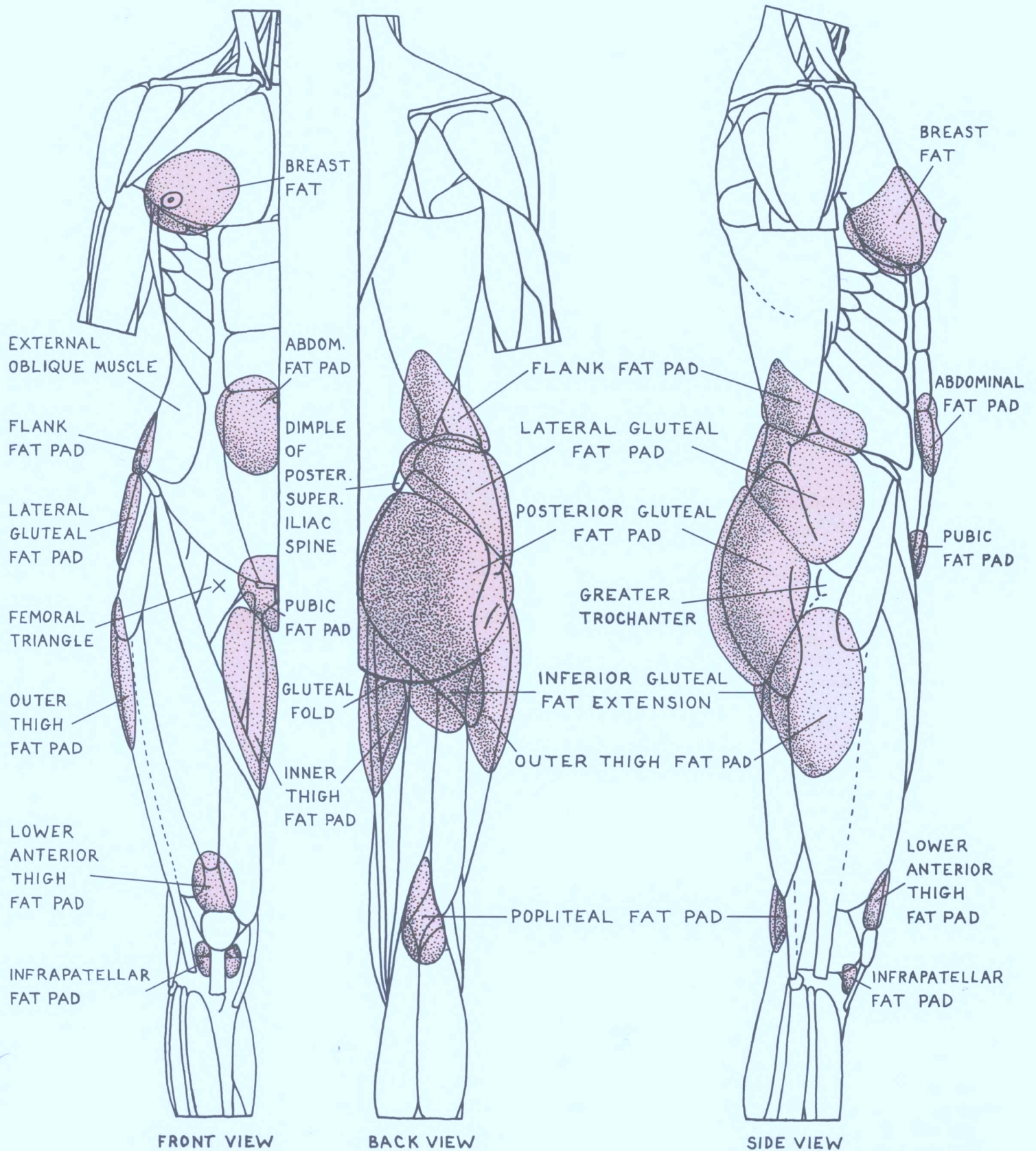
The top of the ear is approximately in line with the brow, while the bottom of the lobe usually coincides with the level of the base of the nose. These alignments do vary quite a bit, though. The straight front edge of the ear is located approximately midway between the front and back of the head; the ear hole is located just posterior to the midline. The auricle of the ear sits on the side of the base of the cranium. The overall plane of the ear is directed outward, slightly forward, and slightly downward.



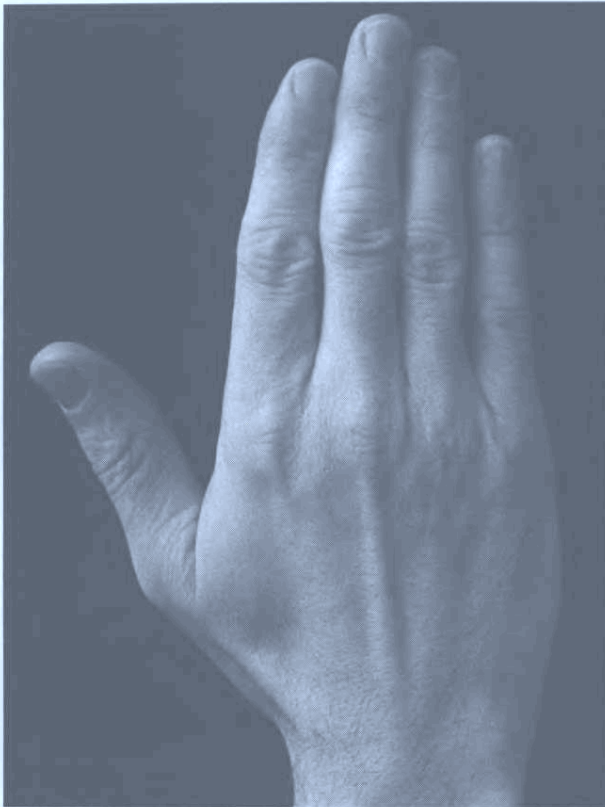Male Fat Pads



Female Fat Pads



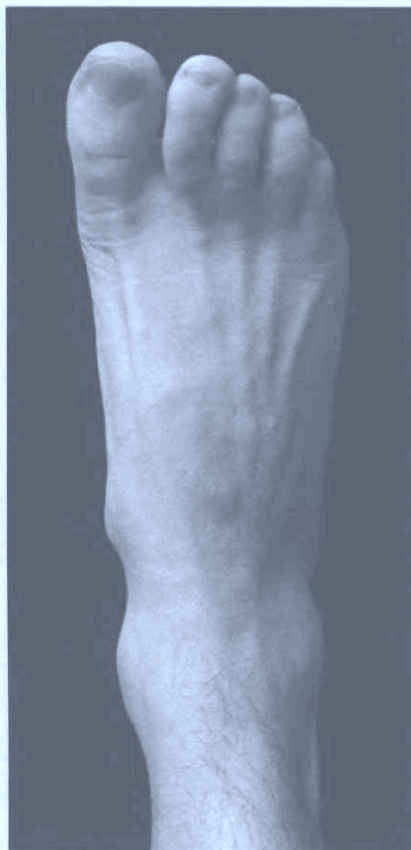Skin Hand and Foot



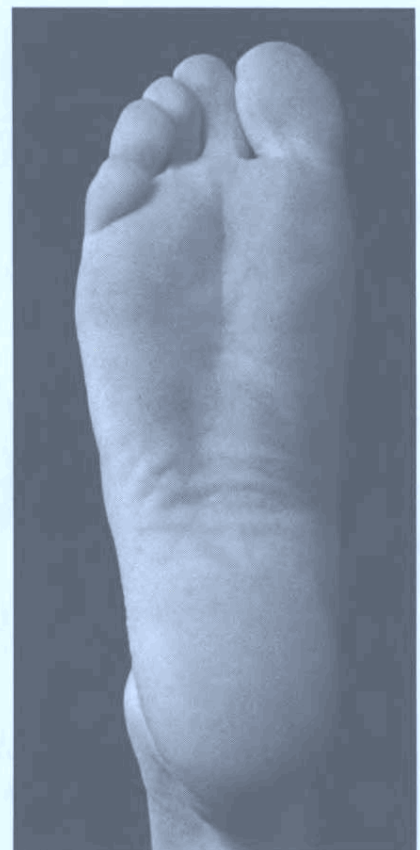Back of hand



Palm of hand

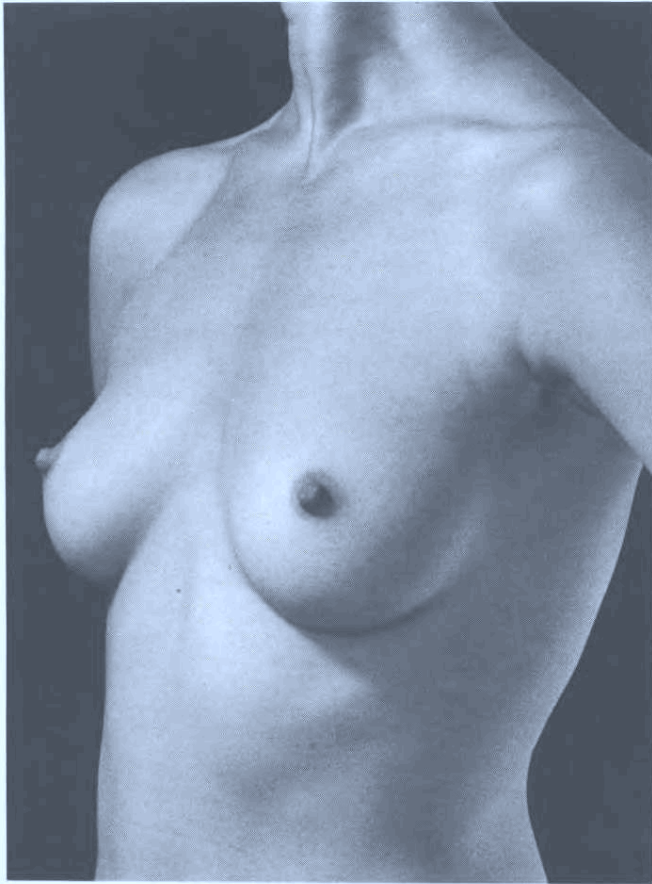

Top of foot

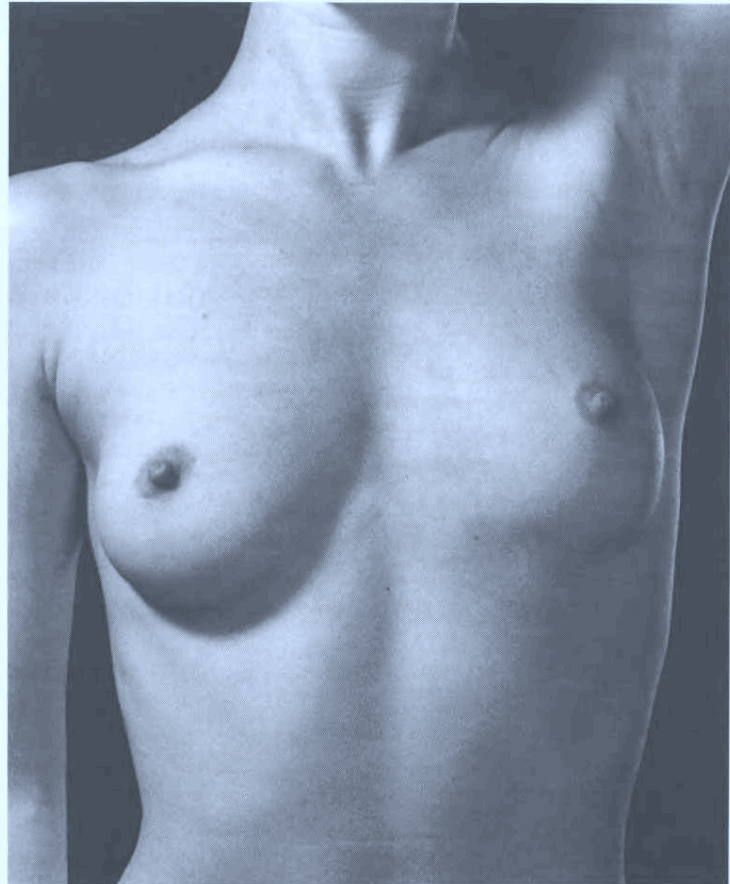


Sole of foot

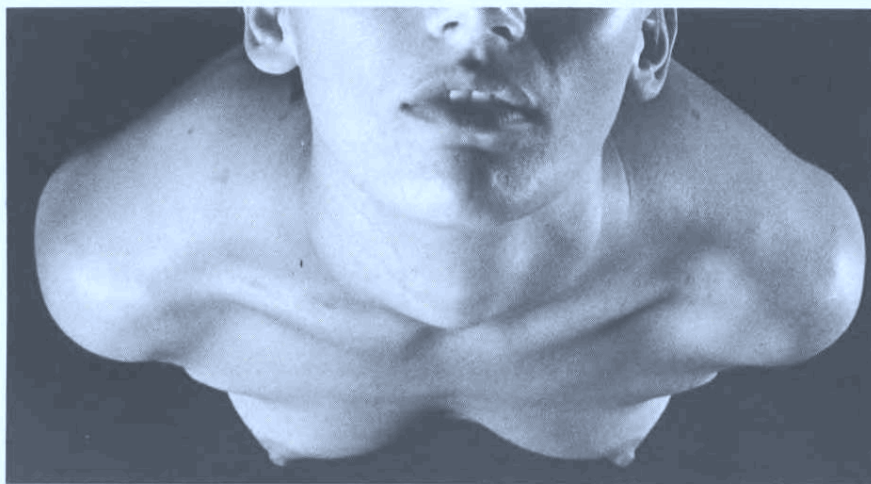Breasts, Genitals



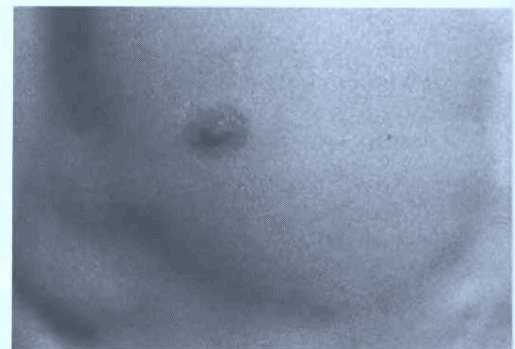
Female breasts



Female breasts

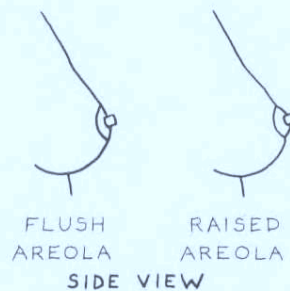
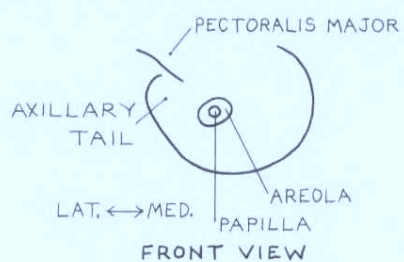


Female breasts—top view



Male nipple

RIGHT FEMALE BREAST




RIGHT MALE NIPPLE

LAT. ↔ MED.

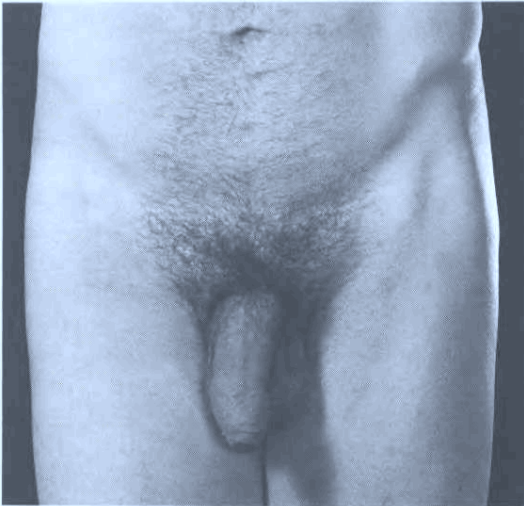

MALE NAVEL

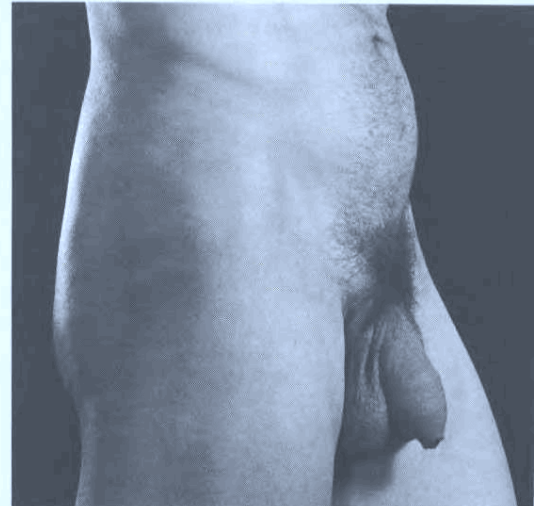

FRONT VIEW

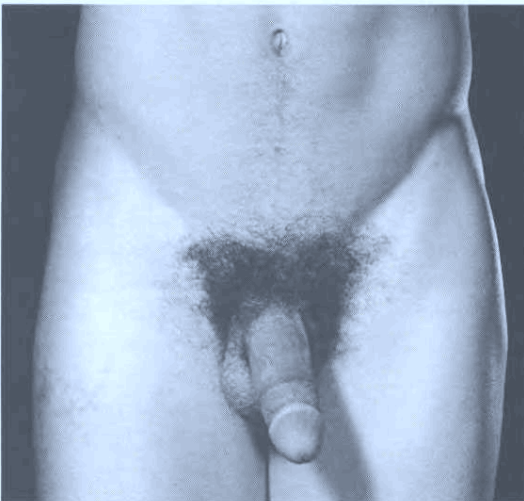Breasts, Genitals



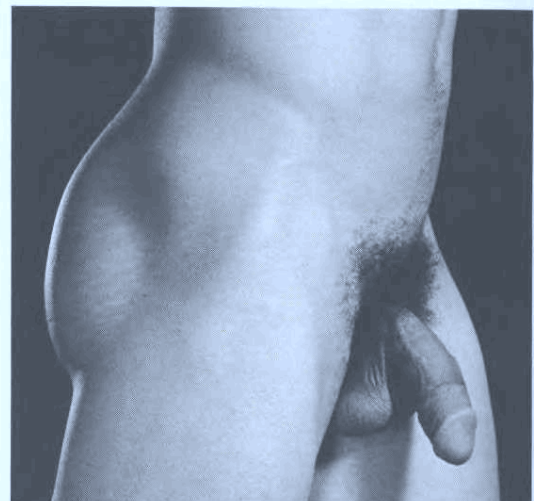Uncircumcised penis



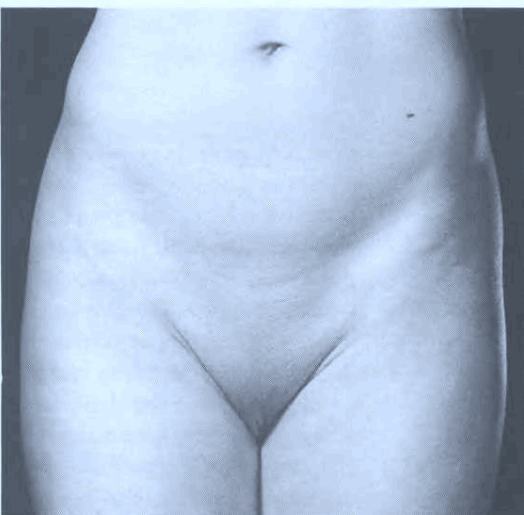Uncircumcised penis



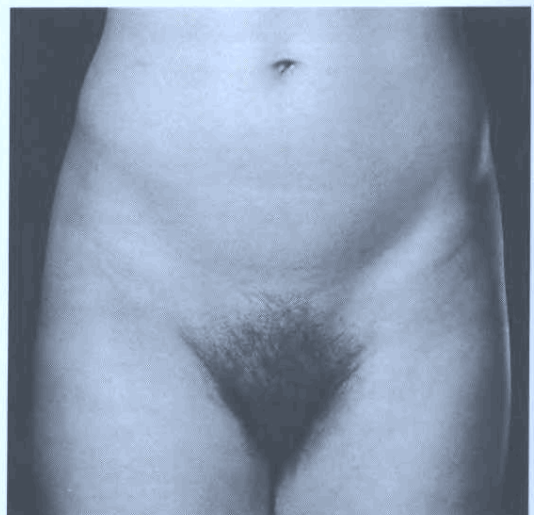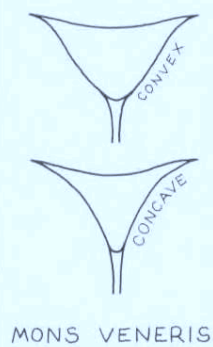
Circumcised penis



Circumcised penis

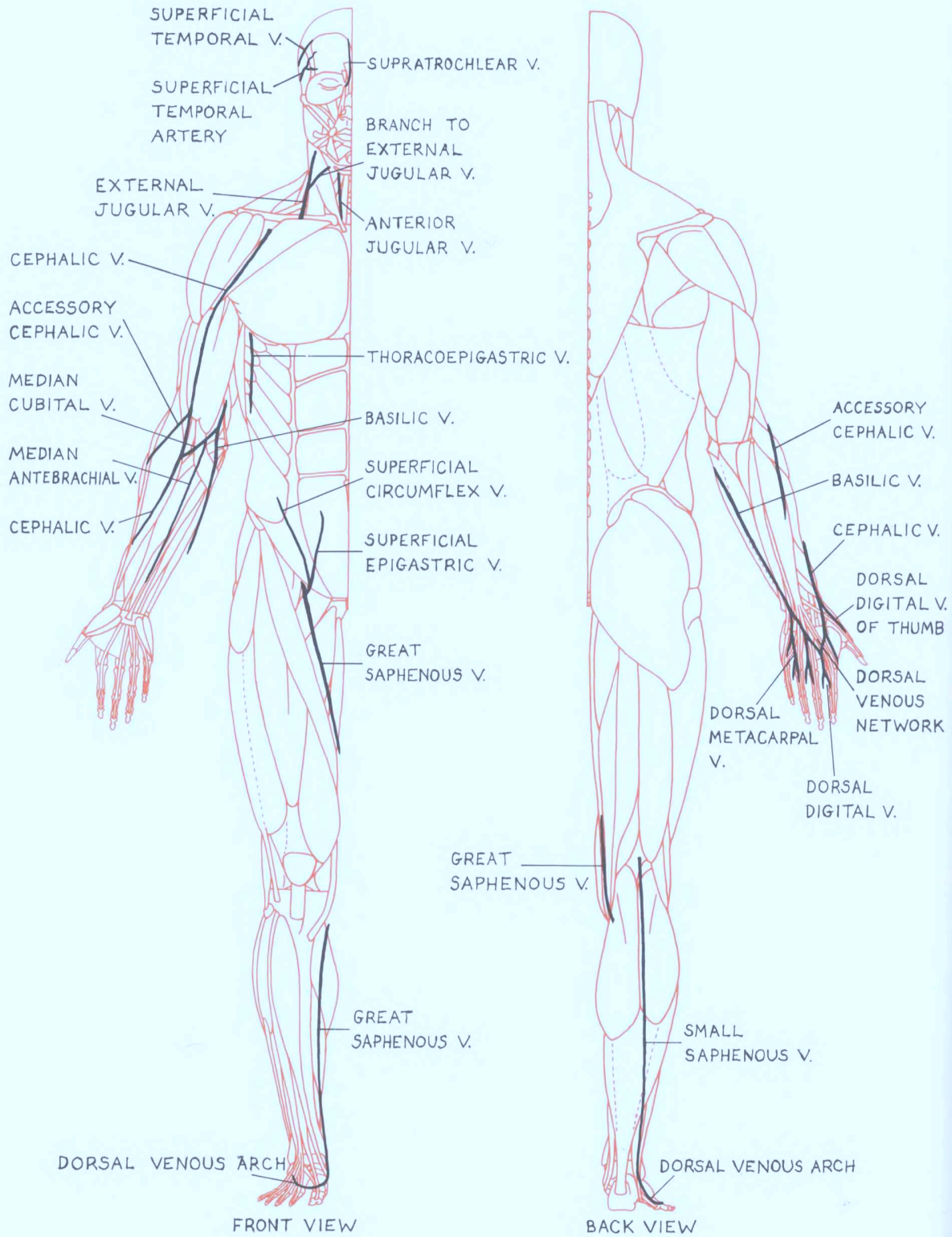


Female pubic region

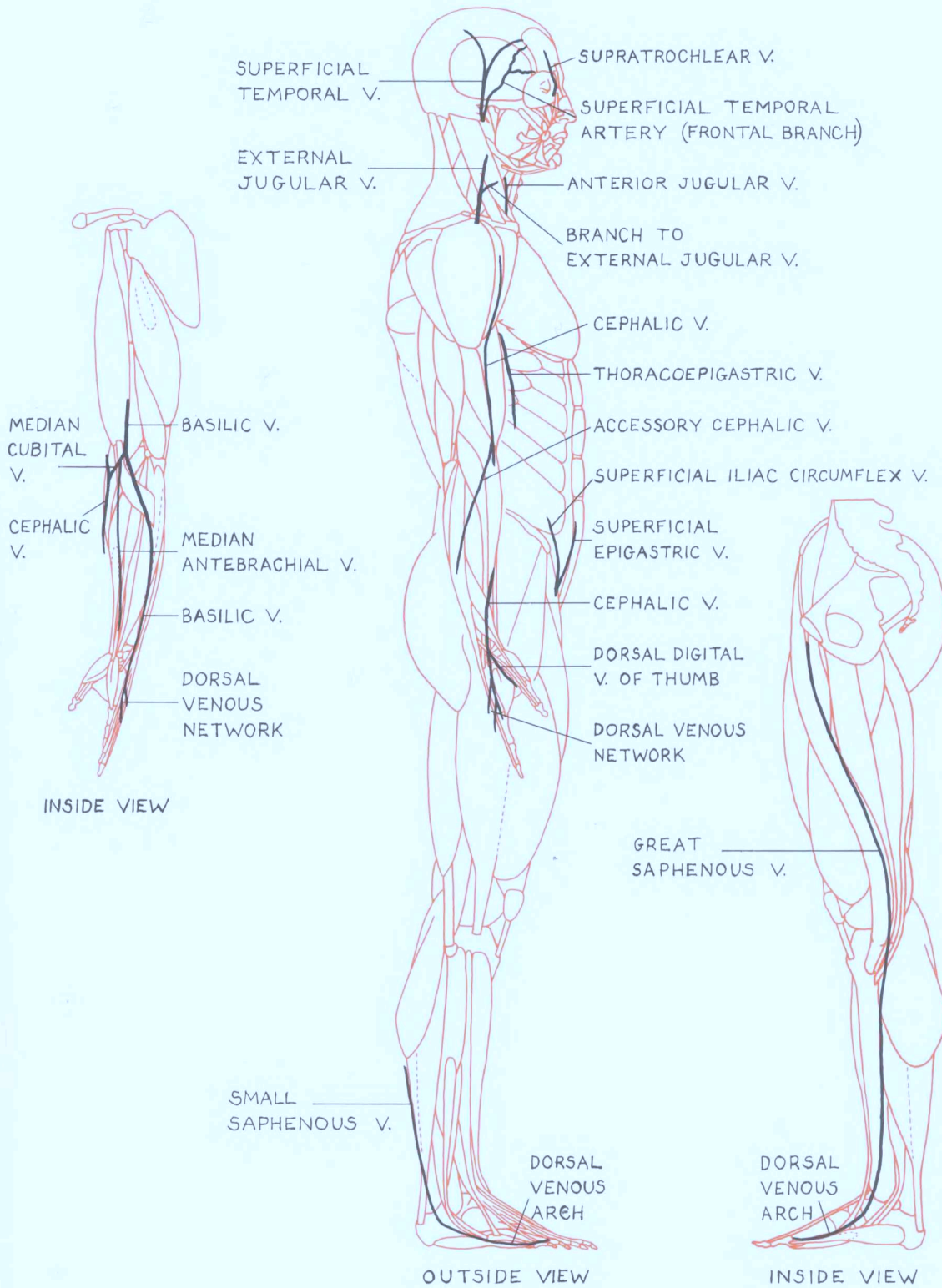


Female pubic region

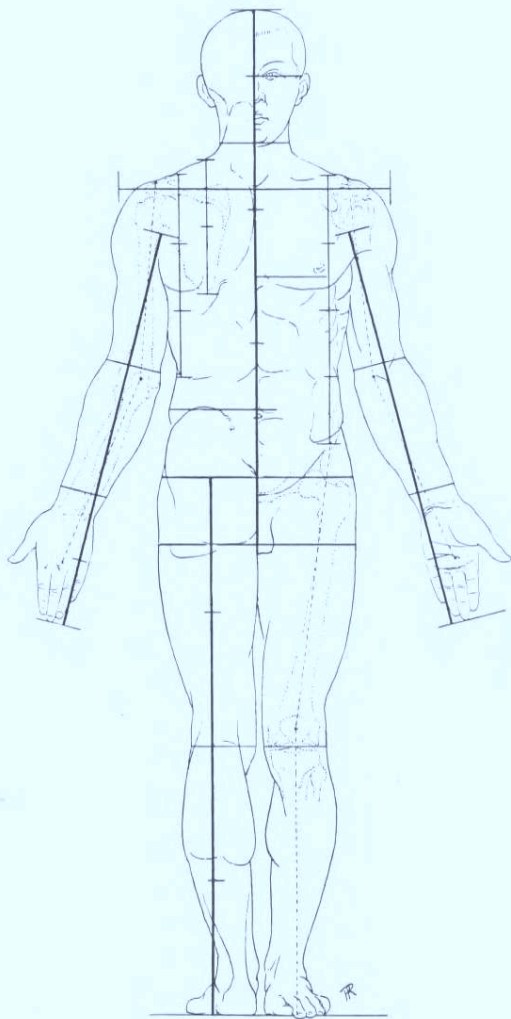
Veins



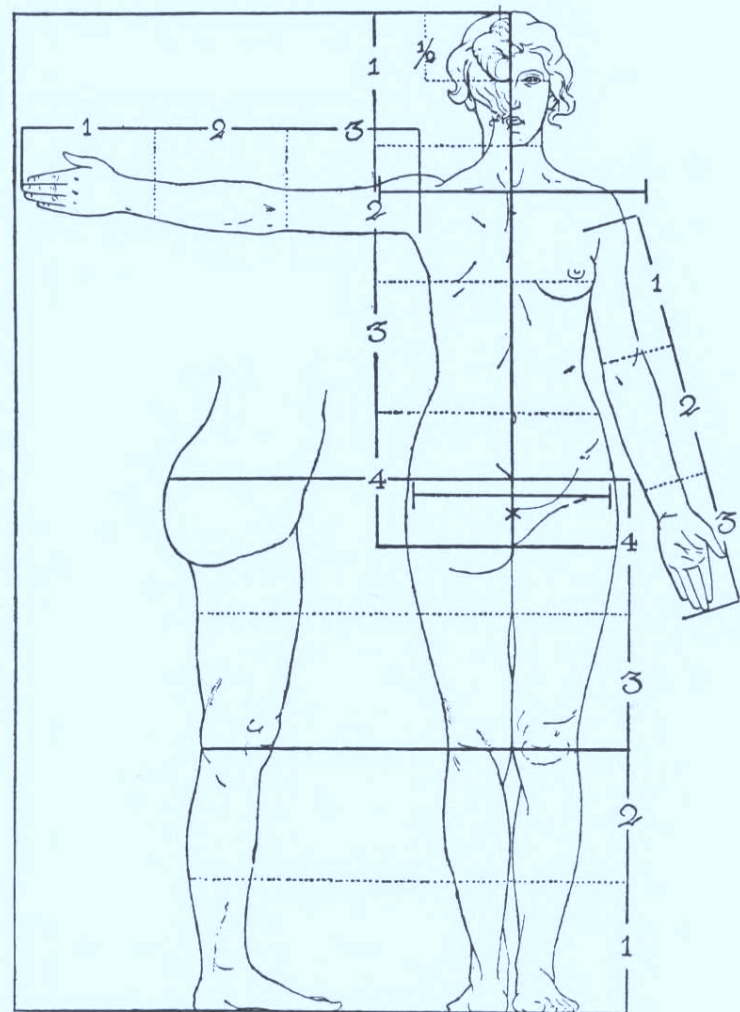
Veins



Proportion



Paul Richer—1890



Paul Richer—1920

PROPORTION is the most subjective aspect of the study of human structure. Our understanding of proportion is based on a combination of several factors: historical conceptions of the figure throughout art history (it also varied in different geographical regions during the same time period, e.g., German and Italian Renaissance), society's present standard of beauty, our own particular sensibilities as an artist, and, when working from the live model, the particular set of proportions of that individual.

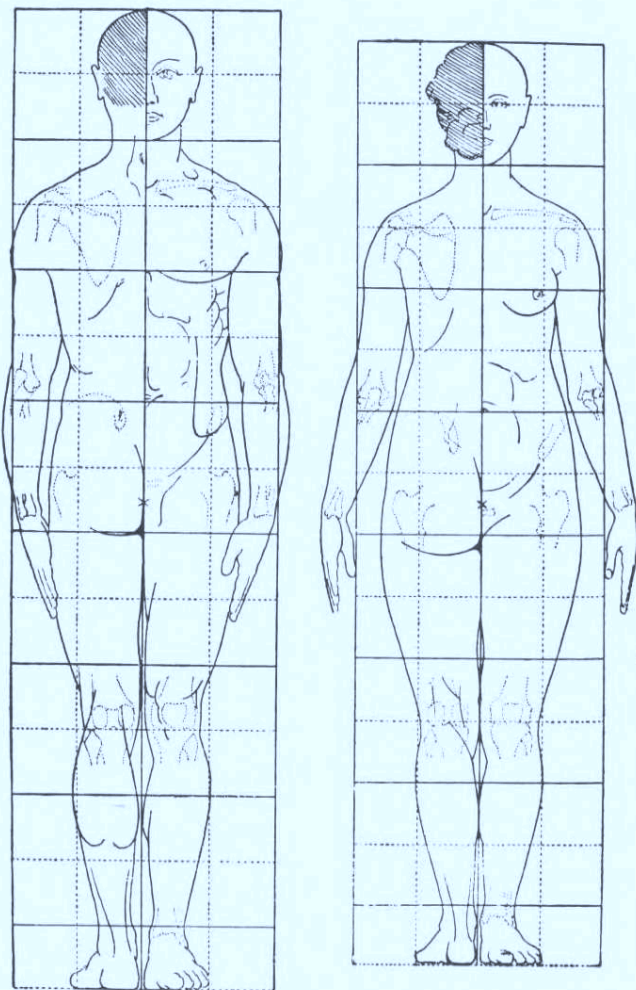
Proportion deals with *comparisons*—a height to another height, a height to a width, a height to a depth, a width to a depth, etc. Useful lengths are those that are equal to another length or are multiples of that length (twice as long, three and a half times as long, etc.). The figure, or its components, can also be divided into equal units, such as halves, thirds, fourths,

etc. A common unit of measurement for the body is a head length (head height), which can, for example, be divided into the figure six, seven, seven and one-half, eight, or even more times, each having very different results.

The body can be measured from its bony landmarks (top and bottom of the sternum, medial epicondyle of the humerus, front point of the pelvis, patella, etc.) and from its fleshy landmarks (nipple, navel, horizontal gluteal fold, etc.). Fleshy landmarks are more variable among individuals, and tend to shift when the figure changes pose.

Finally, and obviously, proportions vary according to age, sex, and race.

The following illustrations present some traditional systems of proportion developed by well-known artist/anatomists.



PROPORTIONS OF MALE AND FEMALE FIGURES IN HEADS AND HALF-HEADS

Arthur Thomson—1896

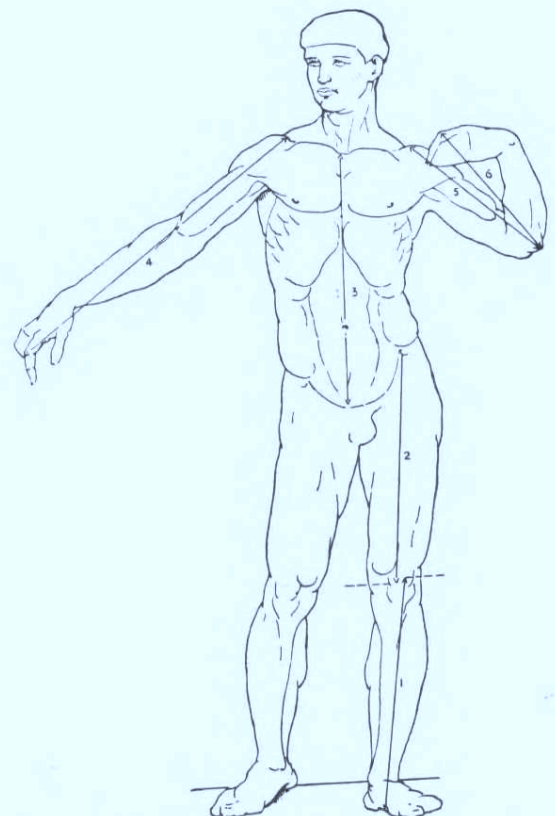


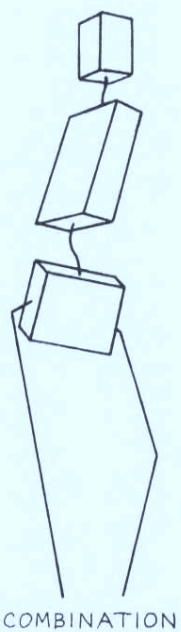
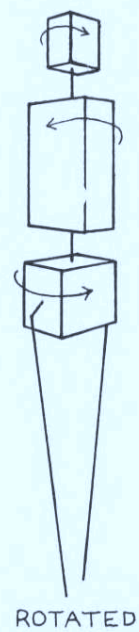
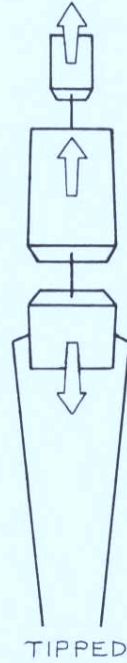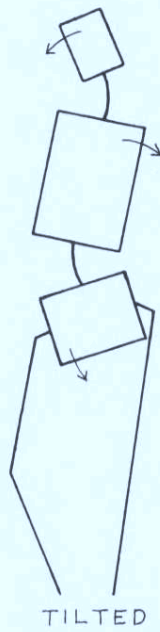
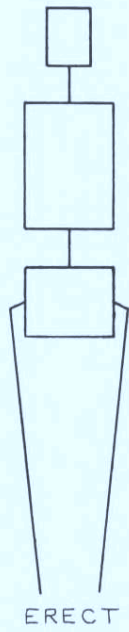
FIG. 129.—GENERAL COMPARATIVE PROPORTIONS.

1. From Plinth to top of Patella.
2. From centre of Patella to Iliac process.
3. From Pubic line to top of Sternum.
4. Three heads in length from Acromion to first articulation of index finger.
5. From Acromion to head of Ulna one head and a half.
6. From head of Ulna to first articulation of finger one head and a half.
- From Plinth to top of Patella two heads.
- From centre of Patella to Iliac process two heads.

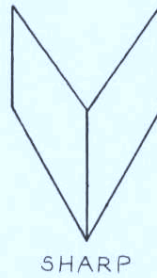
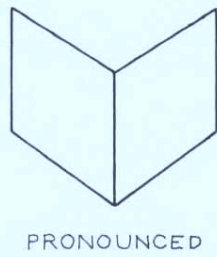
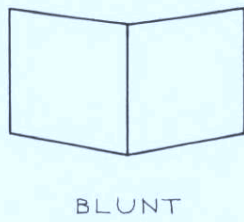
Edouard Lanteri—1922

Mass Conceptions of the Figure

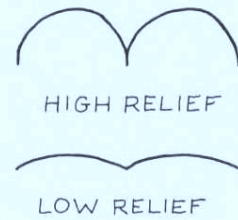VOLUME RELATIONSHIPS



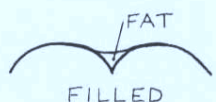
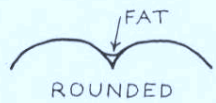
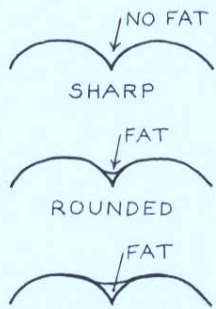
EDGES



FORM DEFINITION

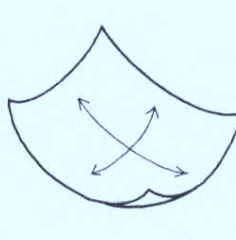
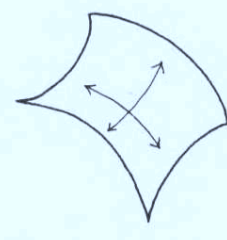
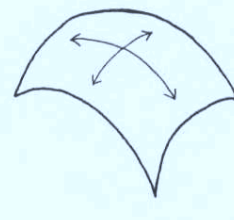
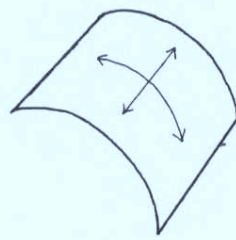
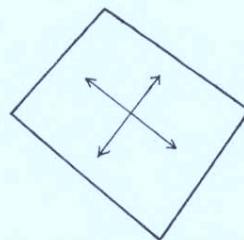


FORM
PROJECTION



DEFINITION
BETWEEN
FORMS

SURFACES

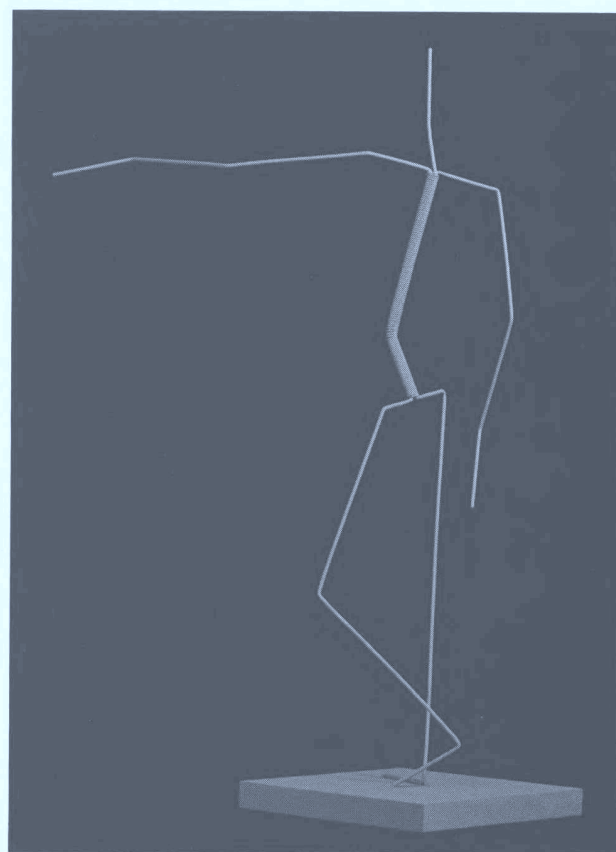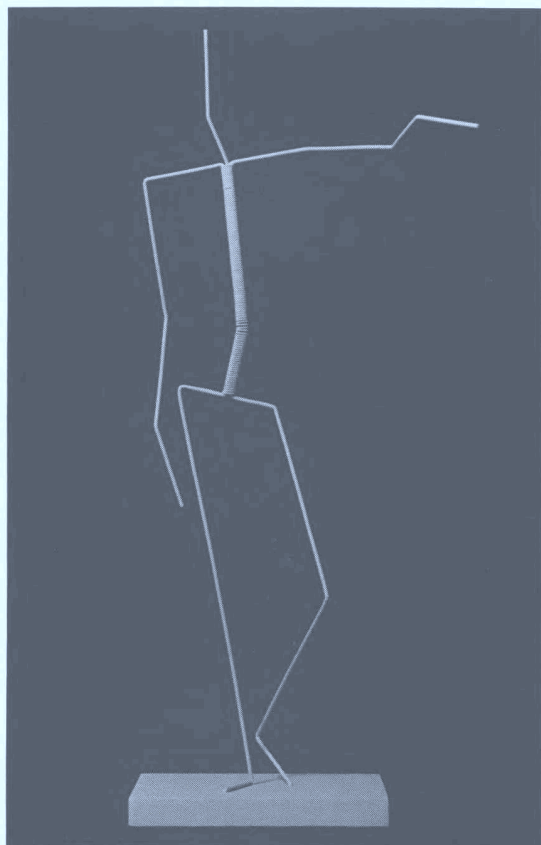


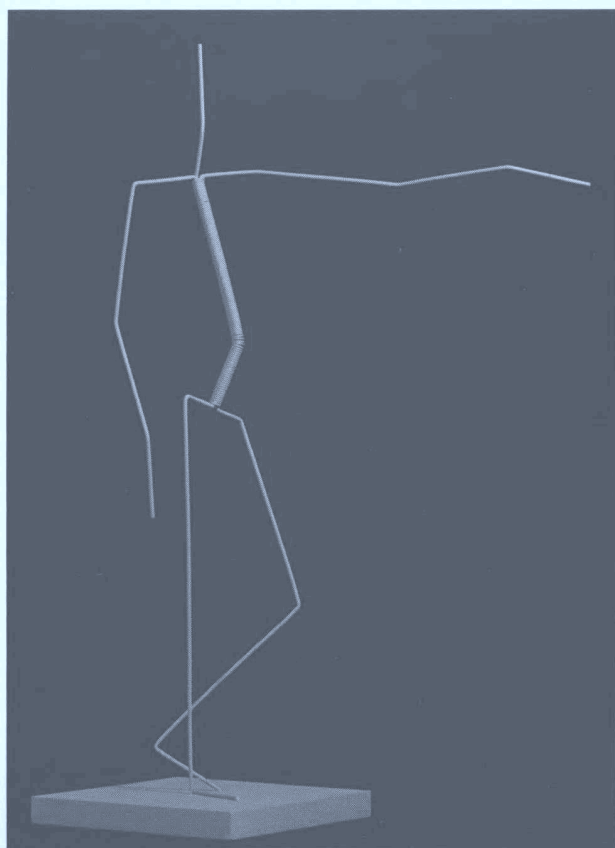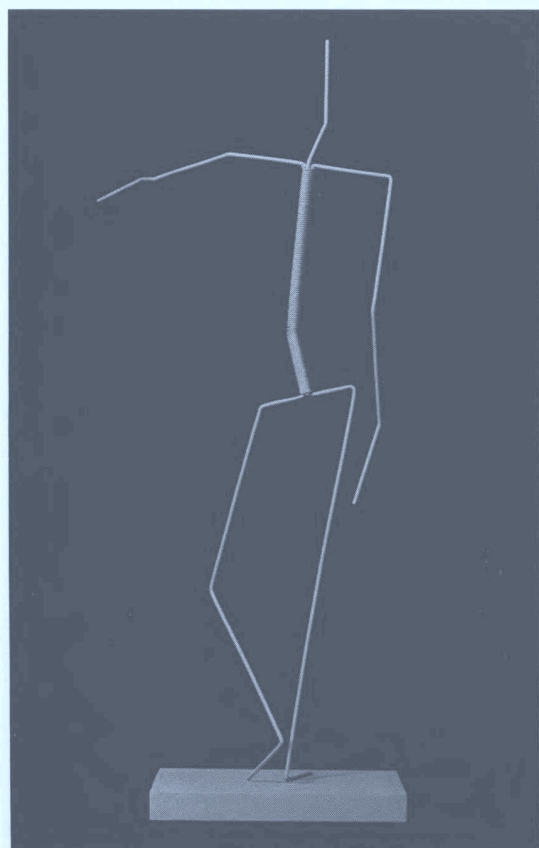
Mass Conceptions of the Figure

RELATIONSHIP BETWEEN FORMS *All form in the figure is produced by anatomy*—bone, cartilage, muscle, tendon, fat, skin, veins, etc. Besides the usual geometric shapes, forms in the figure are often **teardrop** or **fusiform** (tapering toward each end). Forms can be considered in **high** or **low relief** depending on their projection from the surrounding surface, independent of the definition between them. **Definition** between forms varies, depending on the degree of subcutaneous fat and the amount of

contraction of the muscles. The contact between forms can be *sharp* (cleft, cleavage), *rounded* (furrow, groove), or *obscured* (filled—continuous surface between forms). On close examination of the figure, its individual forms can be isolated and their borders defined. Capturing this extensive network of interrelated surface forms, or **surface modeling**, in an accurate way gives artwork great fidelity to nature, vitality, and realism.



Axes






Mass Conceptions of the Figure

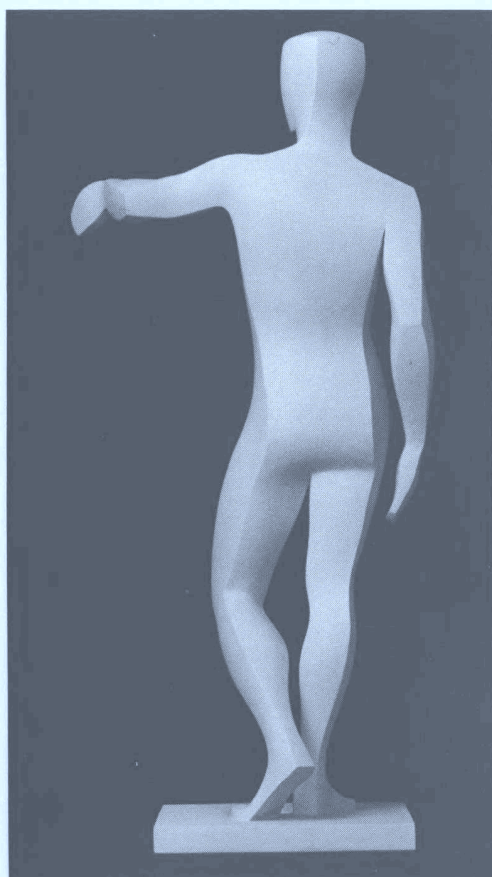

Blocks



*Continuous
planes*





Mass Conceptions of the Figure





Mass Conceptions of the Figure





*Tapered
cylinders
(cones)*



Ovoids

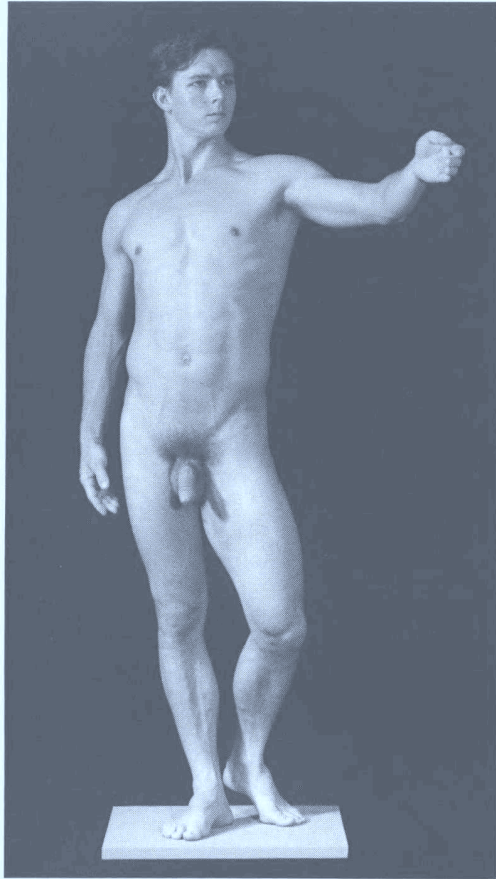

Mass Conceptions of the Figure



Mass Conceptions of the Figure

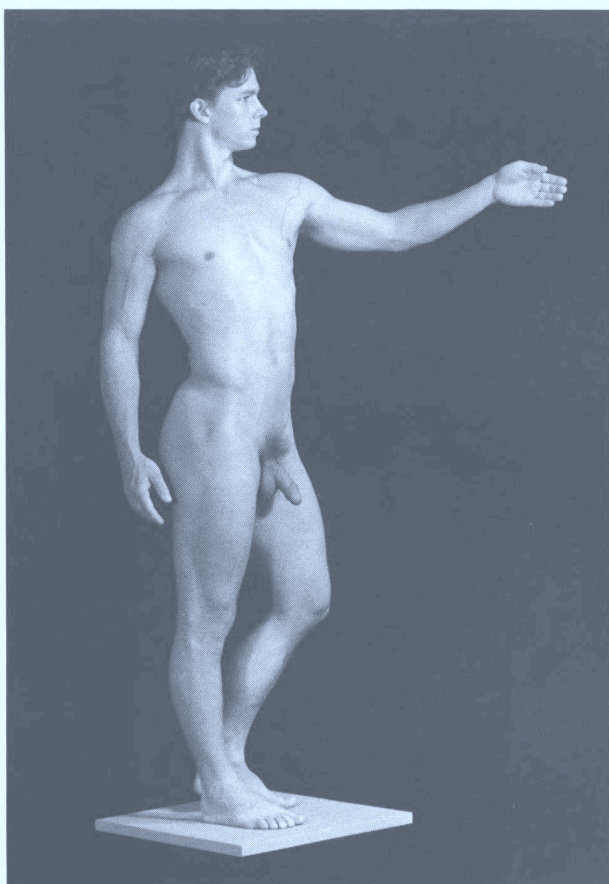
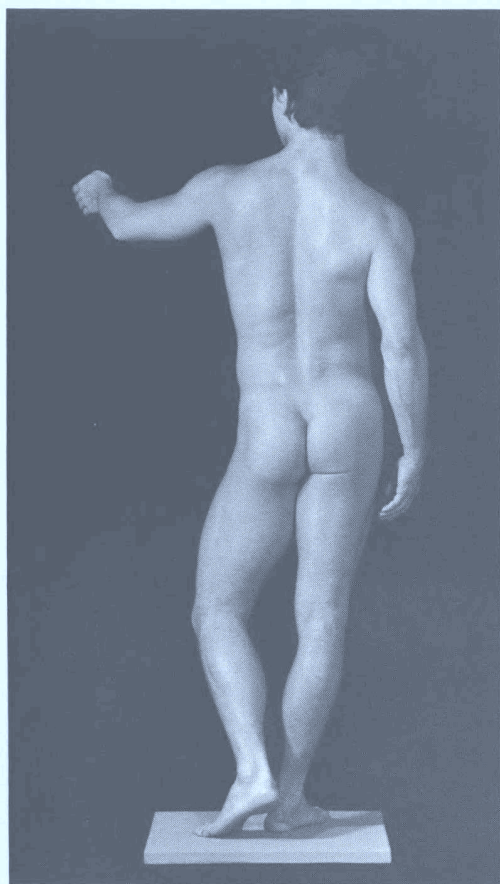Male—life



Female—life





Mass Conceptions of the Figure

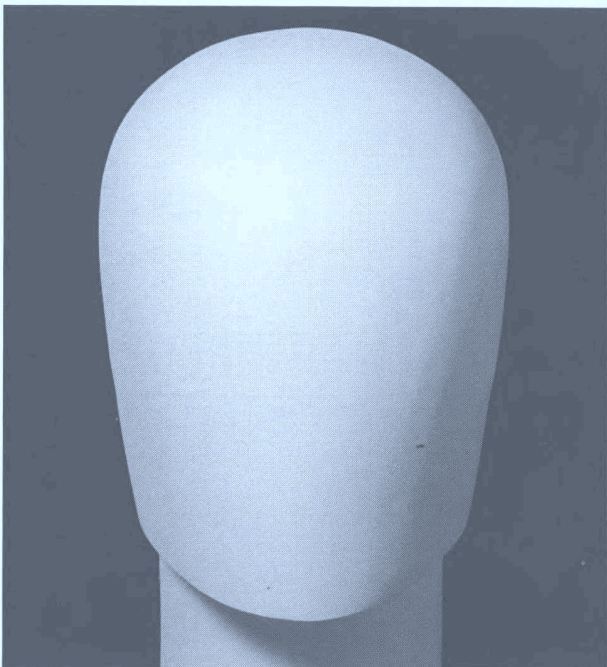


Mass Conceptions of the Head





Box



Rounded form





Mass Conceptions of the Head





Mass Conceptions of the Head





*Single
rounded
planes*



*Underlying
volumes*




Mass Conceptions of the Head



Mass Conceptions of the Head

*Simplified
planes*



Male—life

